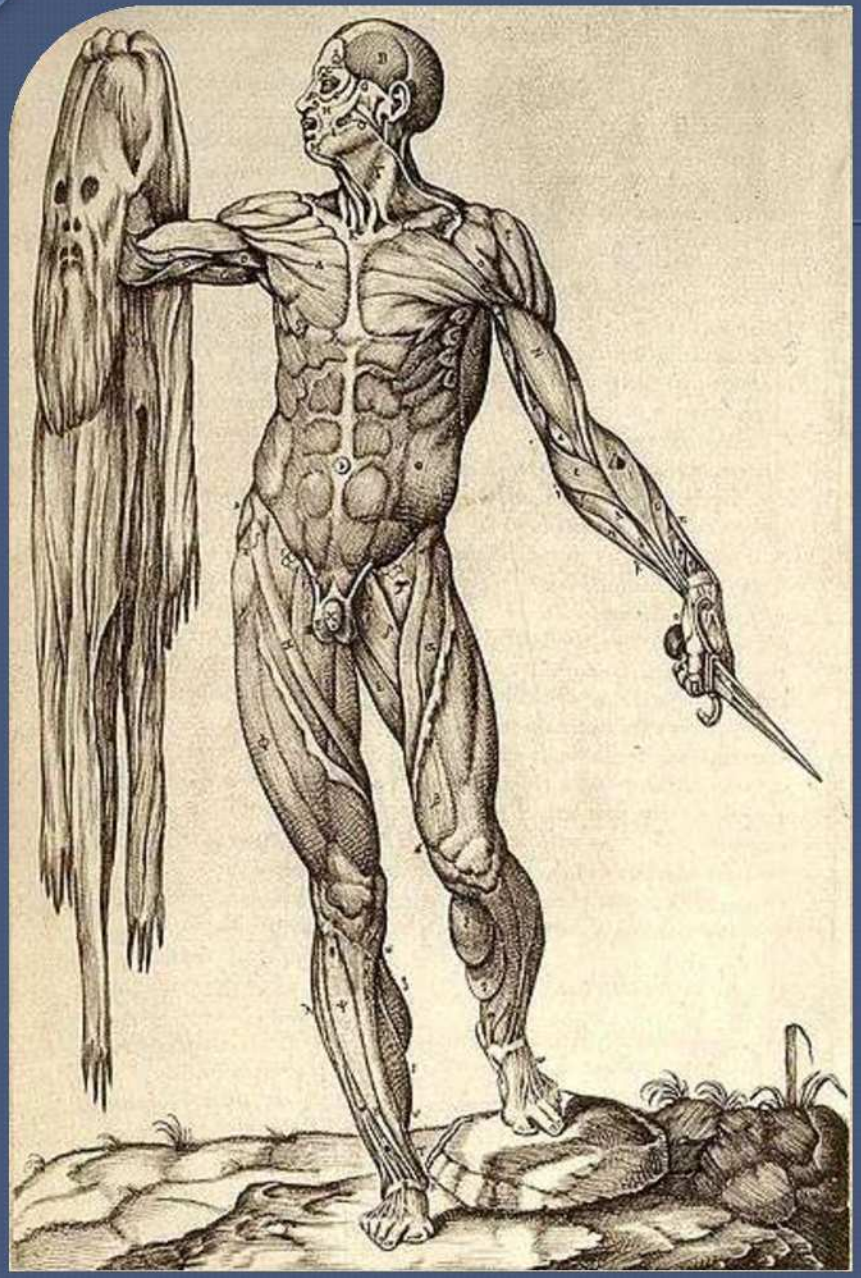

SKELETILIHASED

Tarvo Sillat
III aasta resident

Lihased

- Inimesel üle 400
- 1/3-1/2 kehakaalust

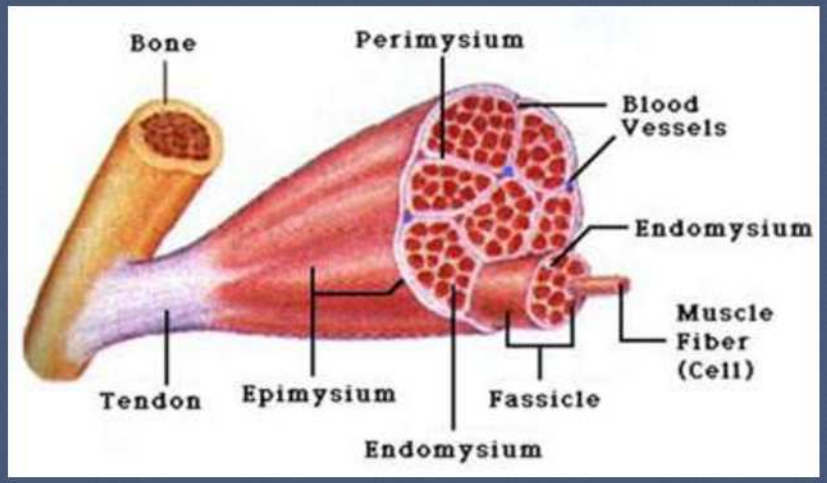

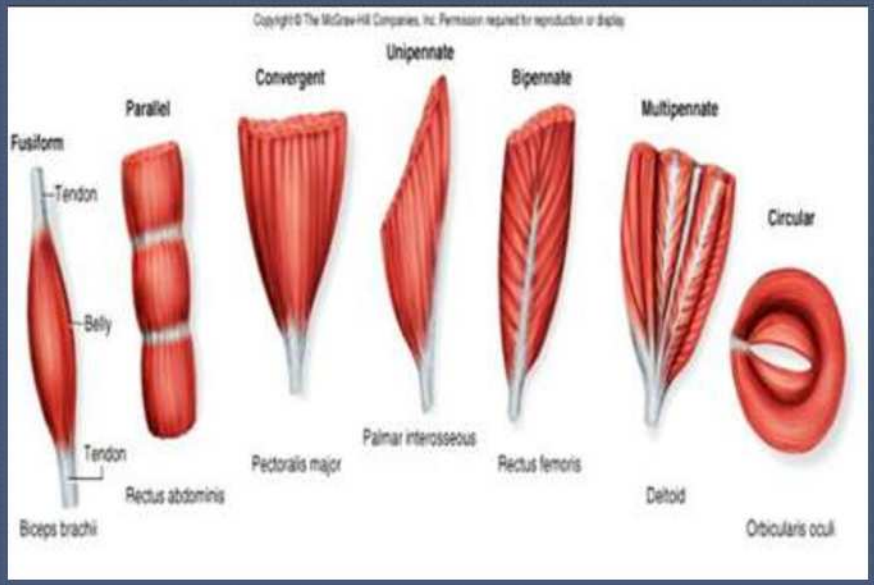

http://people.eku.edu/ritchisong/301notes3.htm

Reeglina paigutuvad kompartmentidesse

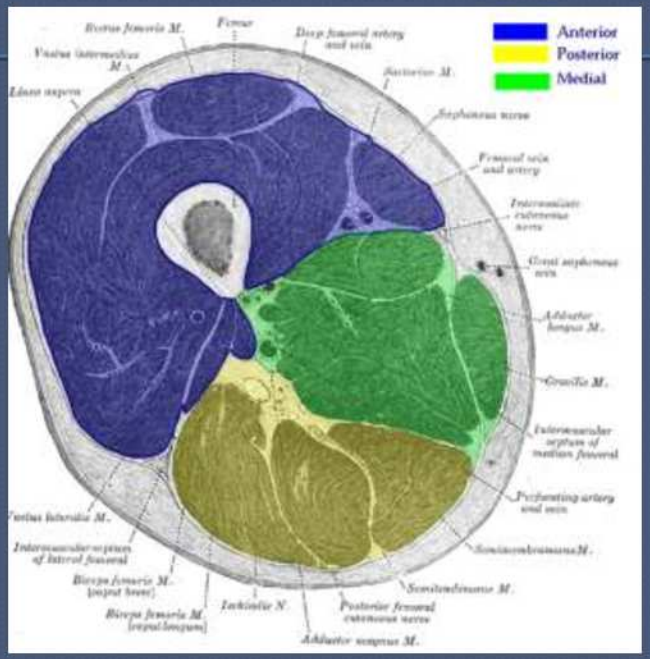

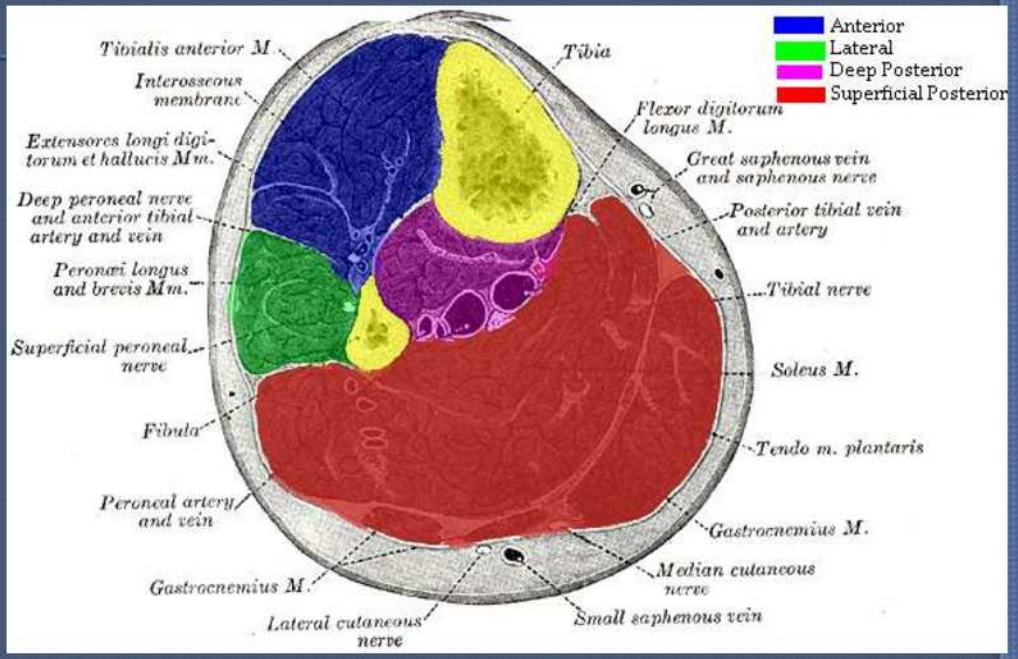

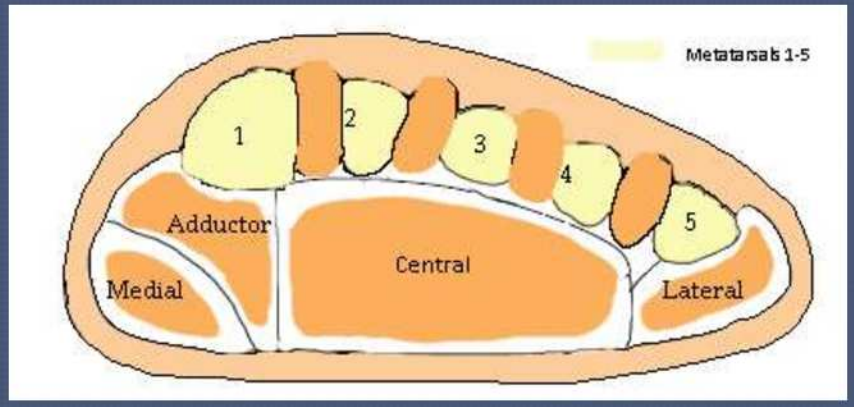

http://php.med.unsw.edu.au/medwiki/index.php?title=Compartment_Syndromes_of_the_Lower_Limb

Fastsiad

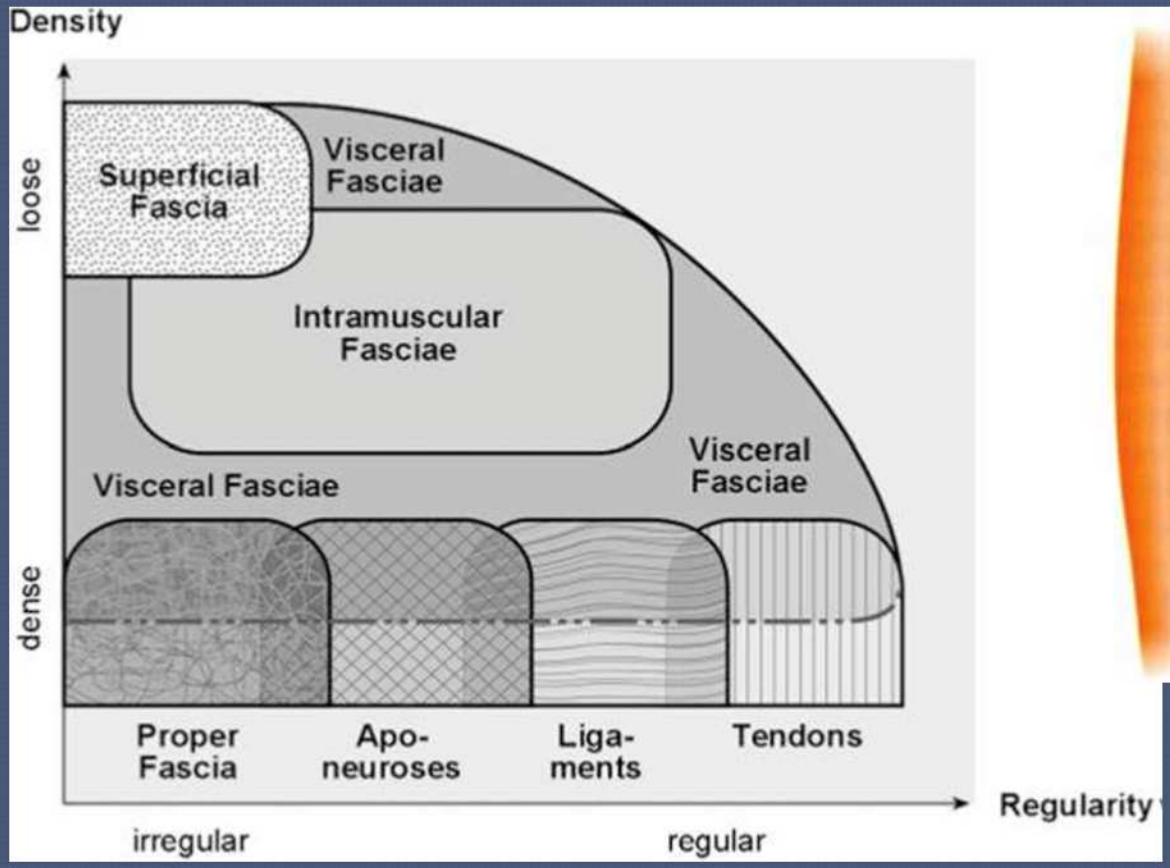

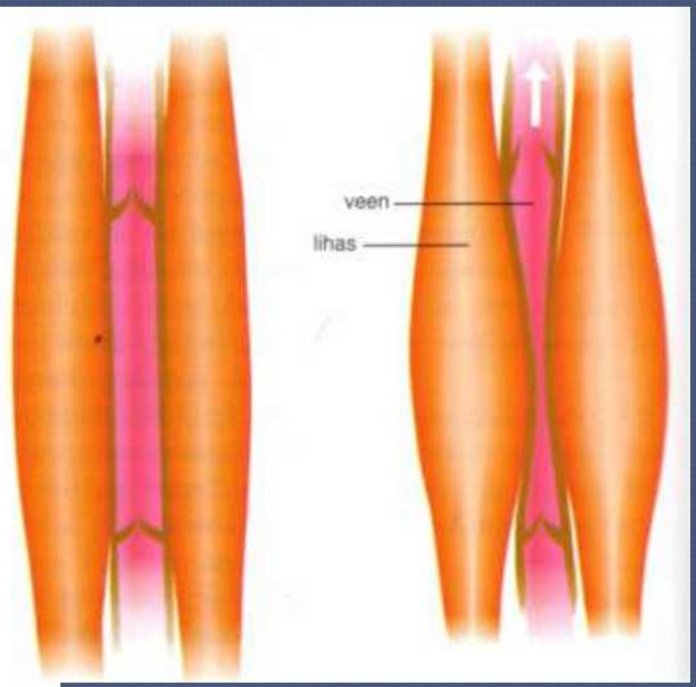

Schleip 2012

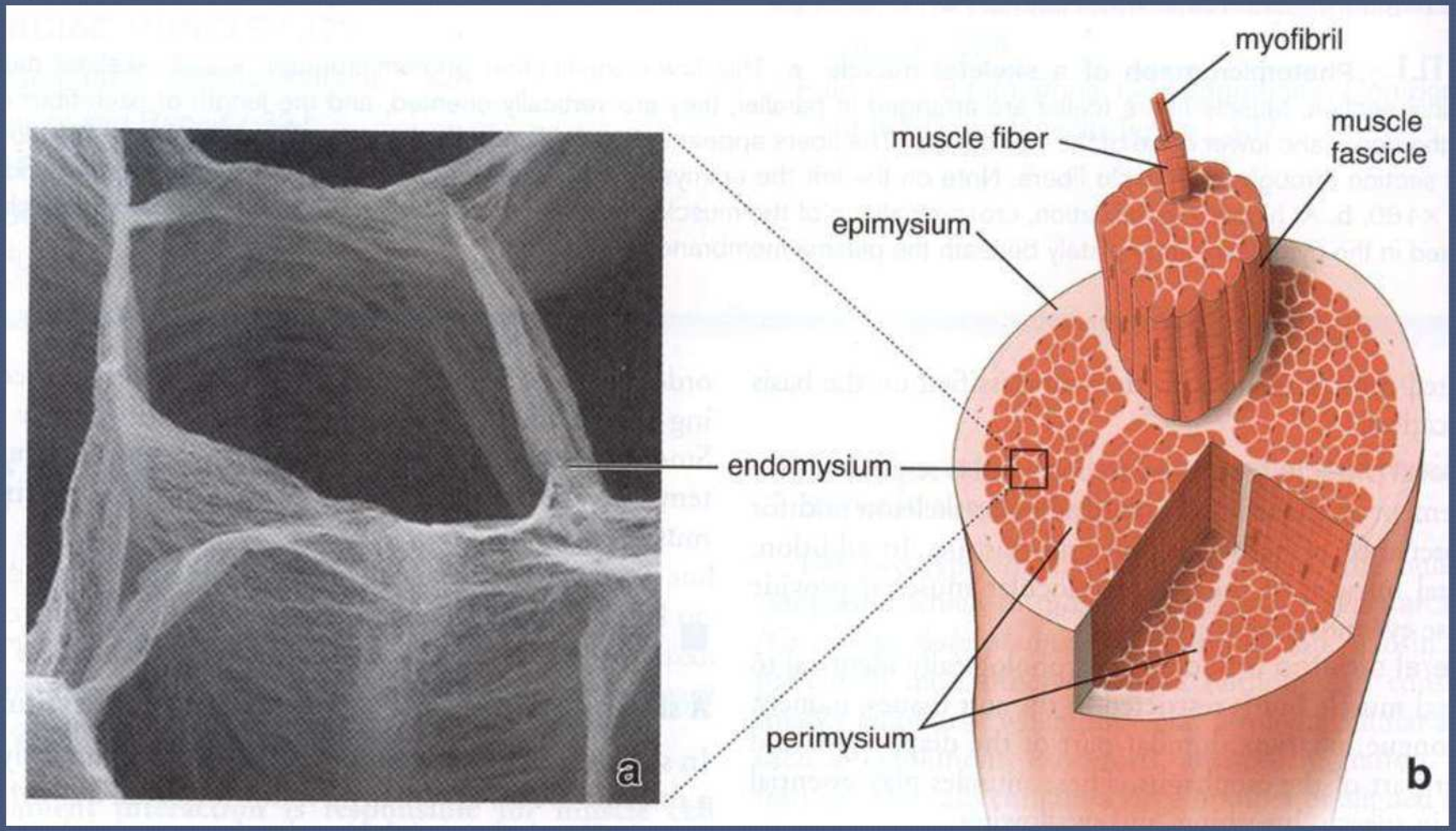
myofibril
muscle fiber
muscle fascicle
epimysium
endomysium
perimysium
a
b

Ross 2010

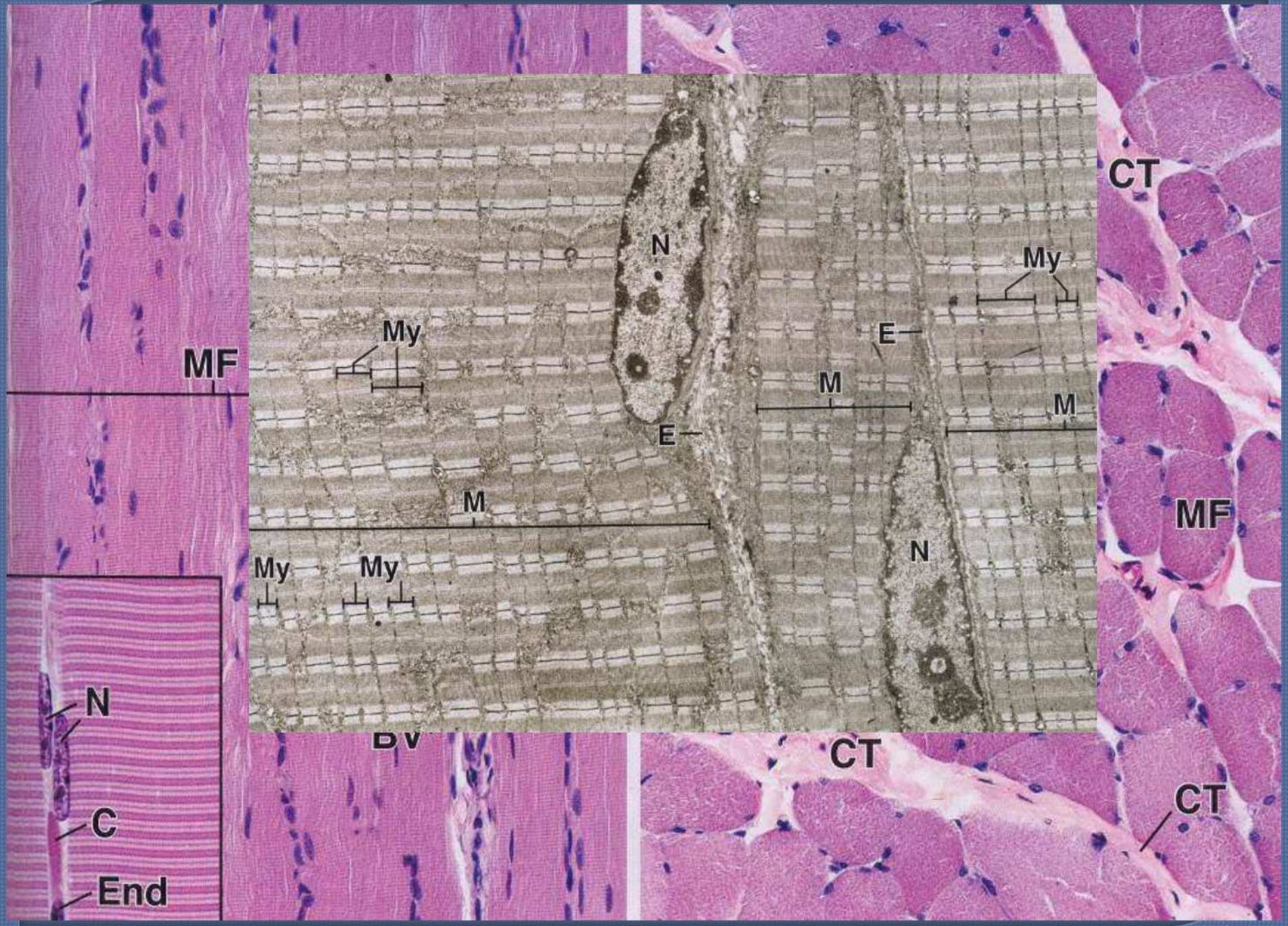

CT
N
My
My
E
MF
M
M
E
M
MF
N
My
My
N
C
End
CT
CT

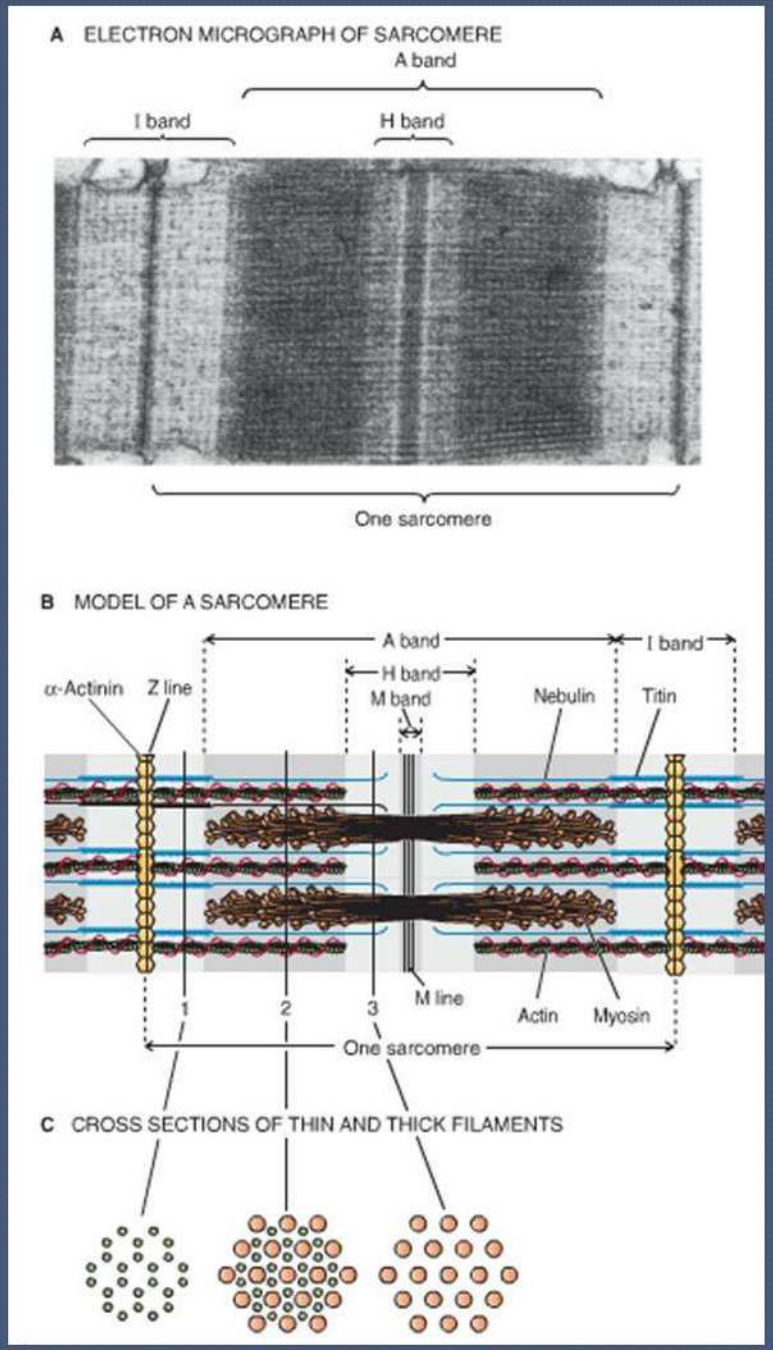
A ELECTRON MICROGRAPH OF SARCOMERE
A band
I band
H band
One sarcomere
B MODEL OF A SARCOMERE
A band
I band
H band
α-Actinin
Z line
M band
Nebulin
Titin
M line
Actin
Myosin
1
2
3
One sarcomere
C CROSS SECTIONS OF THIN AND THICK FILAMENTS

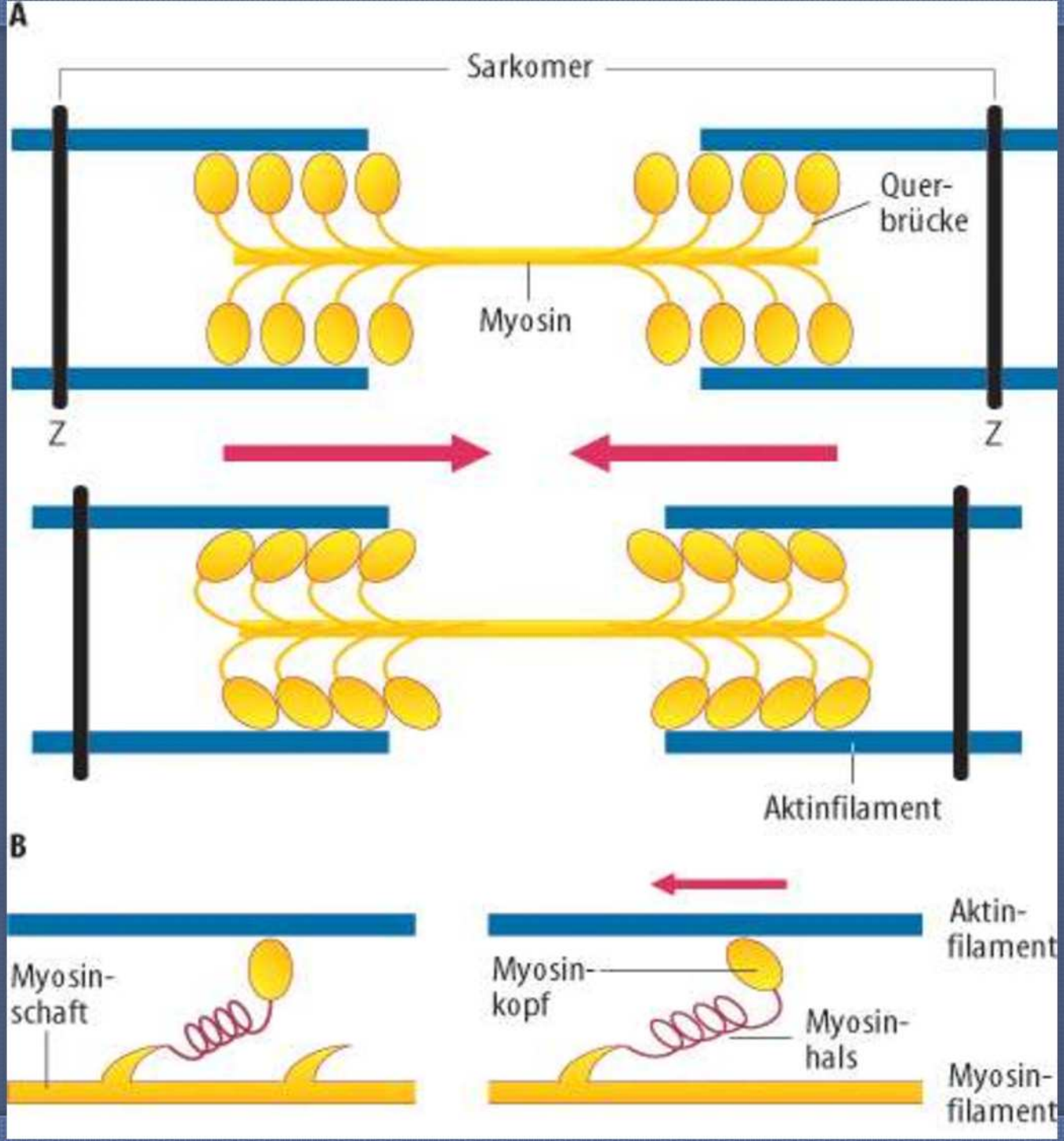
A
Sarkomer
Quer-
brücke
Myosin
Z
Z
Aktinfilament
B
Myosin-
schaft
Myosin-
kopf
Myosin-
hals
Aktin-
filament
Myosin-
filament

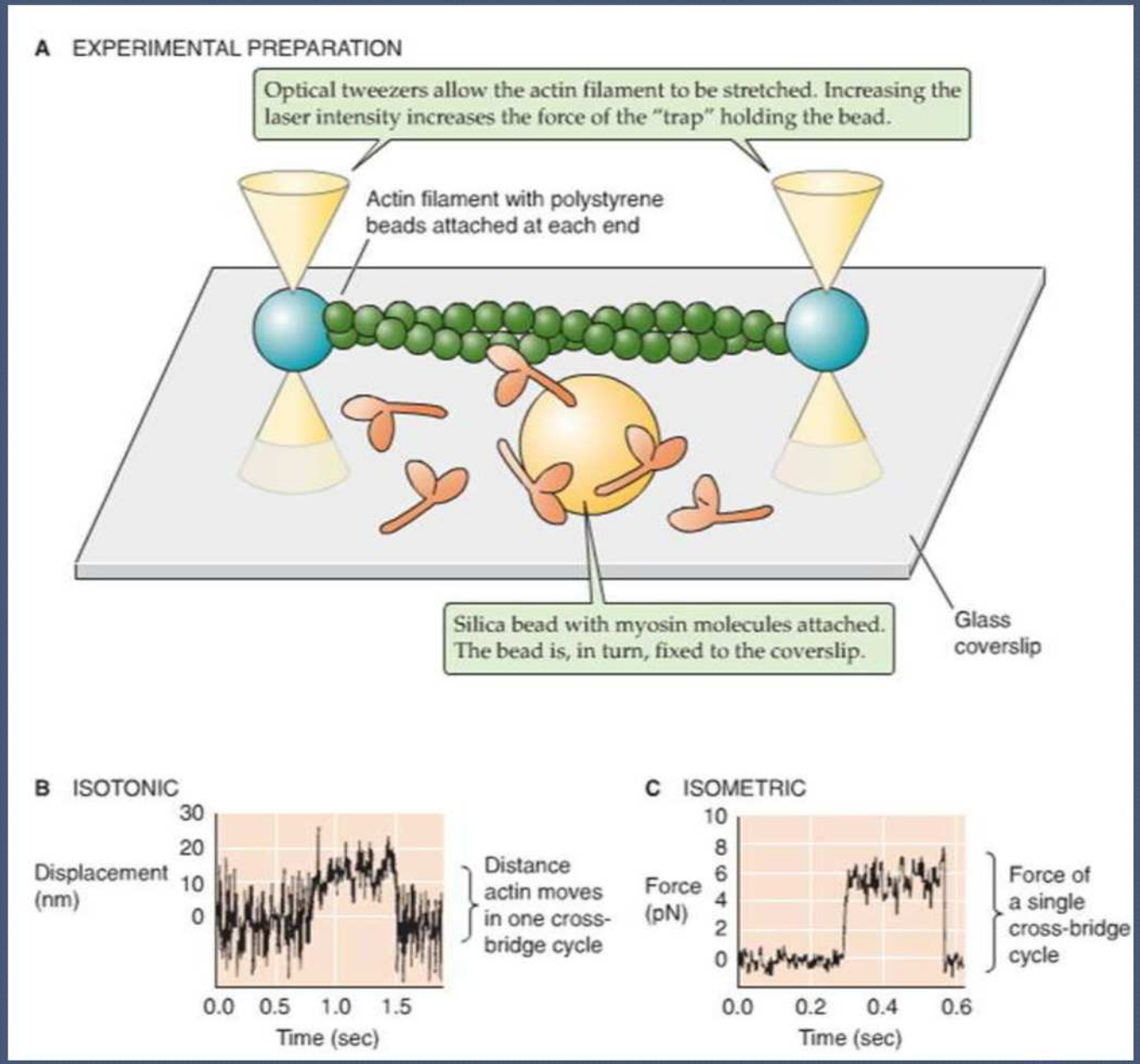
A EXPERIMENTAL PREPARATION
Optical tweezers allow the actin filament to be stretched. Increasing the laser intensity increases the force of the "trap" holding the bead.
Actin filament with polystyrene beads attached at each end
Silica bead with myosin molecules attached. The bead is, in turn, fixed to the coverslip.
Glass coverslip
B ISOTONIC
Displacement (nm)
30
20
10
0
0.0 0.5 1.0 1.5
Time (sec)
Distance actin moves in one cross-bridge cycle
C ISOMETRIC
Force (pN)
10
8
6
4
2
0
0.0 0.2 0.4 0.6
Time (sec)
Force of a single cross-bridge cycle

Boron, 2011

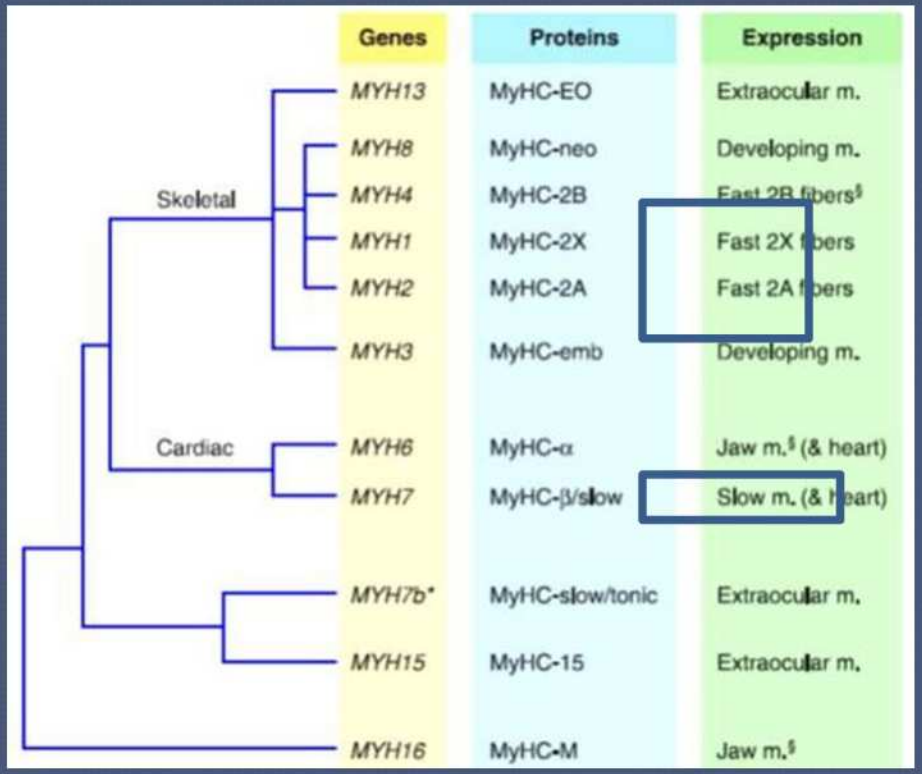

Sciaffino 2011

Energeetika

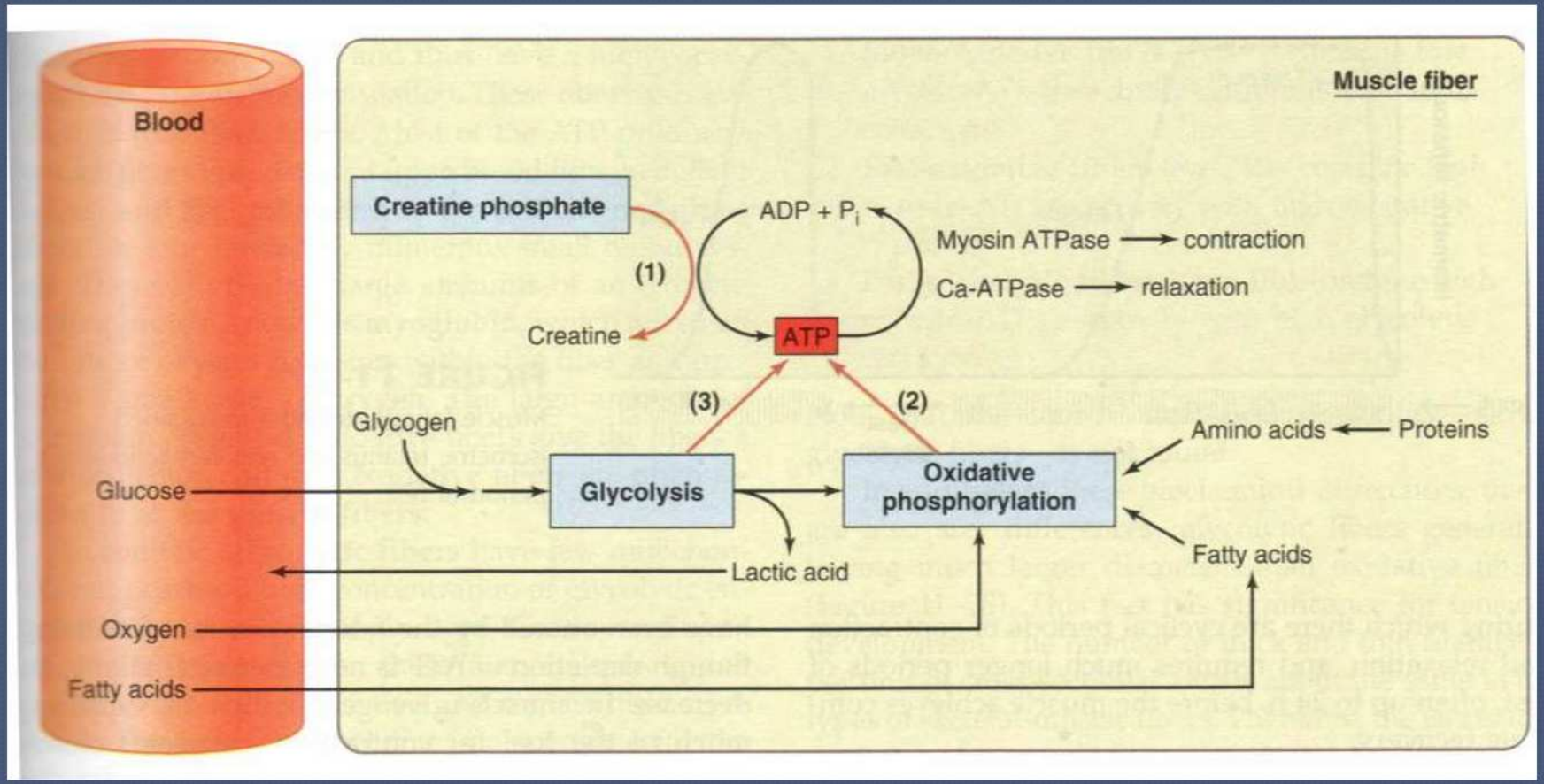

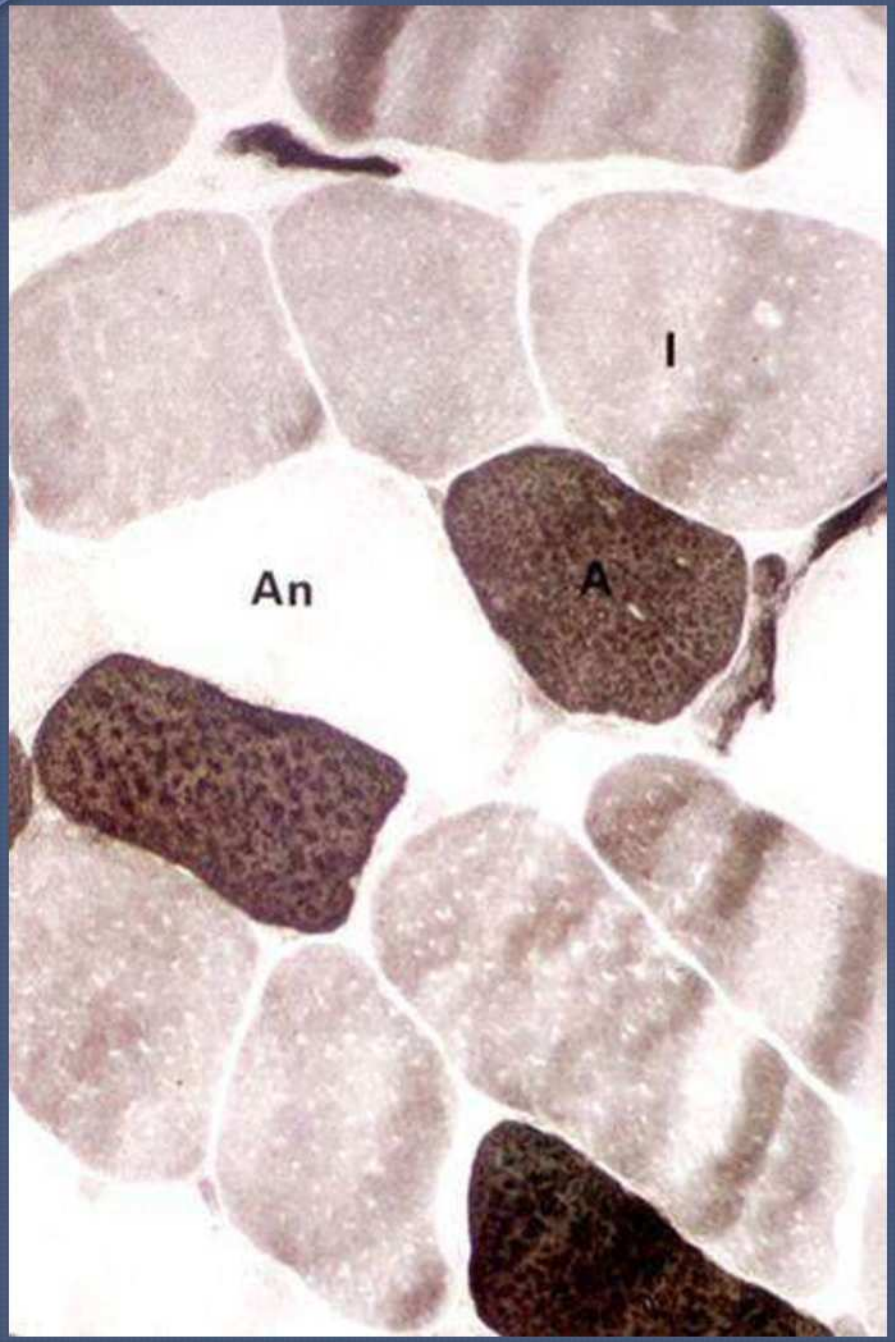
I
An
A

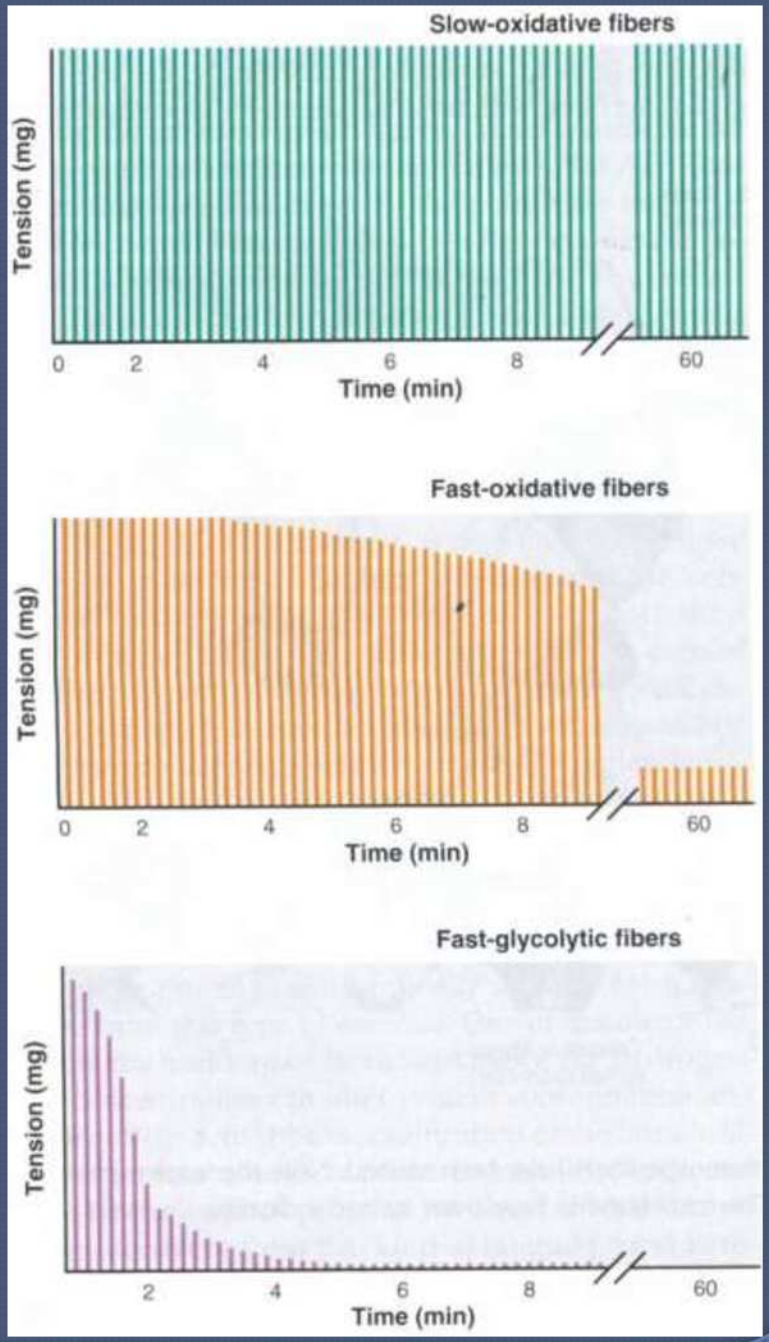
Slow-oxidative fibers
Tension (mg)
0
2
4
6
8
60
Time (min)
Fast-oxidative fibers
Tension (mg)
0
2
4
6
8
60
Time (min)
Fast-glycolytic fibers
Tension (mg)
2
4
6
8
60
Time (min)

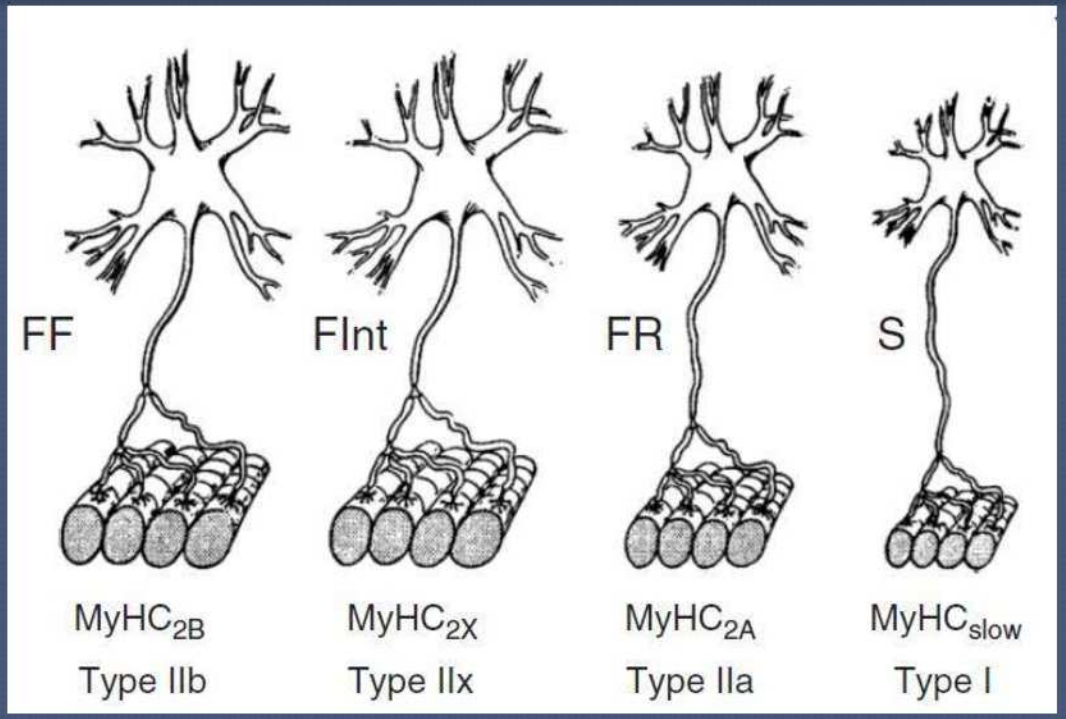
FF
FInt
FR
S
MyHC2B
Type IIb
MyHC2X
Type IIx
MyHC2A
Type IIa
MyHCslow
Type I

159


money
KIPSANG

Kuvamine - MRT

- T1, T2 / STIR
- Gd?
- pindmised mähised?
- spektroskoopia, DTI, BOLD???

Kuvamine - UH

- >10 MHz andur
- Pindmiselt hea lahutusvõime, vähem tundlik sügavate struktuuride osas
- Hea interaktsioon patsiendiga (dünaamiline hindamine)

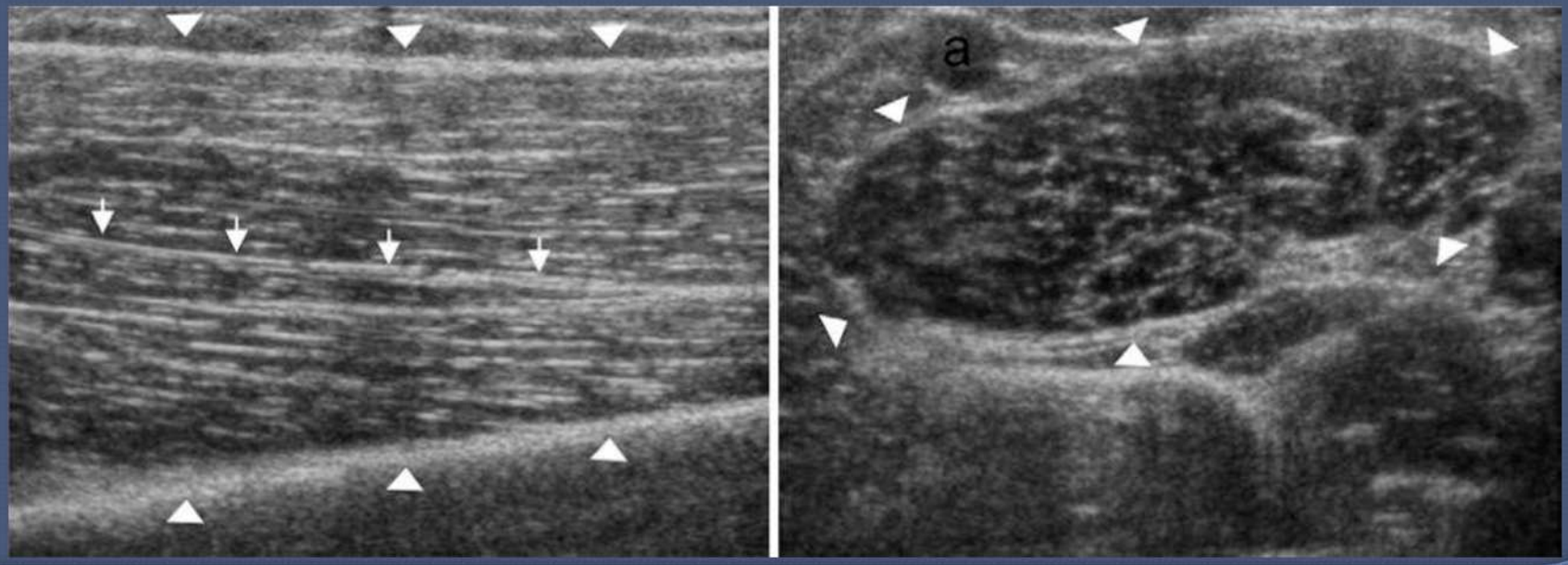

Anatoomilised variandid

- Aksessoorsed lihased
- Reeglina juhuleid
- Struktuurilt ja signaalilt vastab lihasele
- Kliiniliselt võib avalduda lisamassina
- Võib põhjustada närvikompressiooni

Aksessoorne *M. soleus*

M. peroneus quartus

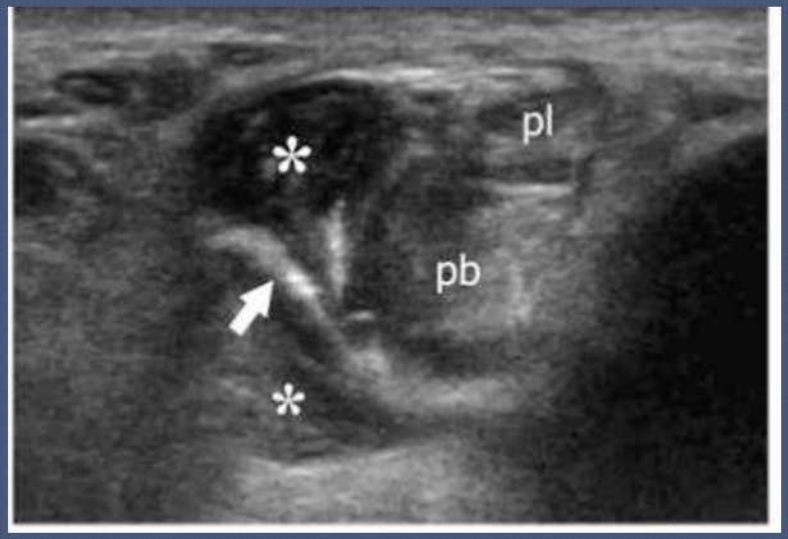

http://www.radsource.us/clinic/0811

Aksessoorne *M. abductor digiti minimi*

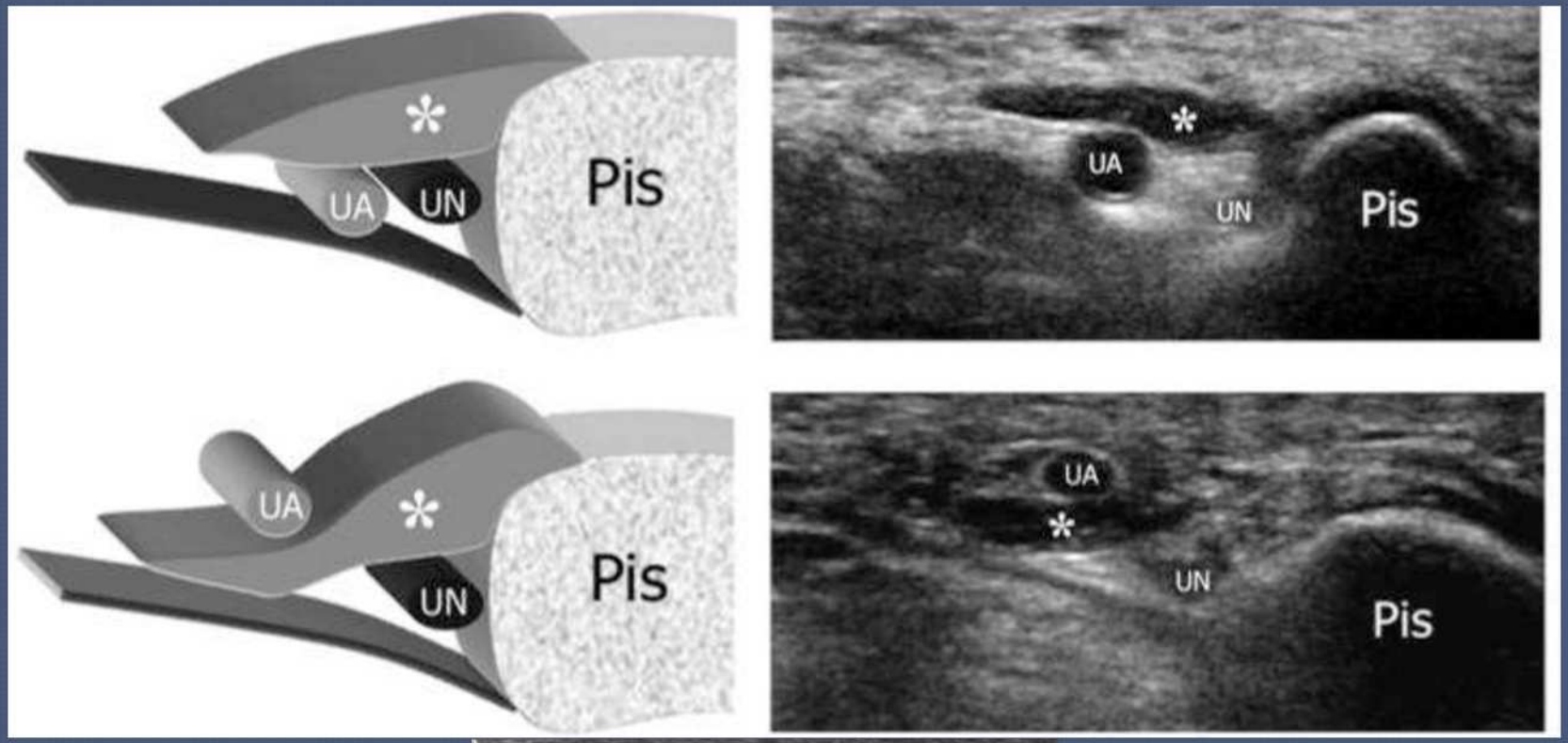

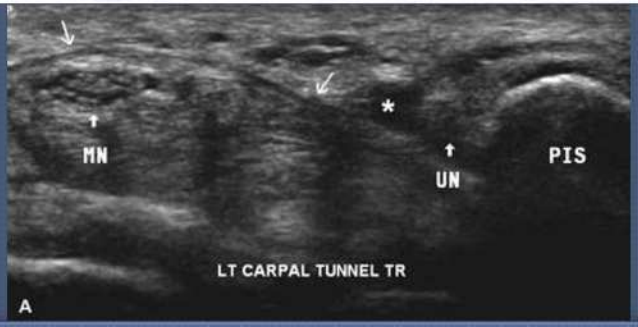

Martinoli 2010

M. anconeus epitrochlearis

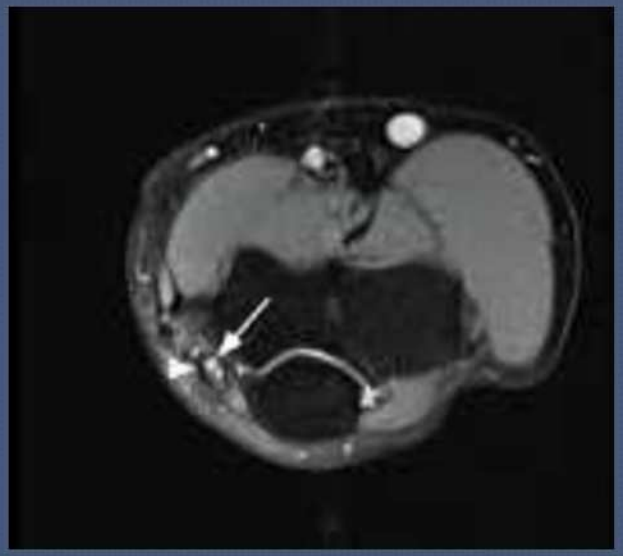

Lihas võib ka puududa – näit. Polandi sündroom

http://www.mskcases.com/index.php?module=article&view=36

Lihastrauma

- Kaudsed
- Otsesed (välisest faktorist)
  - kontusioon
  - latseratsioon
  - rõhk nekroos

DOMS

- = *Delayed Onset of Muscle Soreness*
- valu, turse, jõu langus
- algab 2-3 tundi peale koormust, maksimum 2-3 päeval, peale nädalat kaob
- reeglina juhuleid
- pöörduv strukturaalne kahjustus raku tasemel
- difuusne lihase suurenemine ja turseline signaalitõus (T2↑)
- UH-s ei näe

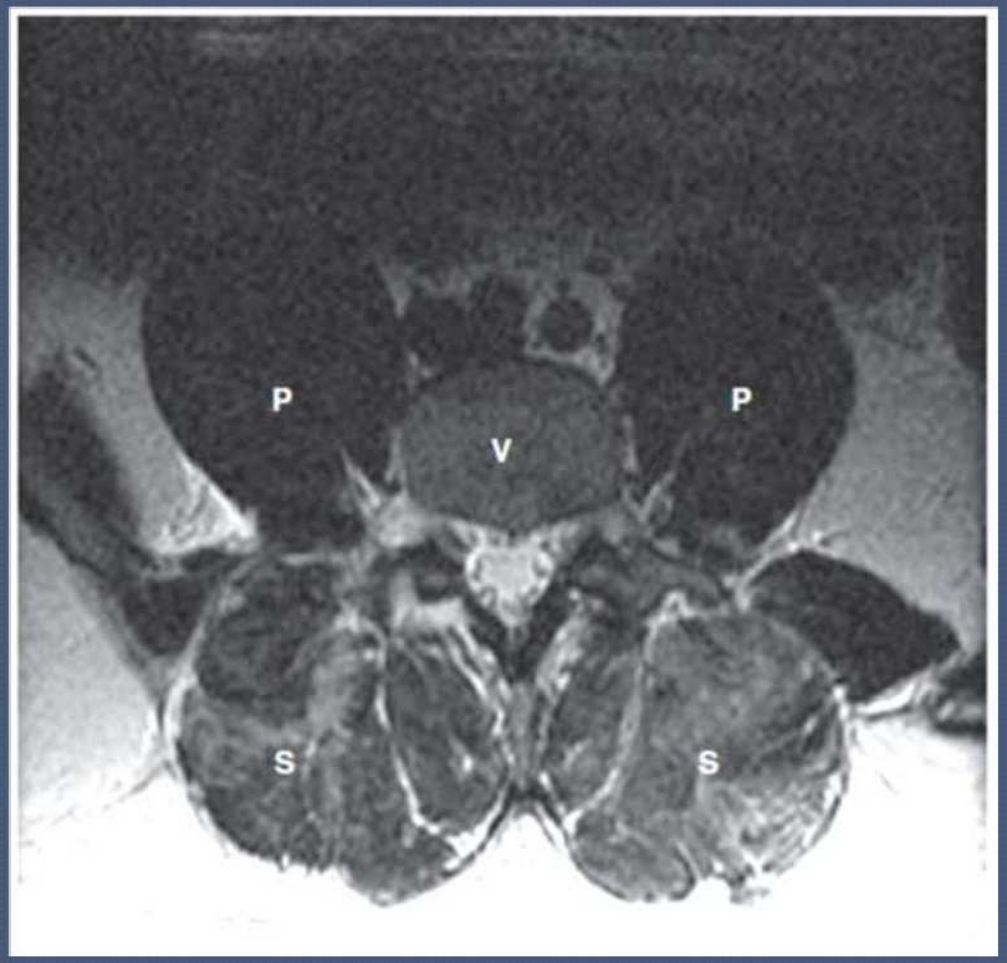
P
V
P
S
S

NB! mitte kõik muutused treeningu järgselt pole DOMS

enne

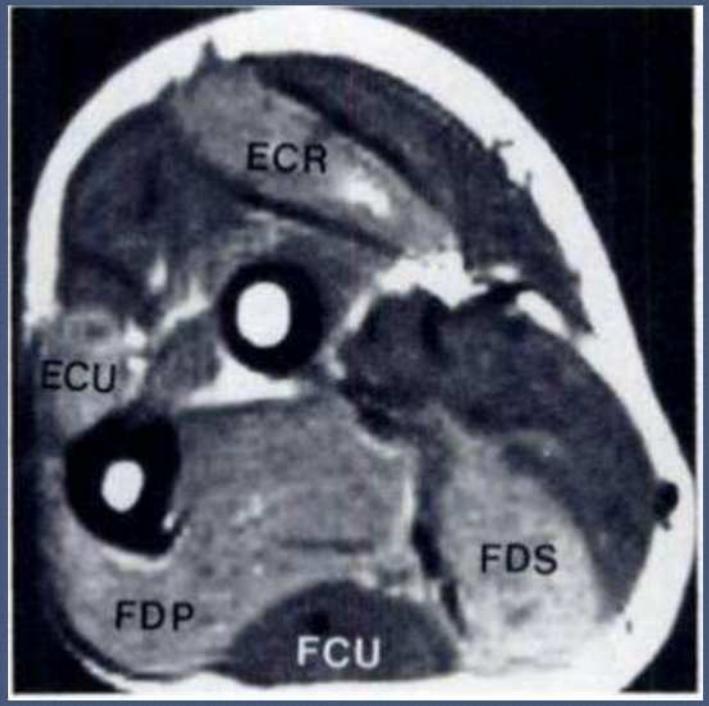

pärast, reeglina kaob poole tunni jooksul

Fleckenstein 1988

Lihasvenitus, -rebend (*strain*)

- sagedaseim spordivigastus
- reeglina lihastes, mis ületavad kahte liigest
- ekstsentrilise kontraktsiooni ajal
- kiirete (II tüübi) lihaskiudude rikastes lihastes
- akuutne valu
- üldiselt venistuskahjustuse lokalisatsioon sõltub vanusest
  - Lapsed, noorukid – apofüüs
  - Täiskasvanud – lihas-kõõlusüleminek
  - Vanemad inimesed – kõõlus

Apofüüsi avulsioon

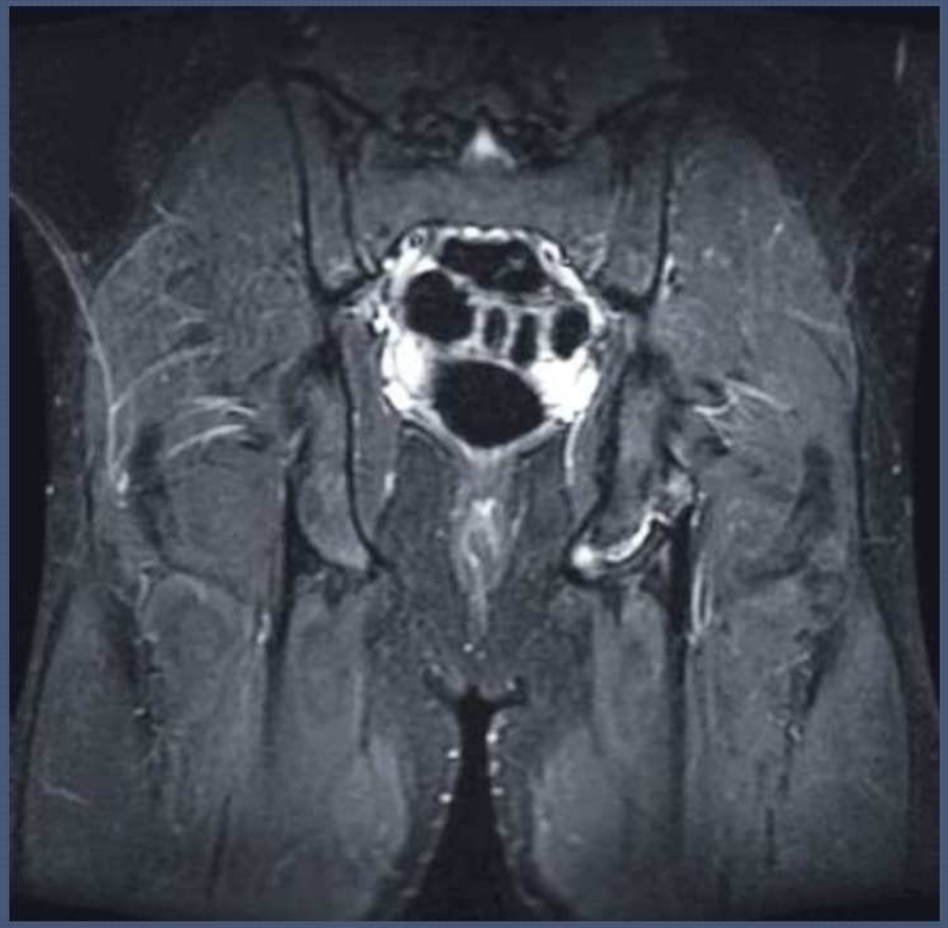

Lawrimore 2009

Krooniline apofüüsi avulsioonkahjustus

Lihas-kõõlus üleminek

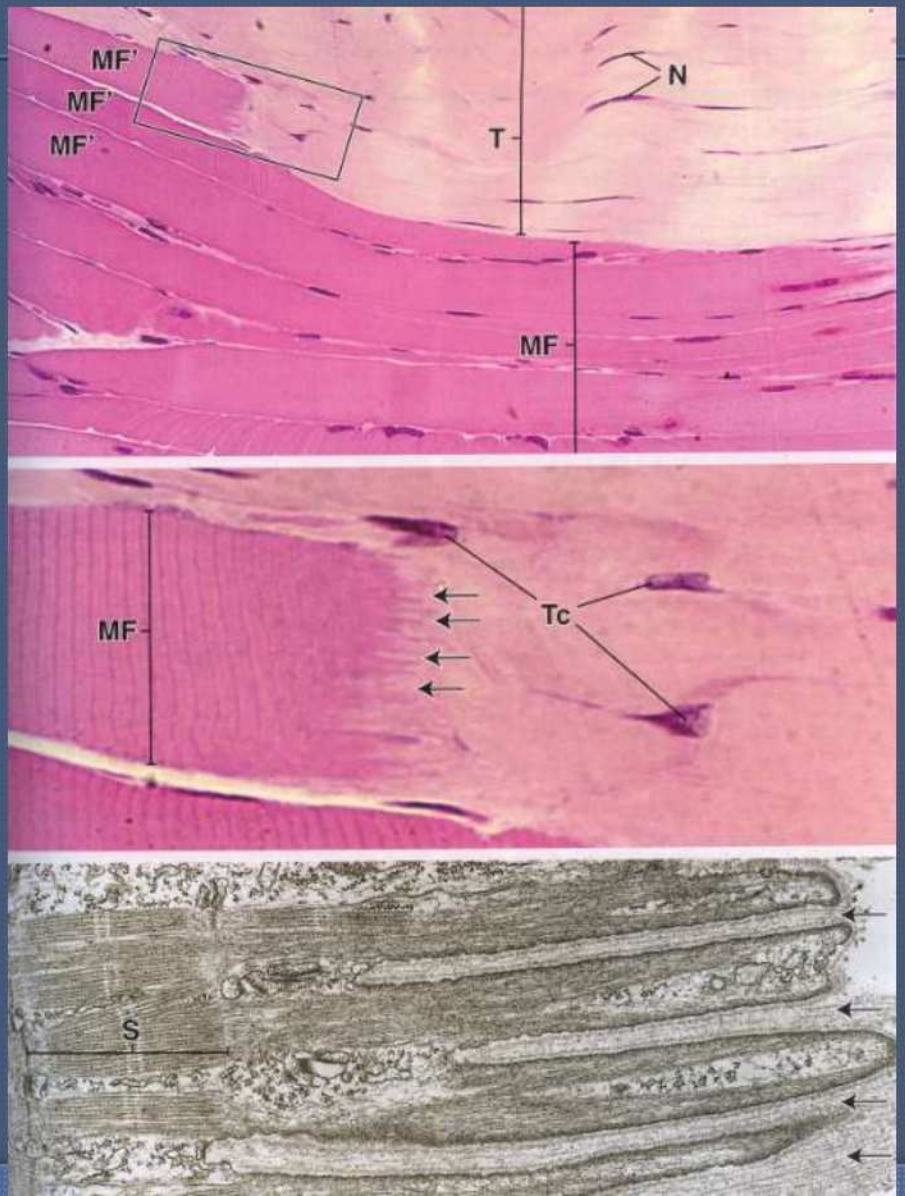

Ross, 2010

Klassifikatsioon

TABLE 12-1. Grading of Myotendinous Strain Injuries

Grade	Injury	Degree of Fiber Disruption
Grade 1 strain	Stretch	Microscopic
Grade 2	Partial tear	Macroscopic
Mild Moderate Severe		Less than one third Between one third and two thirds Greater than two thirds
Grade 3	Complete tear	Rupture

Lihasrebend

- Trauma järgselt eristatakse kolme faasi:
  - destruktsioonifaas (*destruction*)
  - paranemisefaas (*repair*)
  - remodelleerumisfaas (*remodelling*)
- II ja III astme rebendid paranevad halvemini (korduvad mikrorebendid, hemorraagia lihase kontraheerumisel)
- Varasem vigastus tõstab kordumise tõenäosust, isegi kui erinevas lihases, aga esinenud samas lihasrühmas

UH

- esimese 24 tunni jooksul erineva välimusega (anehhogeensest hüperehhogeenseni)
- 2-3 päeva jooksul hakkab muutuma järjest hüpo- ja anehhogeensemaks, võib muutuda heterogeenseks

MRT-s

Table 9.3 MRI grading and appearance in muscle strain

Grade	MR imaging	Additional findings
Grade I	Increased SI on T2W FS/STIR images at the MTJ due to oedema and haemorrhage, tracking along the muscle fascicles producing a feathery pattern	Peri-fascial fluid in 87% of athletes with partial muscle injury
Grade II	Increased SI on T2W FS/STIR images with haematoma formation at the MTJ (typical finding) and peri-fascial oedema; Tendon may thinned, irregular and lax	Focal, stellate-shaped muscle defect may be present; an old second-degree strain may be recognized by the presence of low T2W SI due to haemosiderin, fibrosis and muscle atrophy
Grade III	Complete muscle disruption with haematoma bridging the gap between retracted segments; stage of a haematoma is determined depending on T1W and T2W signal characteristics	Muscle atrophy may begin as early as 10 days after the injury and may be irreversible by 4 months

Grade I

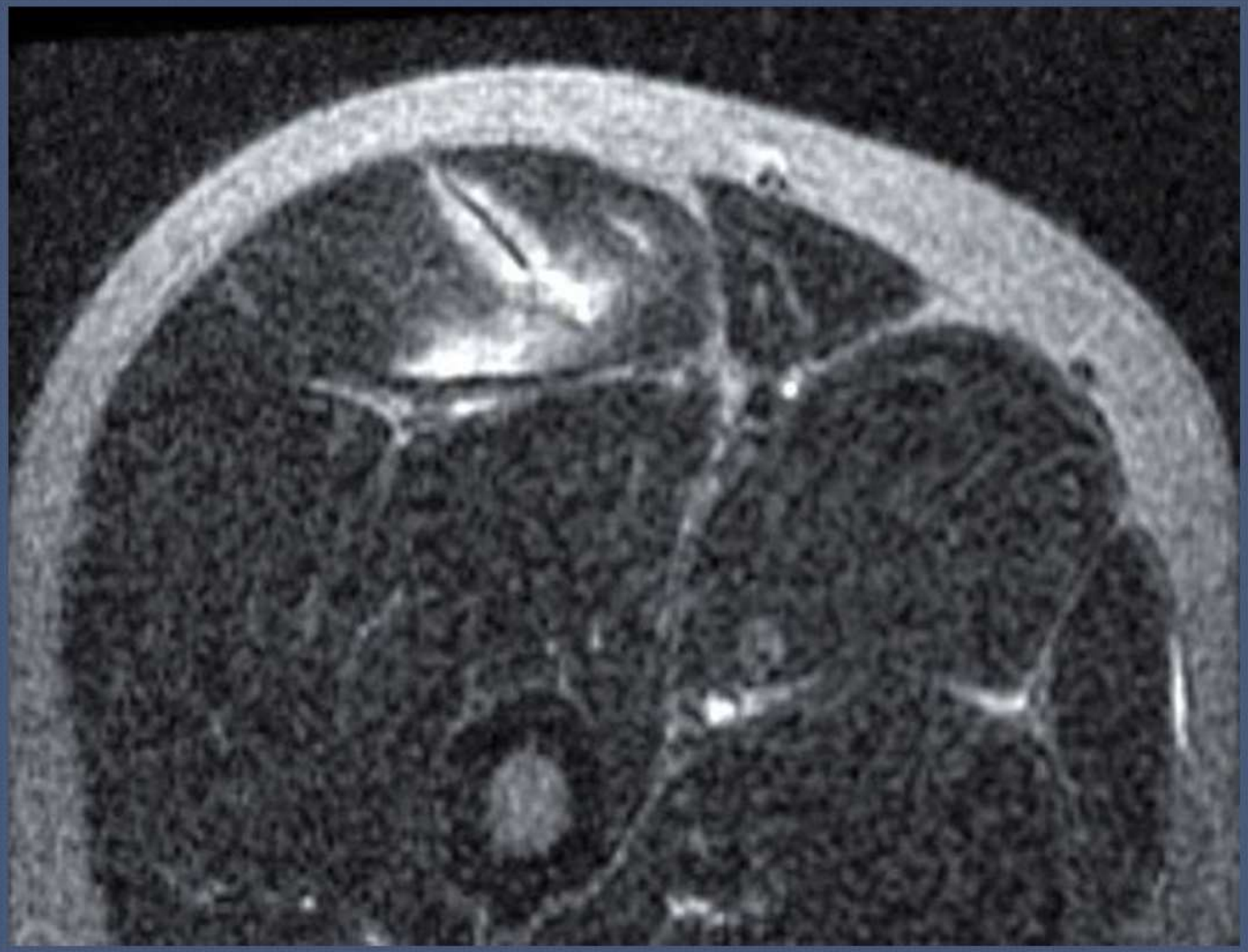

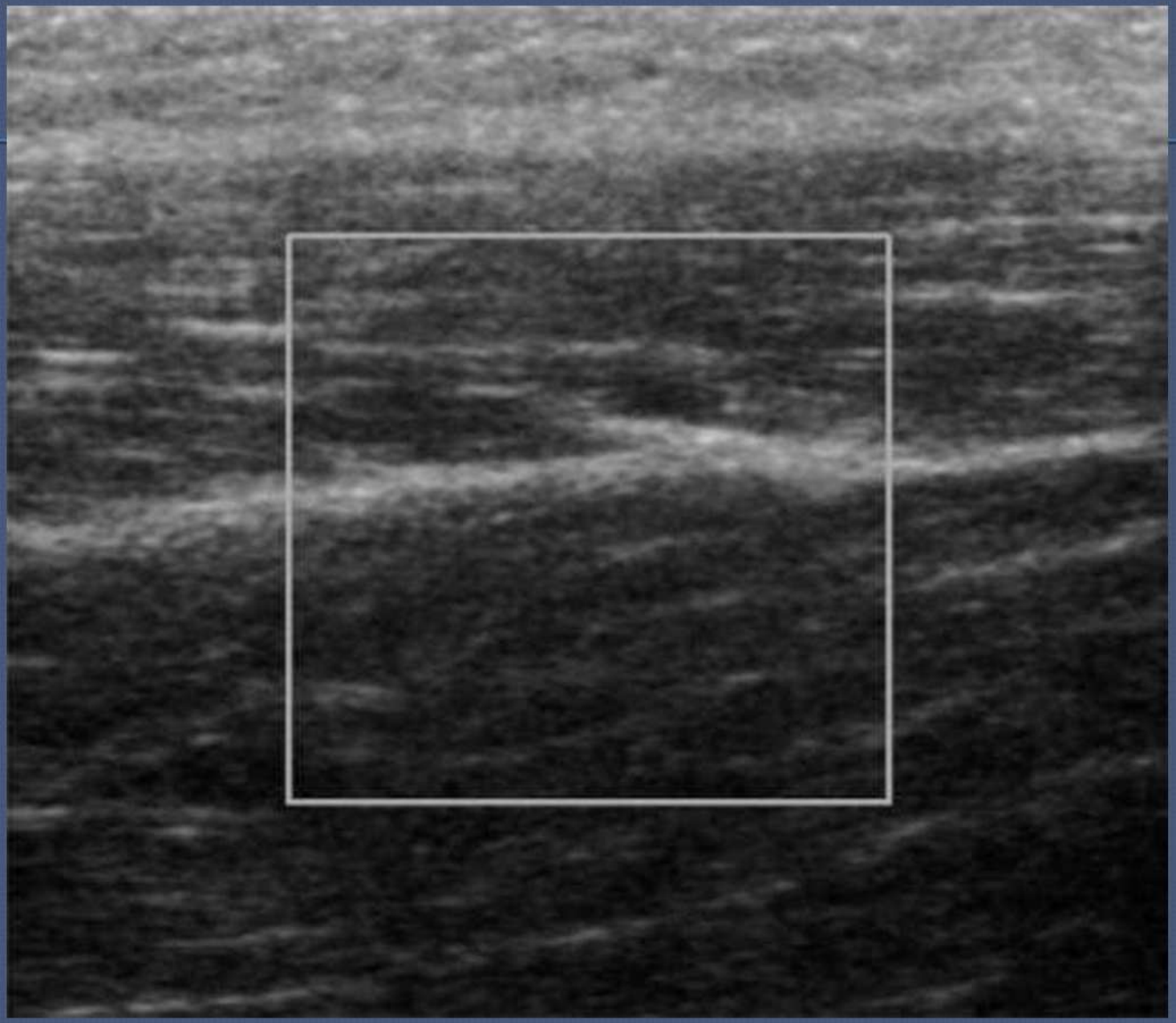

Woodhouse JB & McNally EG, 2011

Grade II

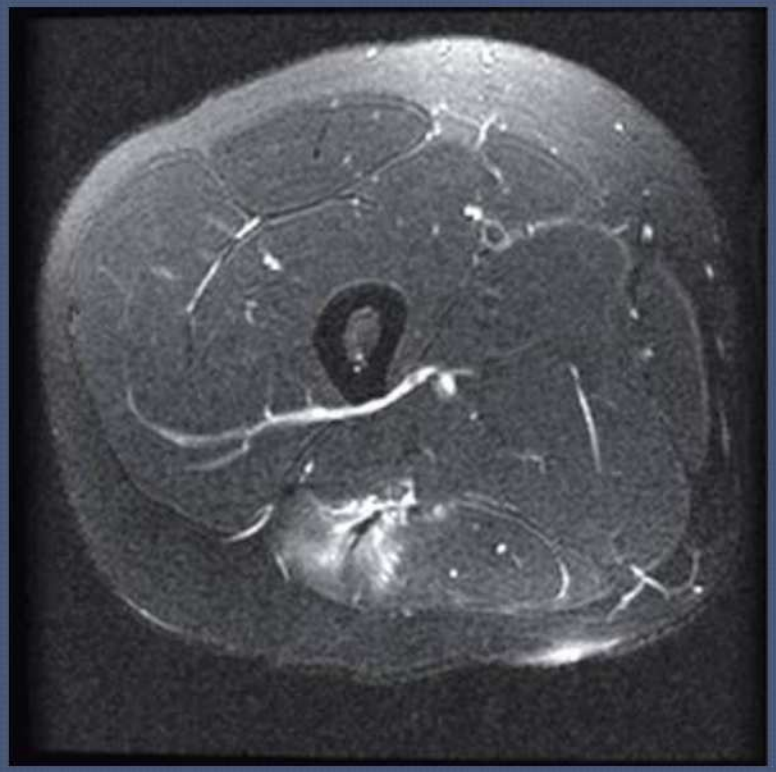

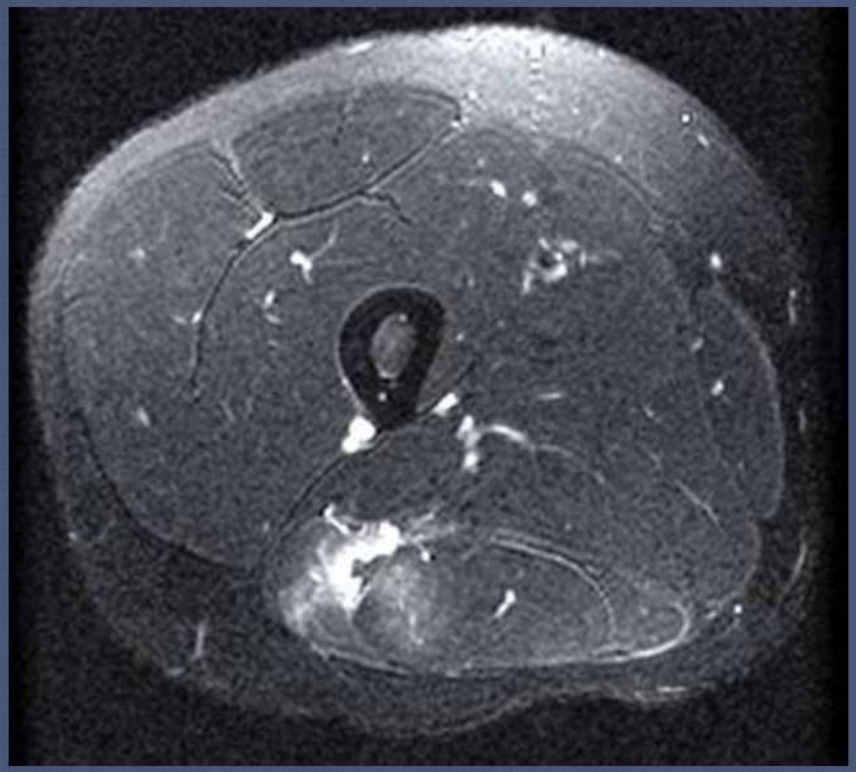

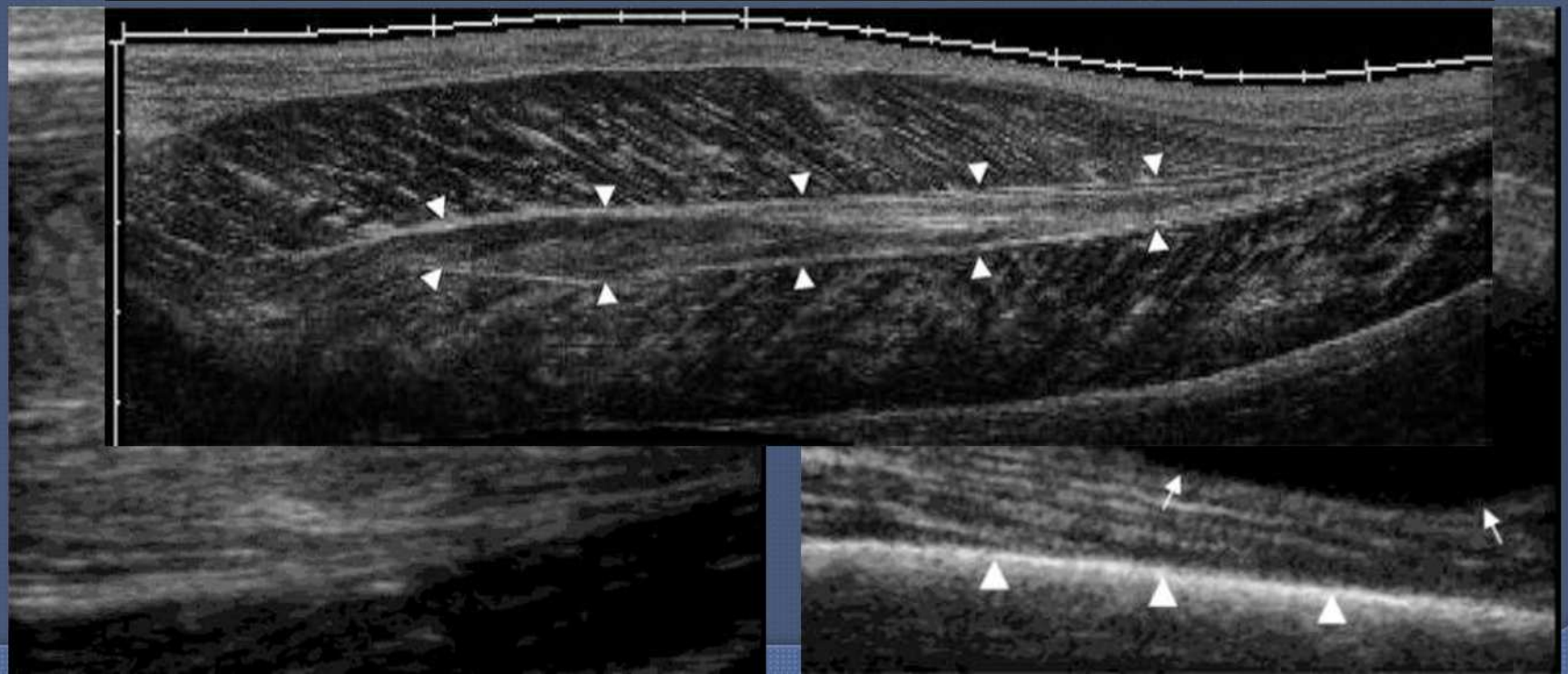

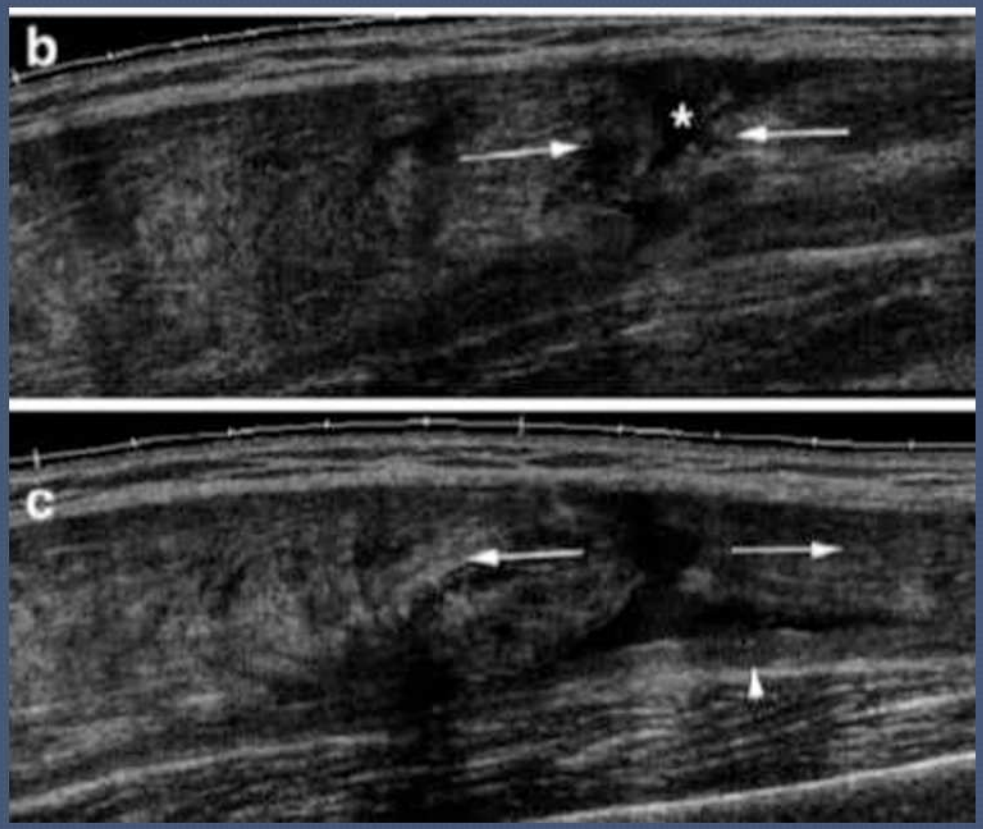

Datir 2010

Grade III

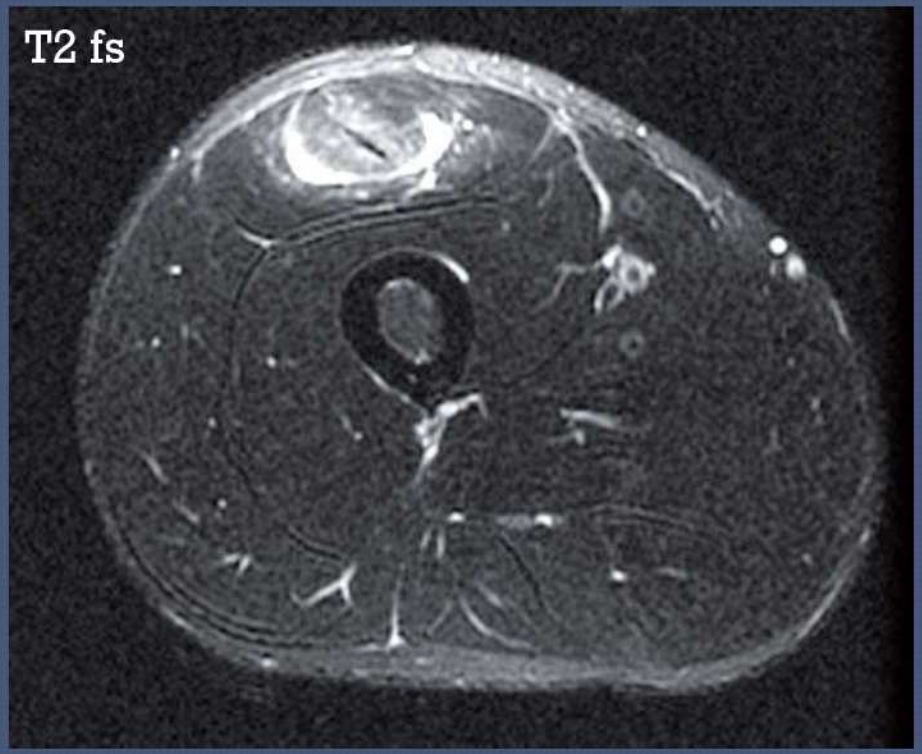

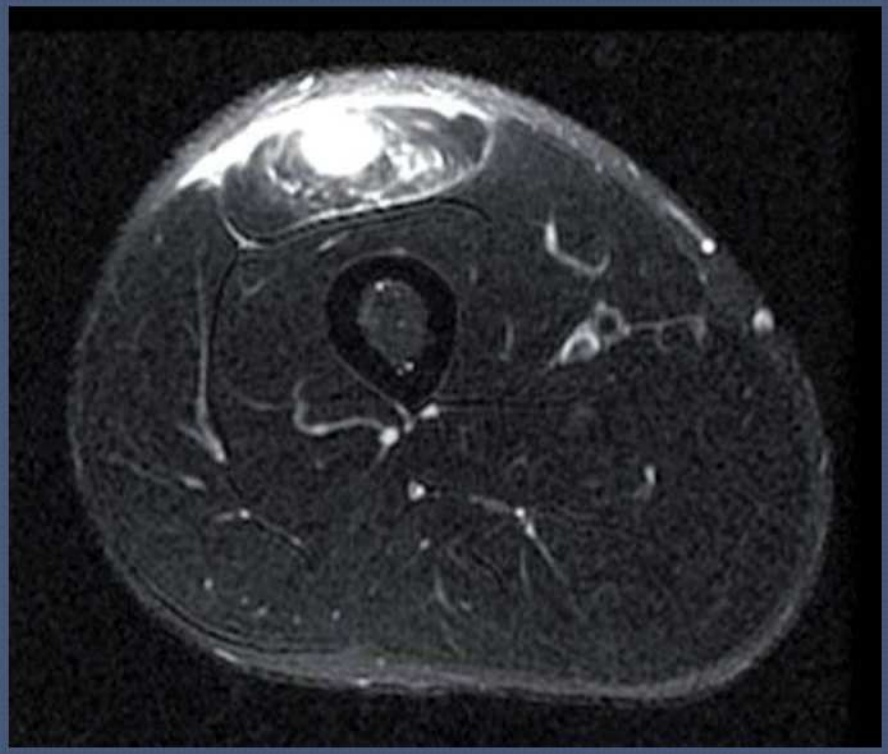

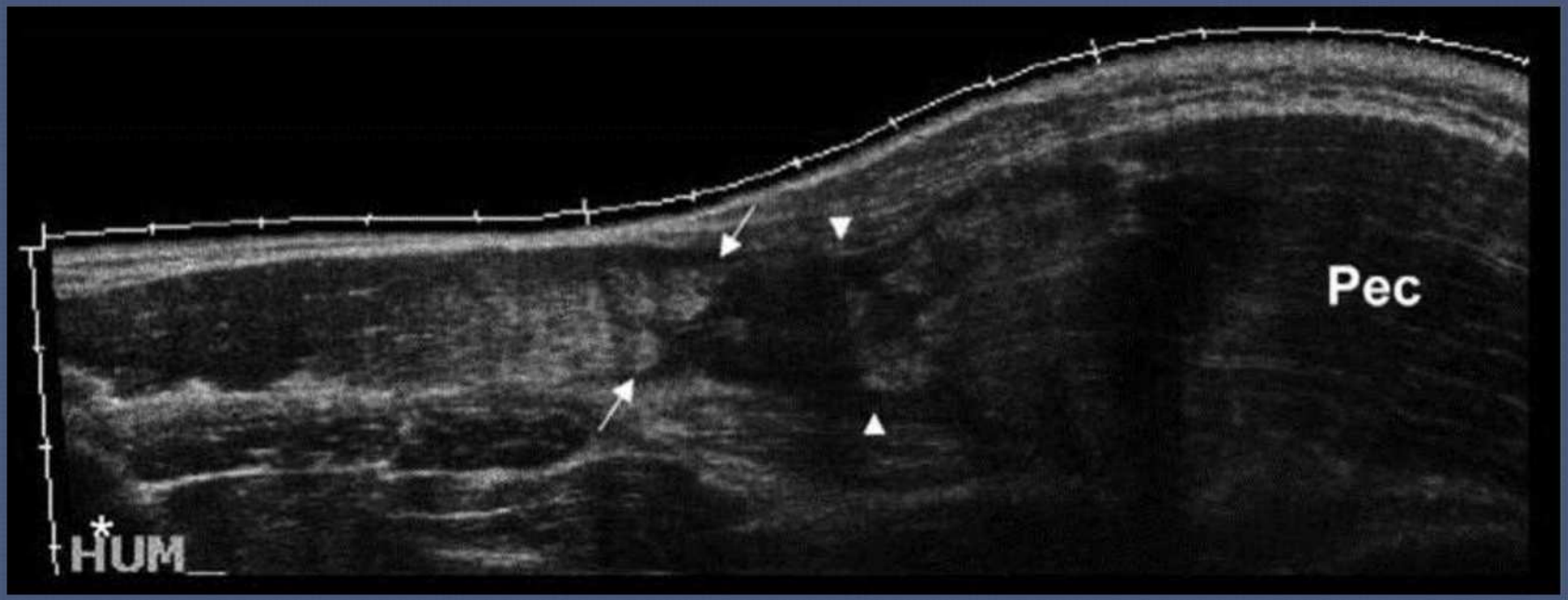
Pec
*HUM_

Kõõluse vigastus

Lihaskontusioon

- reeglina tõmbi trauma tagajärjel, sageli lihas surutakse vastu luud
- lihaskiudude ja kapillaarringe katkemine, (mikro)hemorraagiad
- turse, valu, nõrkus, ROM vähenemine
- Kui kontusioon väga tugev võib müonekroosi esineda. Muidu võib pildiliselt olla suhteliselt sarnane I ja II astme rebendiga, kuid ei ole reegline kõõluseks ülemineku piirkonnas.

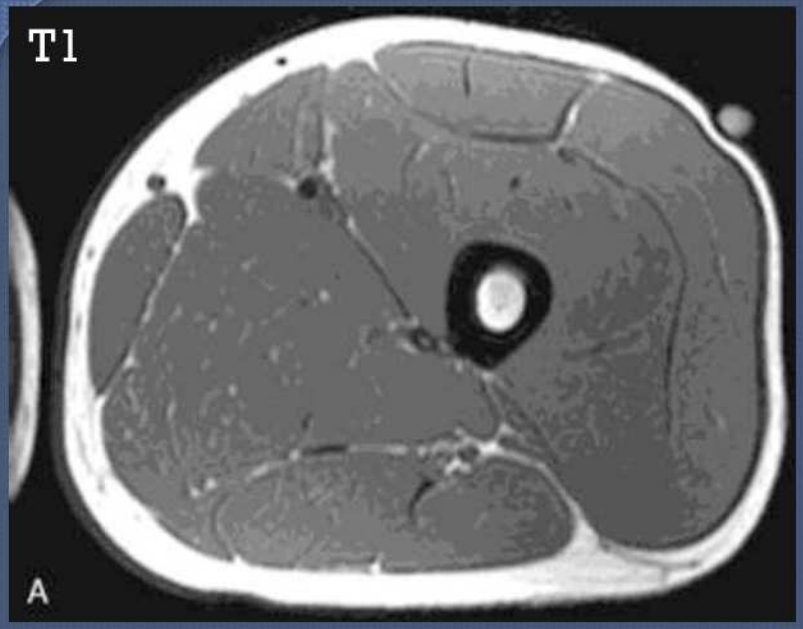

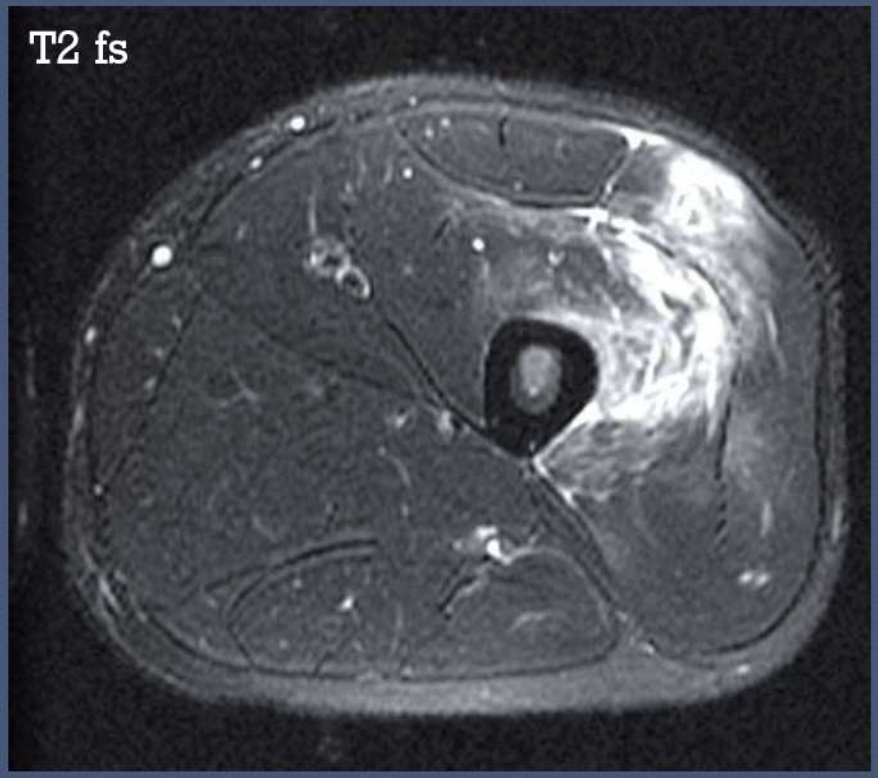

Lawrimore 2009

Woodhouse 2011

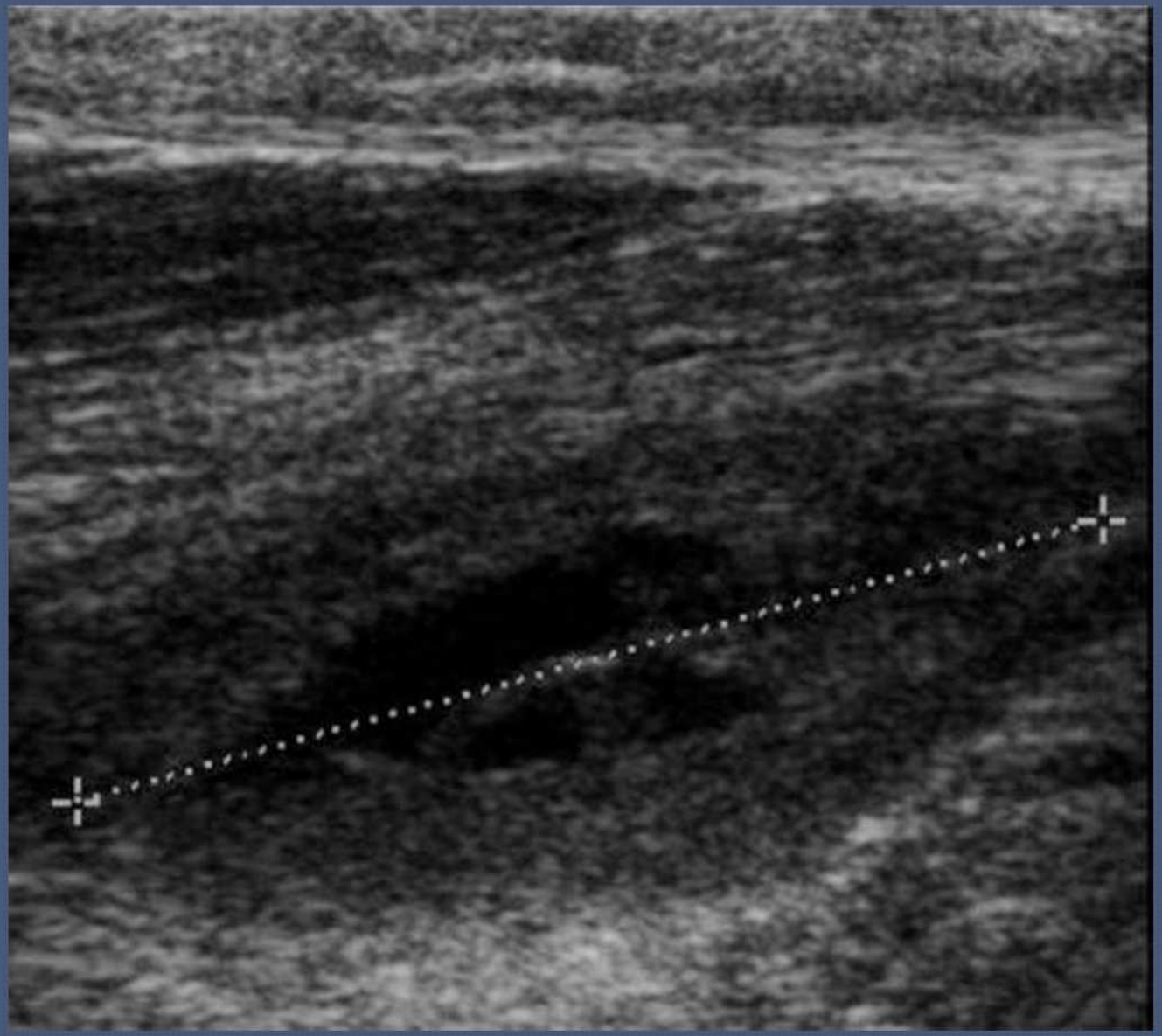

Lihaslatseratsioon

- penetreeriv trauma
- kuvamine, kui neurovaskulaarse või parenhümatoosse organi vigastuse kahtlus
- lihase katkemine, turse, hemorraagia, sageli lineaarses konfiguratsioonis piki penetreerivat vigastust, gaasi pehmes koes
- Hilises faasis võib tekkida rasvatroofia, fibroos, herniatsioon

Kuulihaav

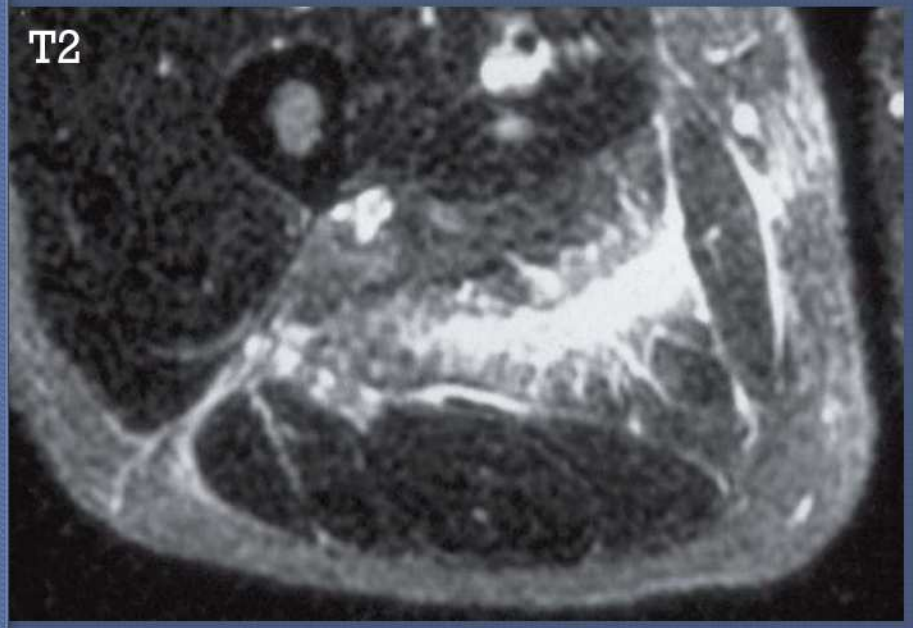

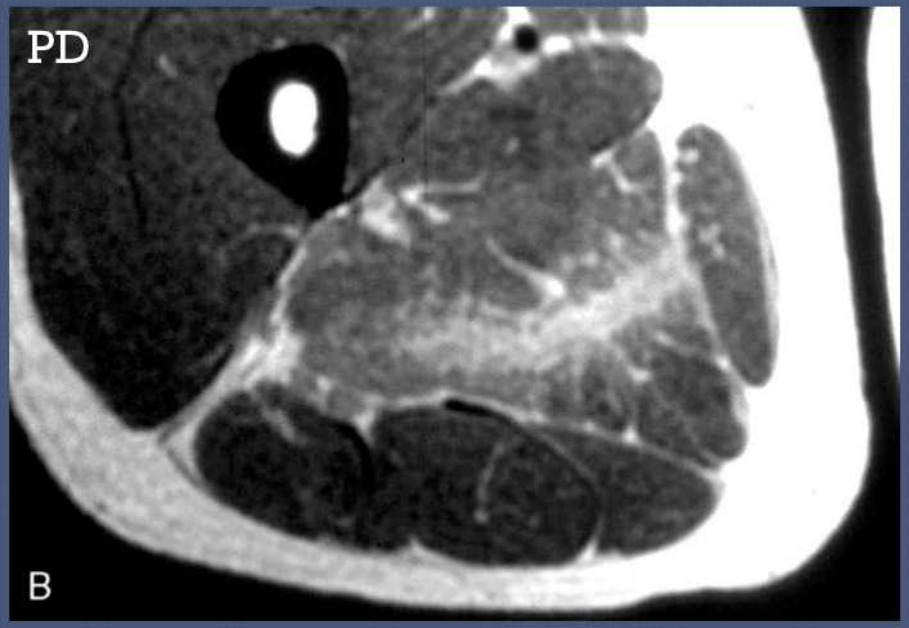

Lawrimore 2009

Lihase herniatsioon

- läbi fastsia lõhe või defekti
- kas lihashüpertroofiast või trauma järgselt (nii penetreeruv kui tömp)
- patsient kaebab mingit massi, mis suureneb lihasaktiivsuse ajal
- sagedasim jala eesosas
- võib kaasneda valu, lokaalne tundlikkusetõus
- ravi konservatiivne, olulise sümptomaatikaga ka fastsia reparatsioon, fastsiotoomia

dünaamiline UH > MRT?

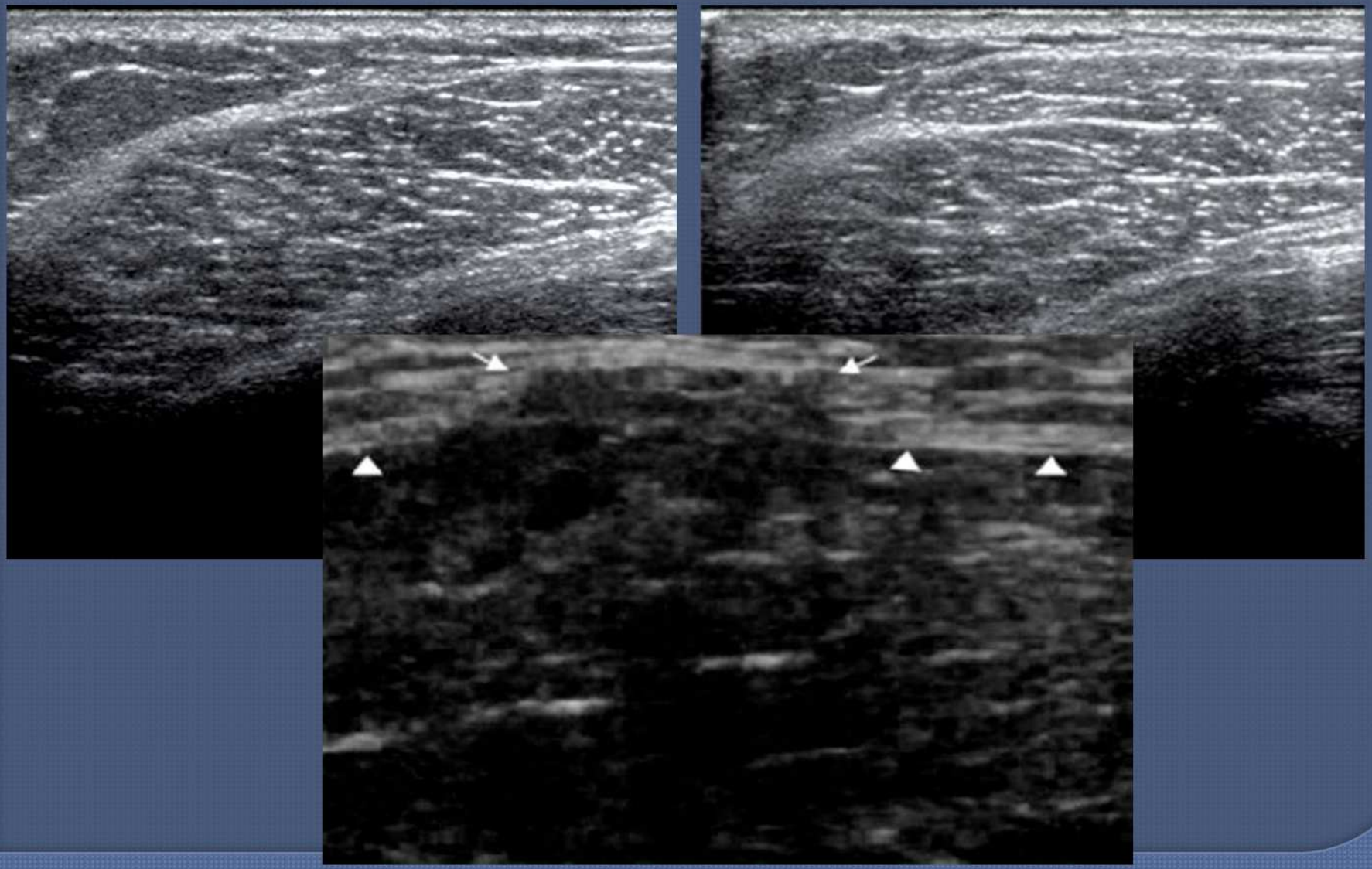

Hemorraagia

- lihasesisene
  - harvem, kliiniliselt halvemini avastatav, paraneb kauem (6-8 nädalat)
- lihaste vaheline
- Hematoom võib organiseeruda, resorbeeruda, võib tekkida armkude

Table 9.4 Progression of muscle haematoma on MRI

Stage		Blood products	T1 signal	T2 signal
Hyperacute		Oxyhaemoglobin	Intermediate	Hyperintense
Acute		Deoxyhaemoglobin	Intermediate	Hypointense
Subacute	Early	Intracellular methaemoglobin	Hyperintense	Hypointense
	Late	Extracellular methaemoglobin	Hyperintense	Hyperintense
Chronic		Haemosiderin	Hypointense	Hypointense

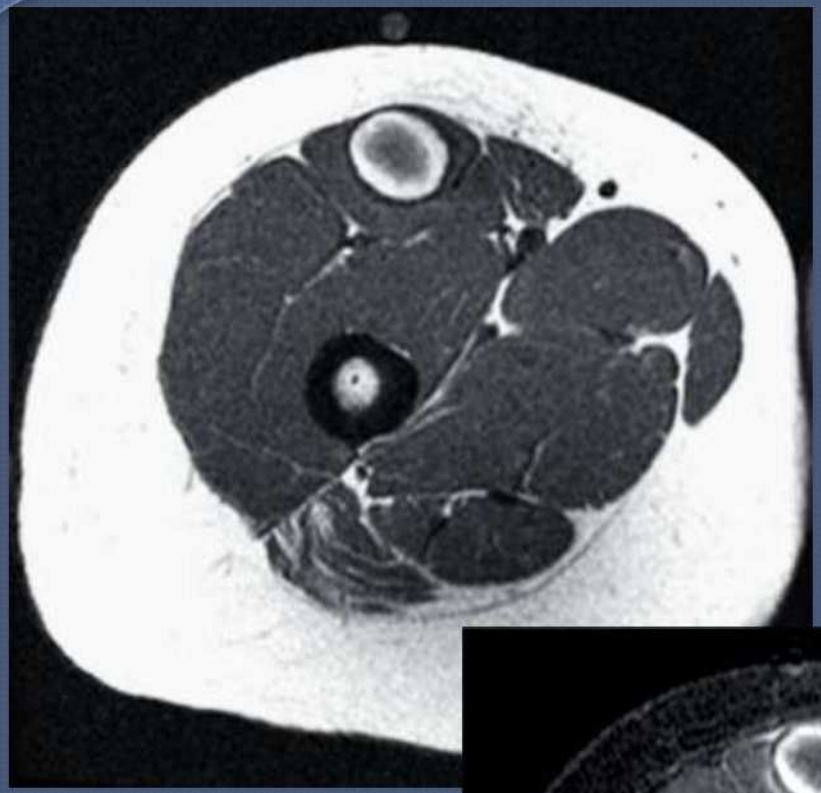
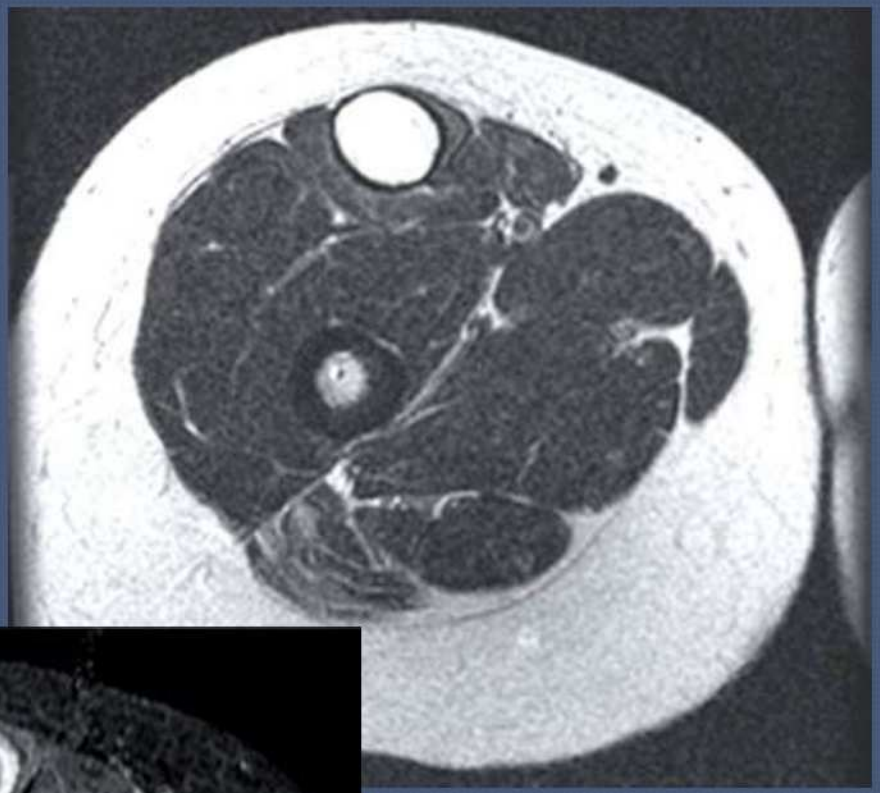
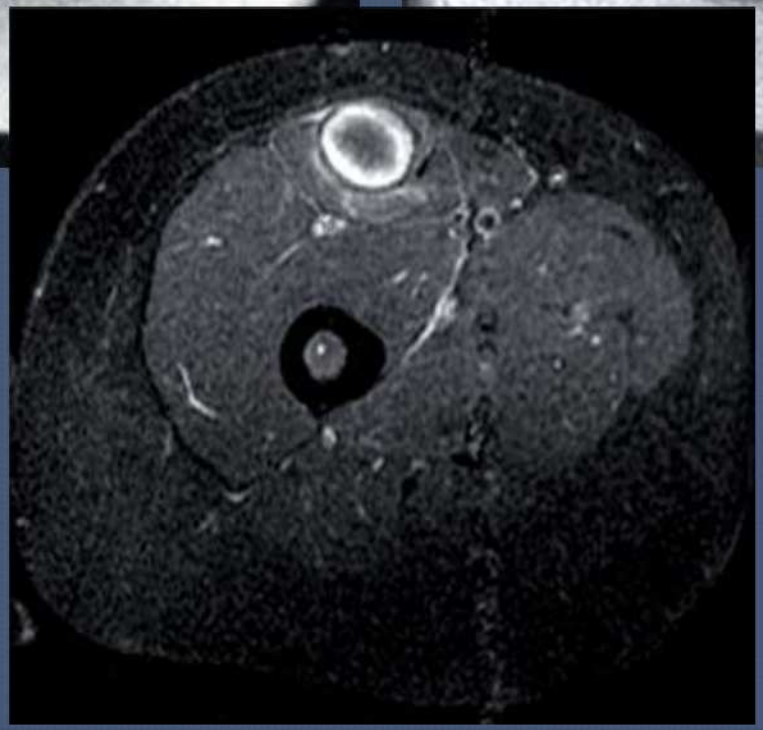

Hematoom vs. kasvaja?

- reeglina ei ole seotud kõõlus üleminekuga, kui on seal piirkonnas, siis pigem massiefektida lükkab viimast eemale, kui, et ümbritseks või katkestaks seda
- ka kasvaja võib verduda ja sisaldada verekomponentidele tüüpilist signaali, kui ei kontrasteeru, siis reeglina välistab, muidu võib ka hematoomi ümber olla põletikulist reaktsiooni
- kui jääb kahtlus, vajalik korduv uuring või biopsia

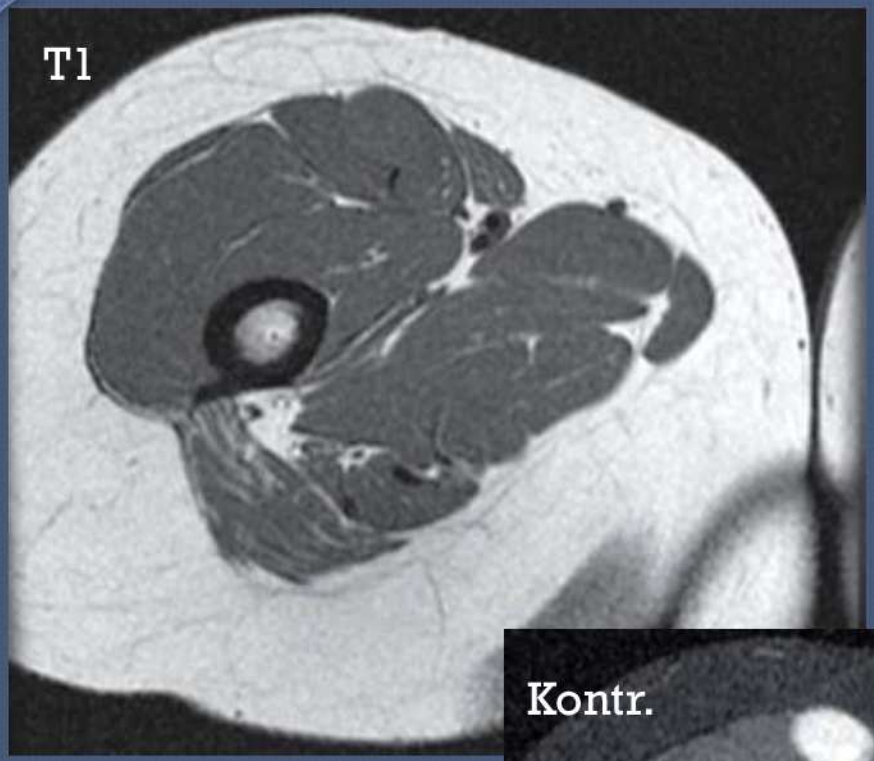
T1

T2

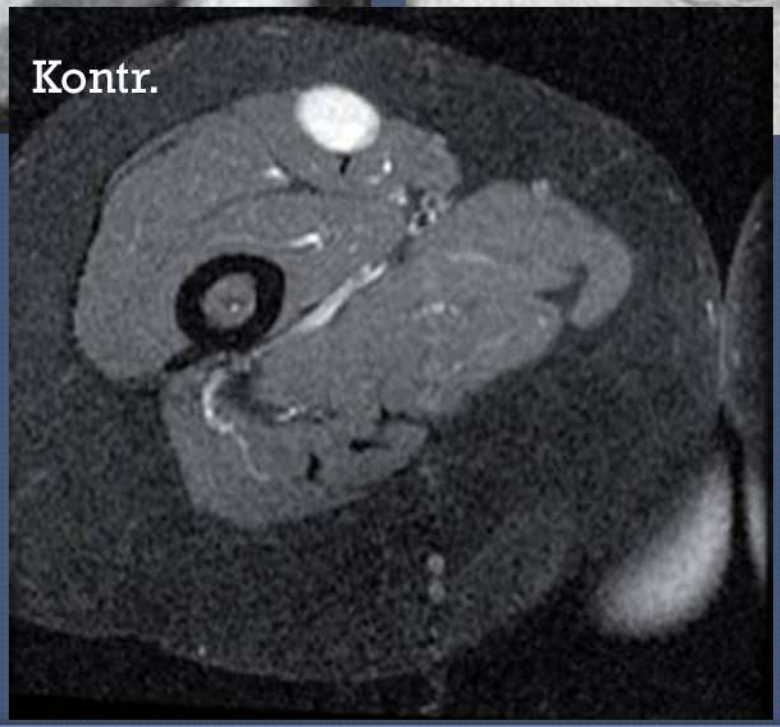
Kontr.

RAVI

- RICE (rest, ice, compression, elevation) + rehabilitatsioon
- Farmakoloogiline
  - lokaalsed anesteetikumid, kortikosteroidid, hüaluroonhape, skleroseerivad ained, proloteraapia, aprotiniin
  - trombotsüütide rikas plasma – PDGF, TGF-b, VEGF, FGF, IGF-1,2 jne.
  - Traumeel S – homöopaatiline taimne preparaat (põletikuvastane?)
  - Actovegin – valguvaba vasika seerum
- Operatiivne, hematoomide aspiratsioon jne.
- Aktiivsuse taastamine alles peale paranemist – korduva trauma oht – rohkem armkude/lihastalitluse häirumine – oht uutele traumadele
- Puudub teaduslik baas, kas kuvamisel leiu kadu on piisav tervistumine treenimise jätkamiseks

Campbell & Dunn, 2012

Trauma järgne leid

- Armi moodustumine – madal SI kõigis sekventsides, sarnane kõõlusele. UH-s lineaarne või ebaregulaarne struktuur, mida võib ümbritseda halo
- Rasvatroofia
- *Myositis ossificans*

Armkude

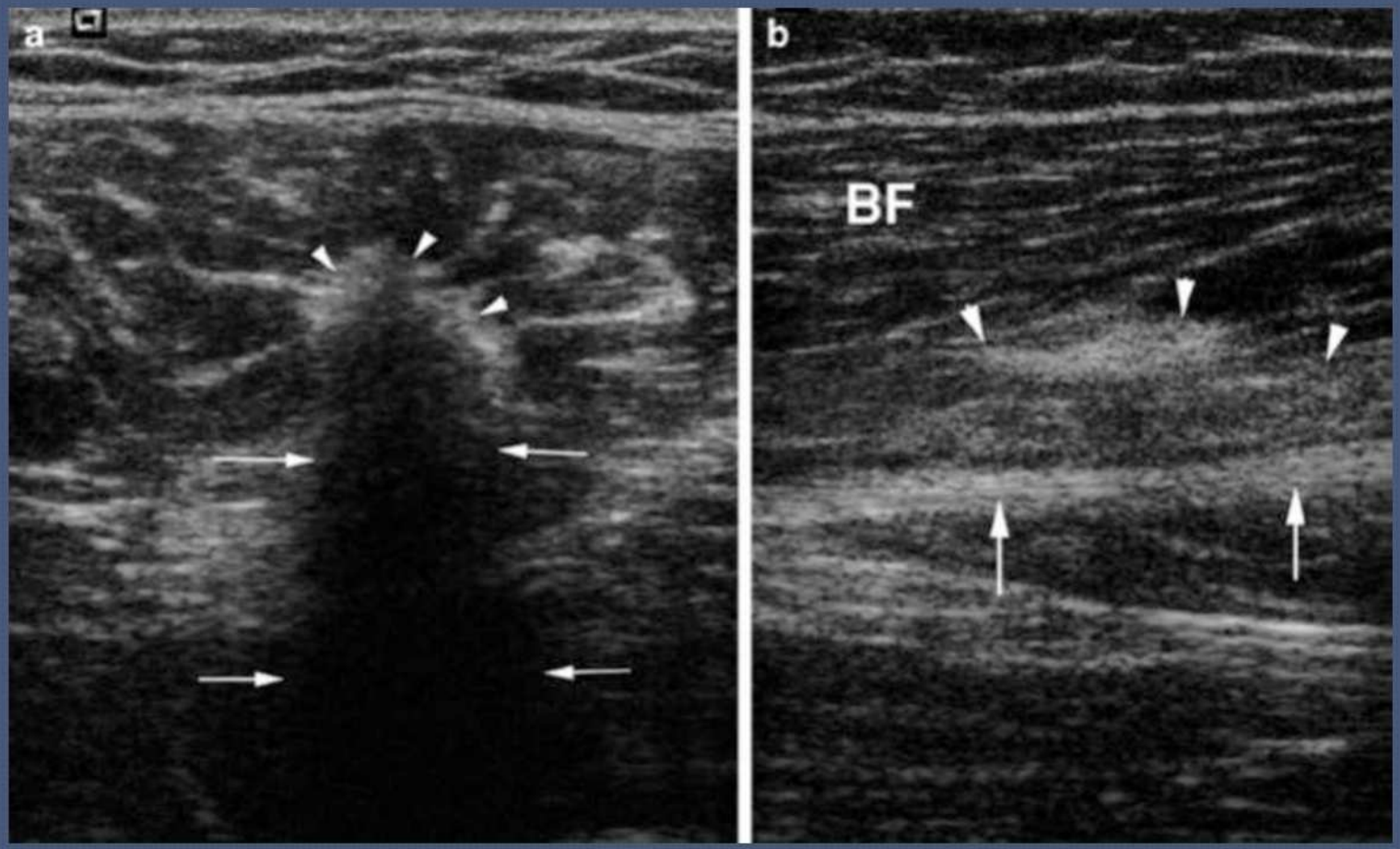

Datir and Connell, 2010

Myositis ossificans

- Heterotoopne ossifikatsioon
  - Posttraumaatiline (75%)
  - Mitte-traumaatiline/pseudomaliigne MO
  - *Myositis ossificans progressiva*
- Trauma raskus tõstab MO tekke tõenäosust
- Valulik, palpeeritav mass, turse, funktsiooni kadu, naha erüteem
- 50%-l trauma anamnees puudub

Myositis ossificans

Table 9.5 Phasic evolution and MRI features of myositis ossificans

Stage	Lesion characteristics	MRI features
Acute (<2 weeks)	Central area of haemorrhage, necrosis and proliferating fibroblasts surrounded by oedema	• Muscle enlargement and oedema • Isointense on T1W • Hyperintense on T2W/STIR with mass effect
Subacute (2–8 weeks)	Immature osteoid at the periphery with central cystic degeneration	• Best seen on T2W – ring-like pattern of low SI with central hyperintensity • Fluid–fluid levels and adjacent periostitis • Post-contrast rim-enhancement
Chronic (>8 weeks)	Mature bone pattern	• Peripheral hypointensity representing cortical bone • Mixed central SI with fatty changes representing mature trabecular bone

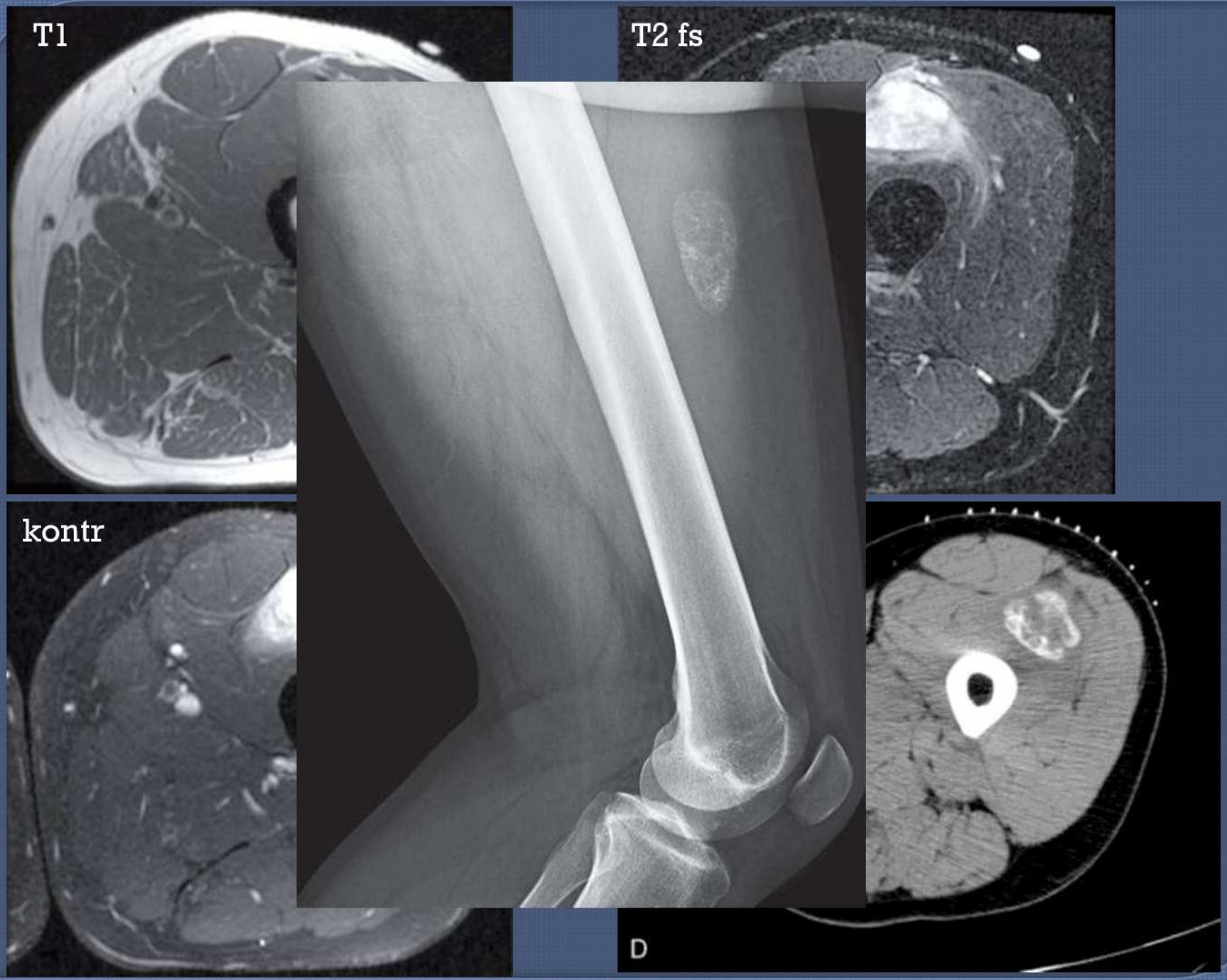
T1
T2 fs
kontr
D

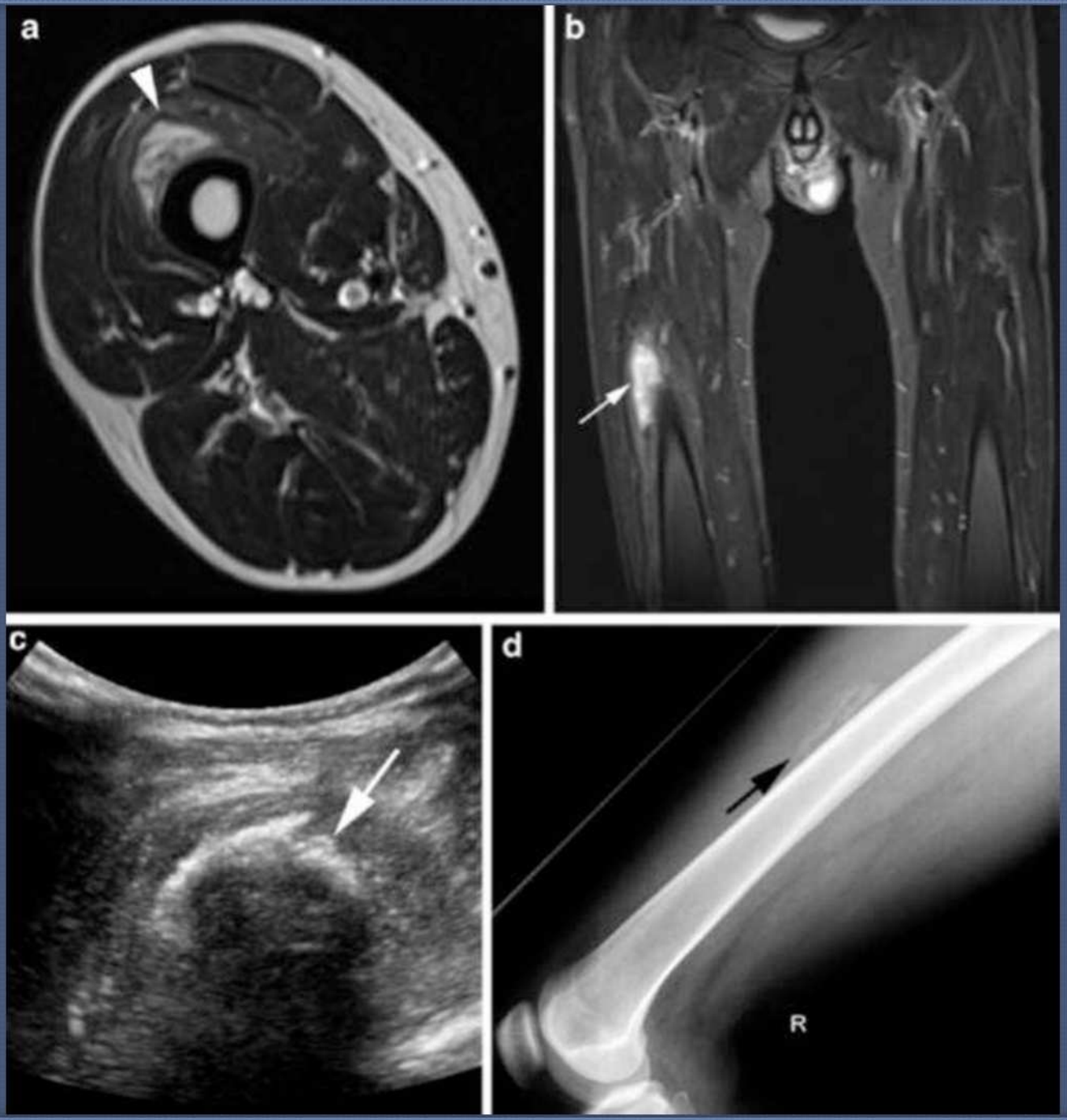
a
b
c
d
R

Myositis ossificans progressiva

Mittetraumaatiline / pseudomaliigne MO

Lihasatroofia

- peale rasket lihasvigastust (täielik ruptuur, innervatsioonihäire, mitte kasutamine).
- Tuleks hinnata teise poolega võrdlevalt, NB! osad kasutavad eri keha pooli erinevas määras
- lihase massi vähenemine (varases faasis lihashüpertroofia), rasvasendus algab lihasesisese aponeuroosi ja lihas-kõõlusülemineku piirkonnast

Denervatsioon

- akuutne (alla 2 nädala)
  - MRT võib olla normaalne
- 1-12 kuud
  - T2 tõus ekstratsellulaarne turse
- üle 12 kuu
  - rasv infiltratsioon, T1 tõus

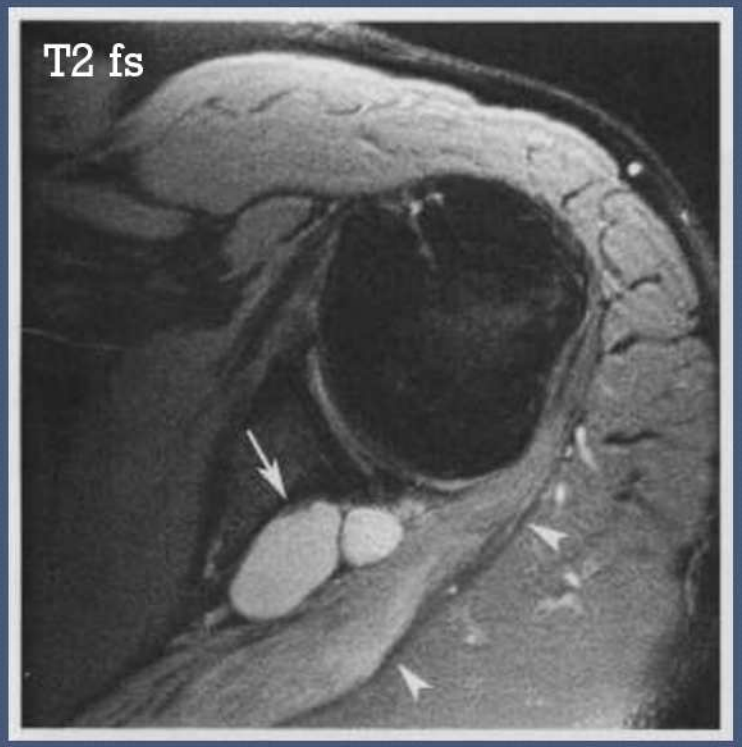
T2 fs

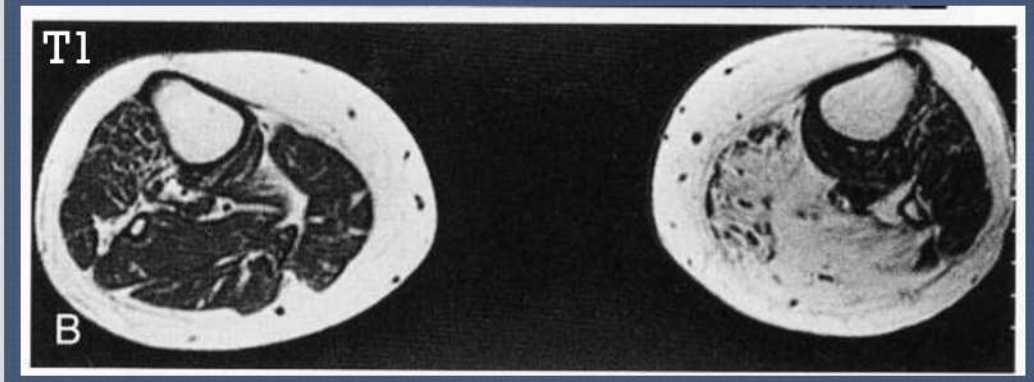
T1
B

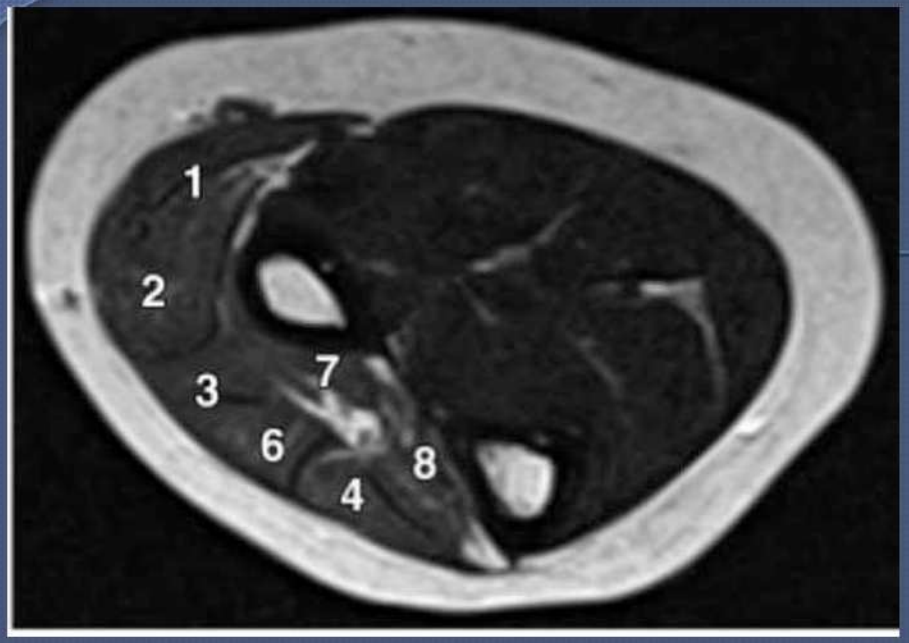
1
2
3
7
6
8
4

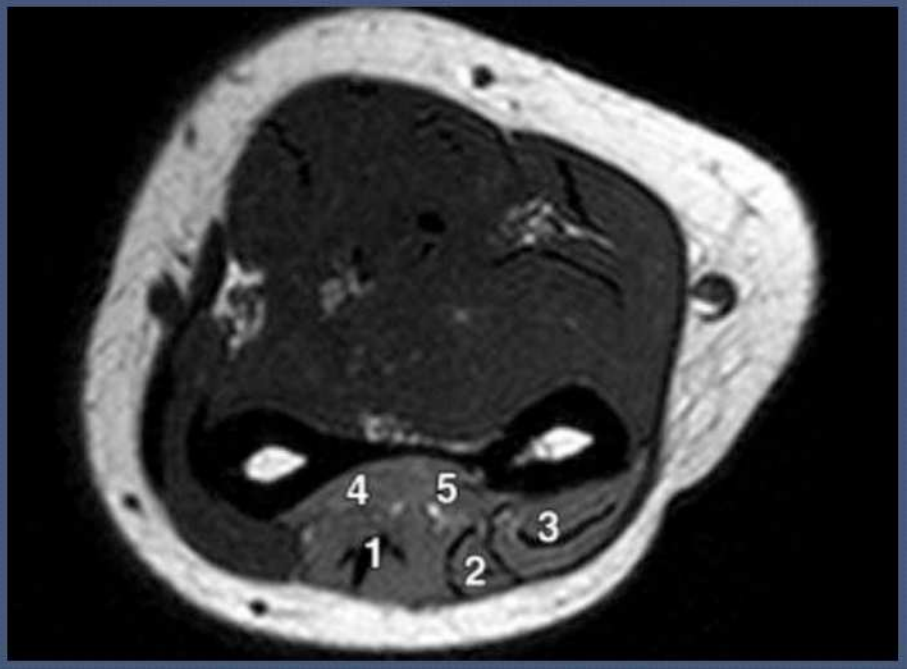
4
5
3
1
2

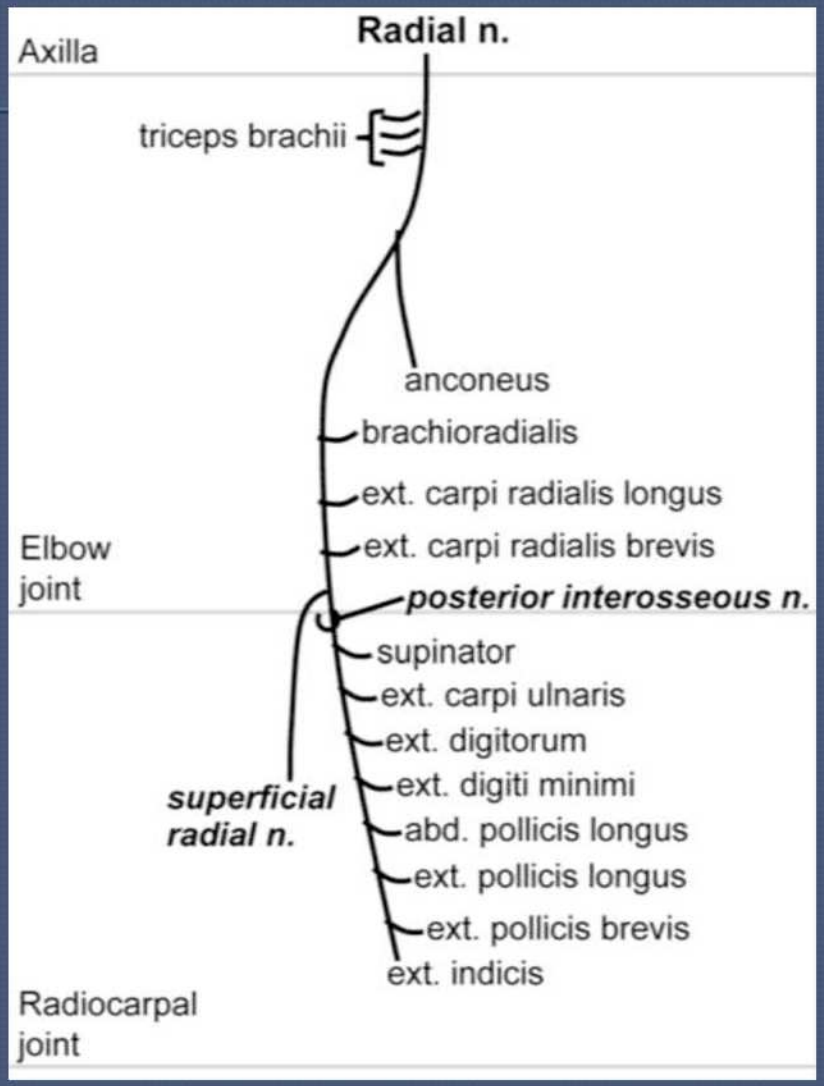
Axilla
Radial n.
triceps brachii
anconeus
brachioradialis
ext. carpi radialis longus
ext. carpi radialis brevis
Elbow joint
posterior interosseous n.
supinator
ext. carpi ulnaris
ext. digitorum
ext. digiti minimi
superficial radial n.
abd. pollicis longus
ext. pollicis longus
ext. pollicis brevis
ext. indicis
Radiocarpal joint

Kim 2011

Atroofiline lihas UH-s

M. vastus lateralis

M. vastus intermedius

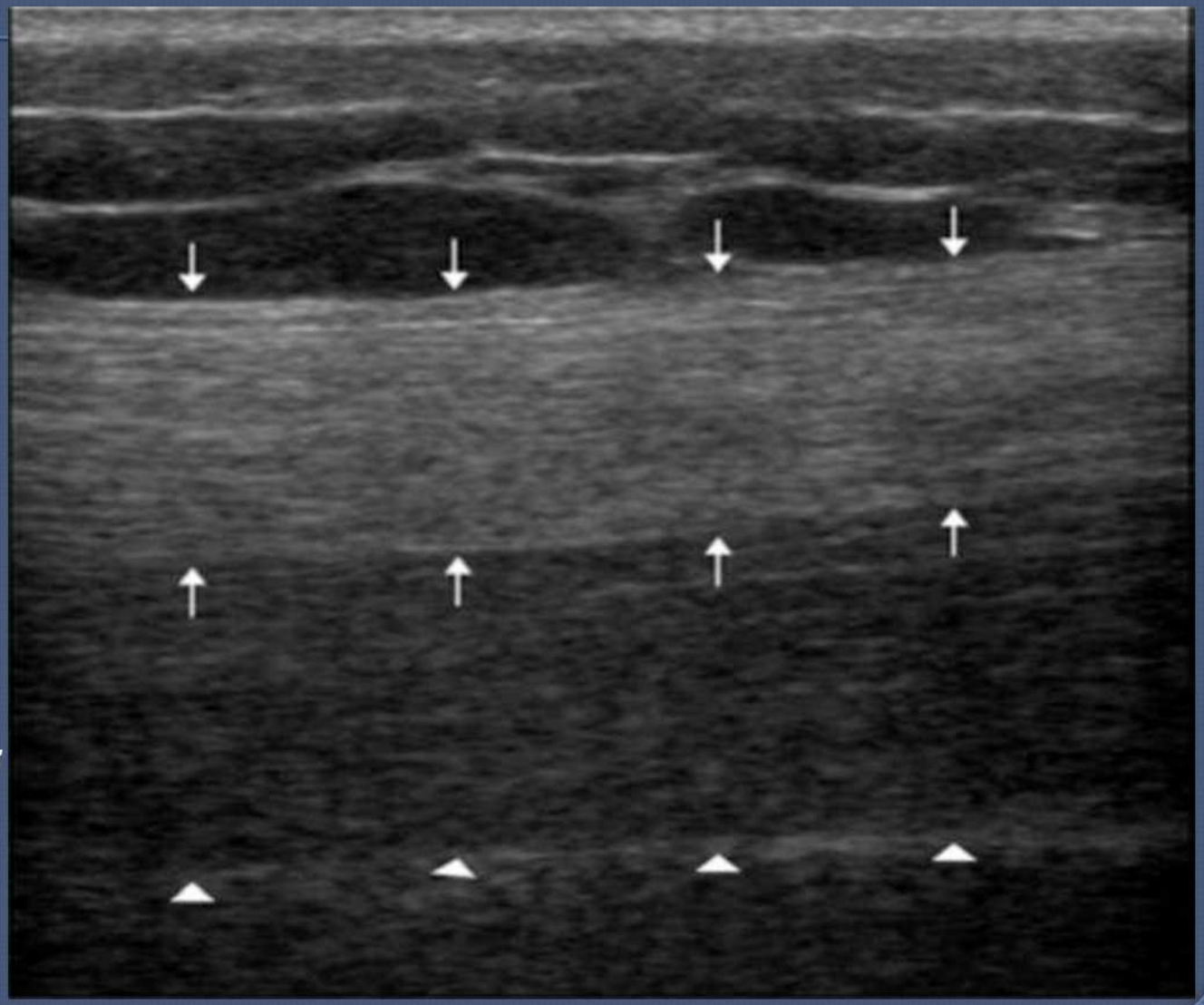

Varia muudest lihaskahjustustest

Kompartmentsündroom

- Akuutne
  - rõhutõus lihastes, mis fastsiaga piiratud, tavaliselt ekstensiivsest tursest / hematoomist;
  - (kapillaarse) perfusiooni langus, hüpoksia – kahjustus süveneb – turse laieneb – lihasnekroos
  - rhabdomüolüüs, neerude puudulikkus, surm
  - ravi kiire dekompressioon fastsiotoomia abil
  - ei ole radioloogiline diagnoos
  - sagedasim sääreluumurru järgselt
- Krooniline
  - CECS (*chronic exertional compartment syndrome*)
  - ebaselge geneesiga

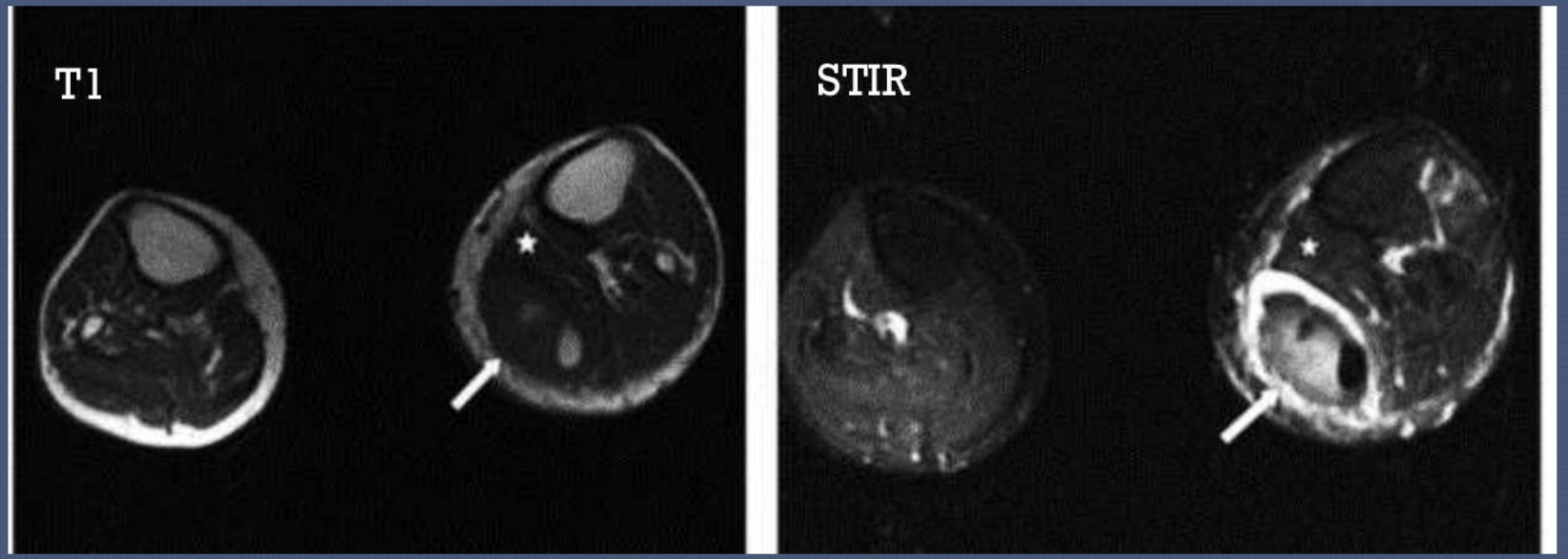
T1
STIR

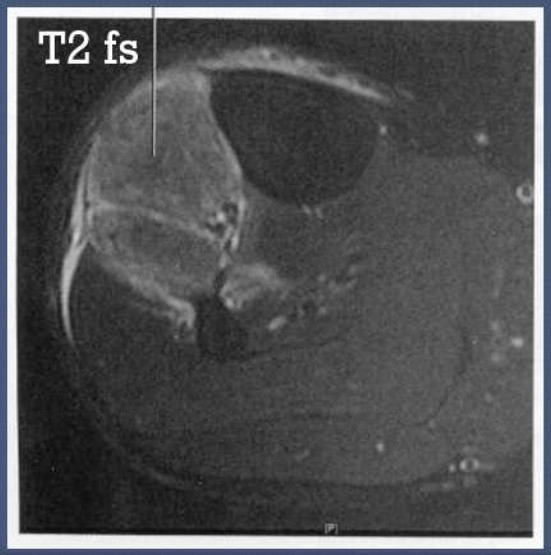
T2 fs

Rhabdomüolüüs

- nekroosi järgselt müoglobiin vereringesse – omandatud neerupuudulikkus, hüperkaleemia, DIC
- trauma (*crush injury*), infektsioon, põletik, peale ekstreemset füüsilist pingutust, alkoholi/ravimite üledoos jne.

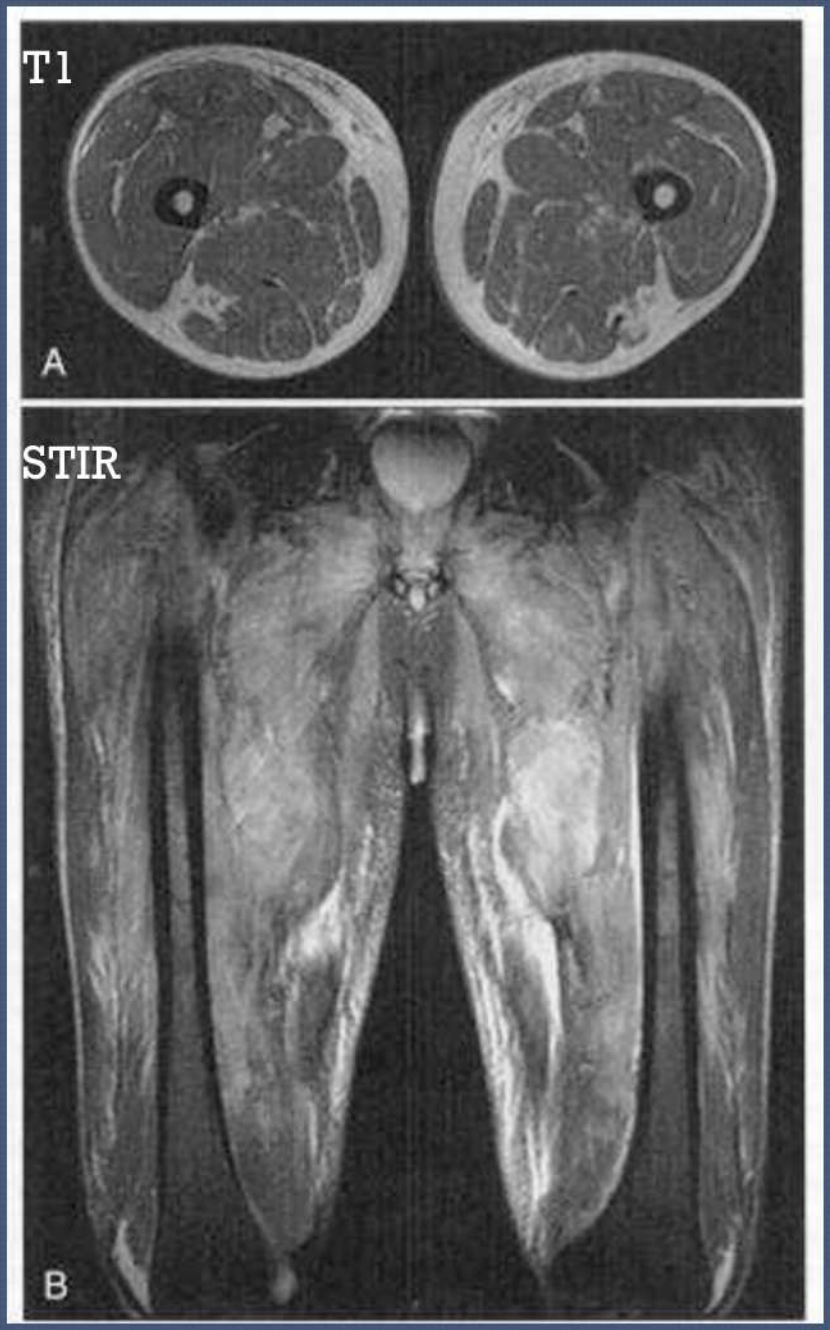
T1
A
STIR
B

Diabeetiline lihasinfarkt

T1

STIR

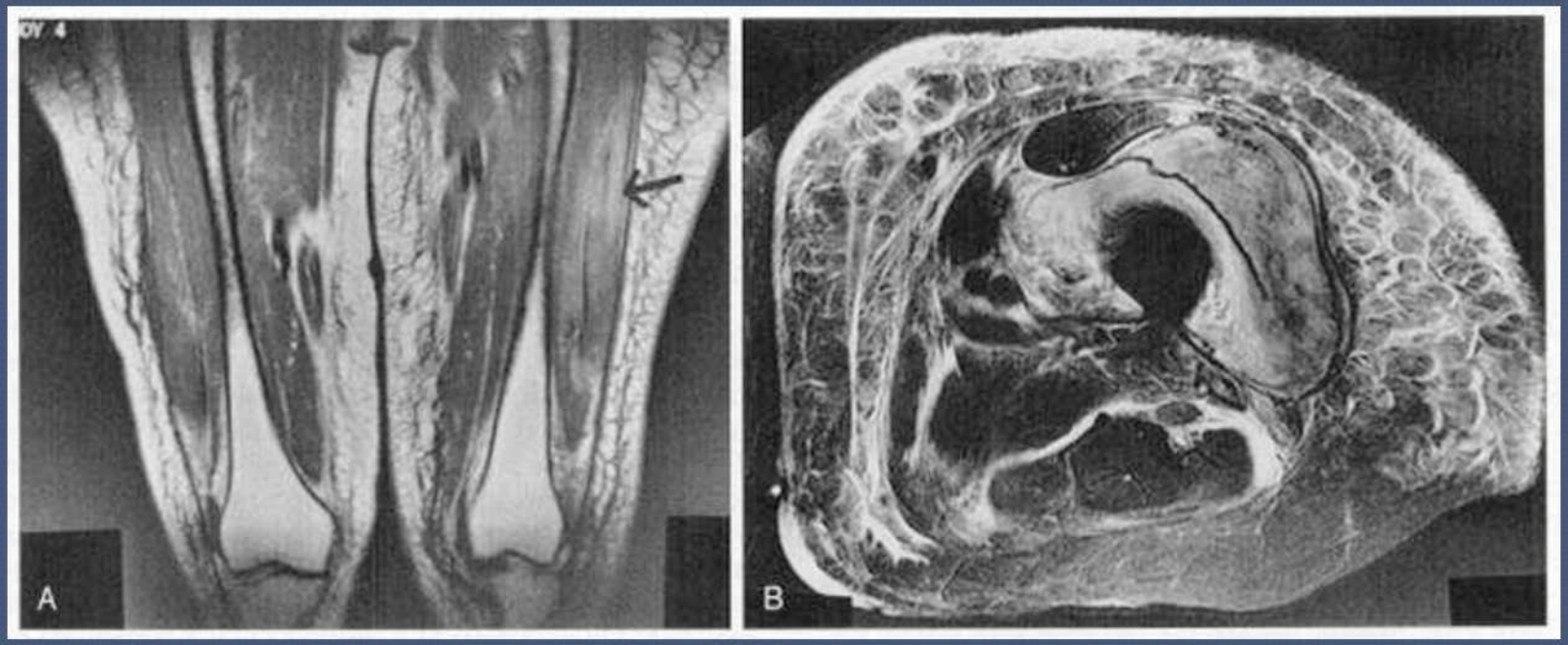

Põletikulised müopaatiad

- infektsioossed / mitteinfektsioossed
- püomüosiit – meil harv, peamiselt immuunpuudulikkusega seotud, hematogeenne levik või penetreeriv vigastus
- nekrotiseeriv fastsiit – lihastevaheliste fastsiate haaratus, kõrge mortaalsus, kliiniliselt raske vahel tselluliidist eristada, tavaliselt grupp A hemolüütiline streptokokk või *S. aureus*
- autoimmuunsed? idiopaatilised põletikulised müopaatiad – polümüosiit, dermatomüosiit, inklusioon keha müosiit
- sarkoidoos

Püomüosiit

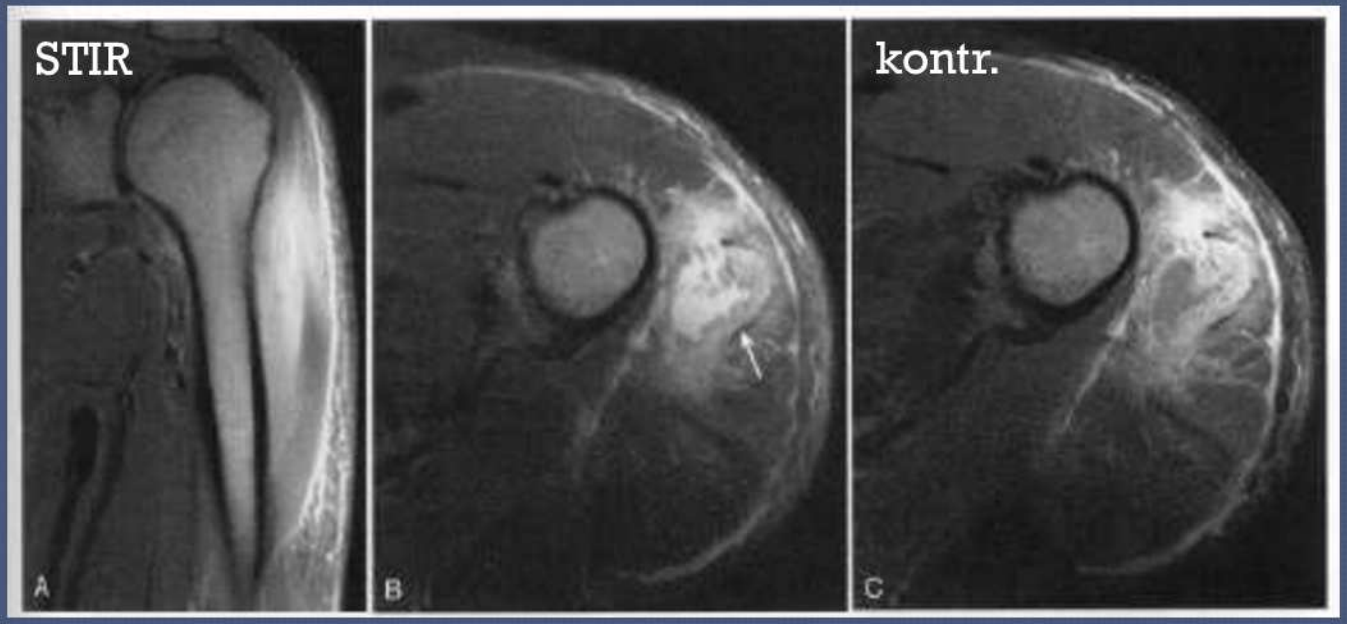

Nekrotiseeriv fastsiit

STIR

Tselluliit

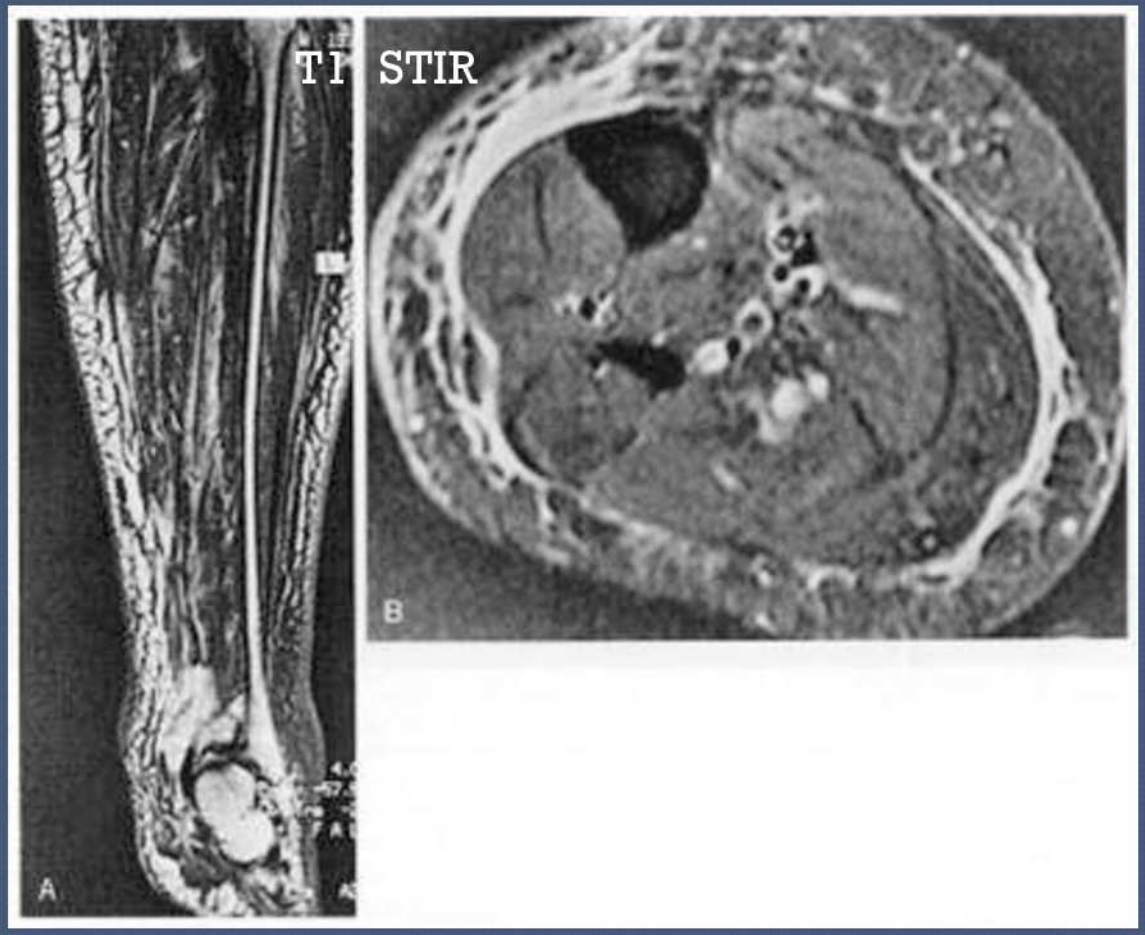

NB! Eosinofiilne fastsiit

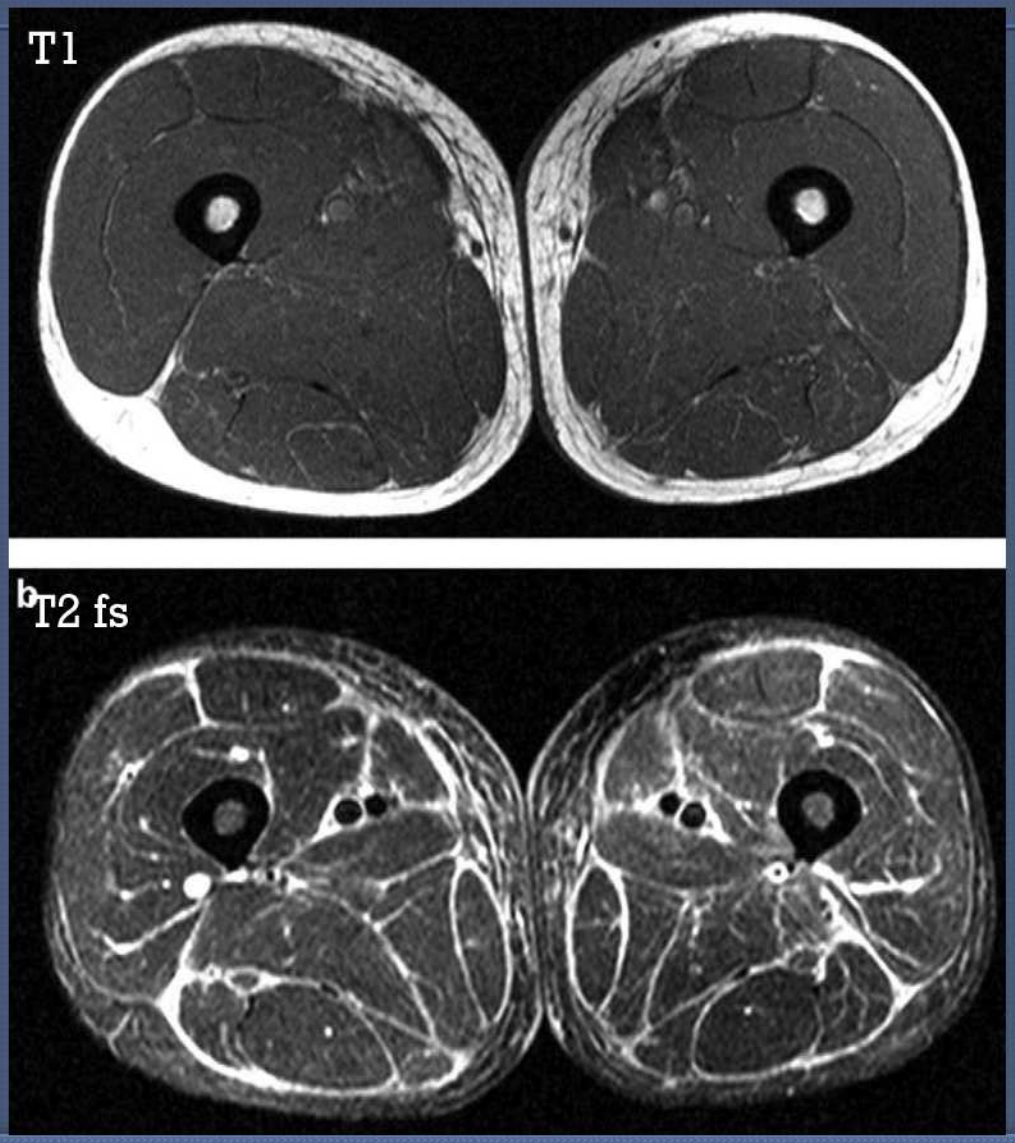

Polümüosiit

STIR

Dermatomüosiit

Kiiritusjärgsed muutused

- Sageli piiritletud difuusne intramuskulaarne ja subkutaanne T2 signaalitõus

STIR

Lihaskasvajad

- 98% maliigsed rhabdomüosarkoomid, alla 2 % rhabdomüoomid
- sagedasim pahaloomuline pehmekoe kasvaja lapseeas (5-8%) ja alla 1% täiskasvanu maliigsetest kasvajatest
- Histoloogiliselt kolm tüüpi
  - embrüonaalne – levinuim vorm, enam lastel, 12% täiskasvanutel, 47% pea-kaela piirkonnas, 28% urotraktiga seotult, 6% jäsemete lihastes, sõltuvalt rakutüüpidest erinev prognoos
  - alveolaarne – enam noorukitel, jäsemetel, halvema prognoosiga
  - pleomorfne – üle 45 aastastel, halva prognoosiga
  - skleroseeruv rms.

Davies 2010

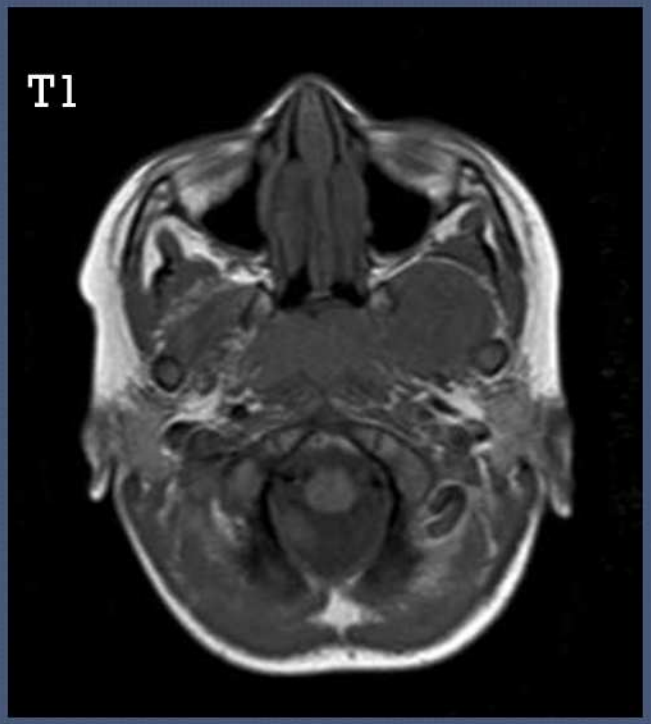

Dr. R. Saat

Embrüonaalne rms.

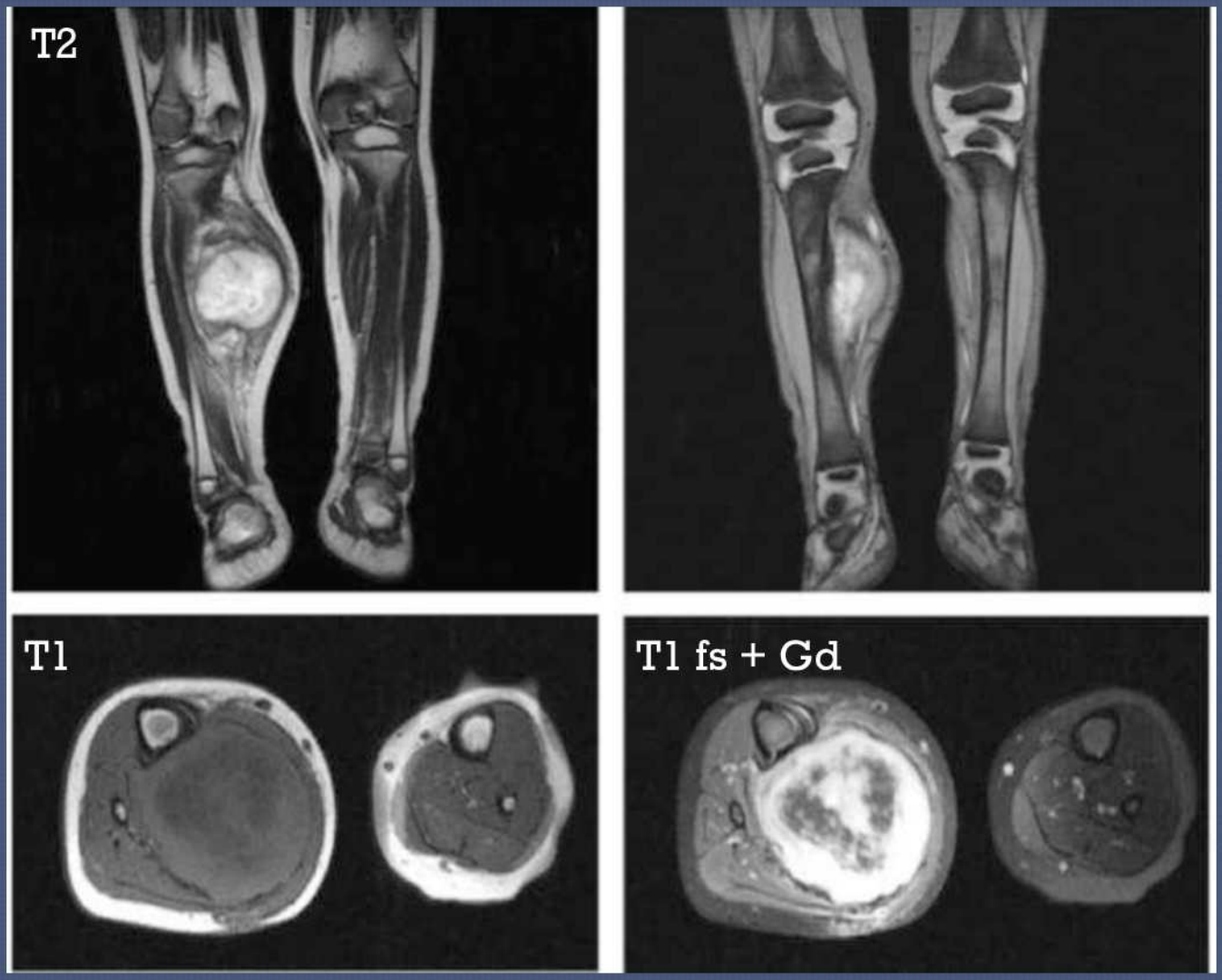

Alveolaarne rms.

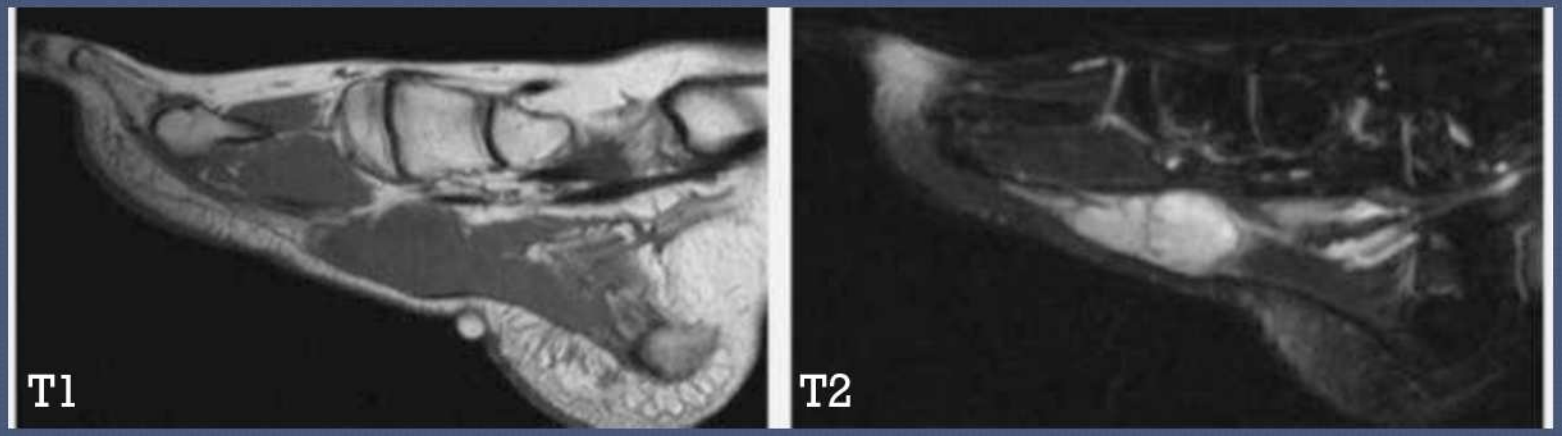

Kasvajad

- Reeglina üsna ebaspetsiifiline leid: T2↑, varieeruv kontrasteerumine. Sageli vajab biopsiat, kuvamine hea lokaliseerimiseks

Lesion	Discriminators
Hemangioma	Contains fat
Lipoma	Is fat
Myxoma	Many cyst characteristics
Sarcoma	No surrounding edema
Metastases	Often surrounding edema
Lymphoma	Infiltrates entire muscle
Neurofibroma	Target sign possible; resembles myxoma, but diffuse enhancement

Hemangioom, lipoom

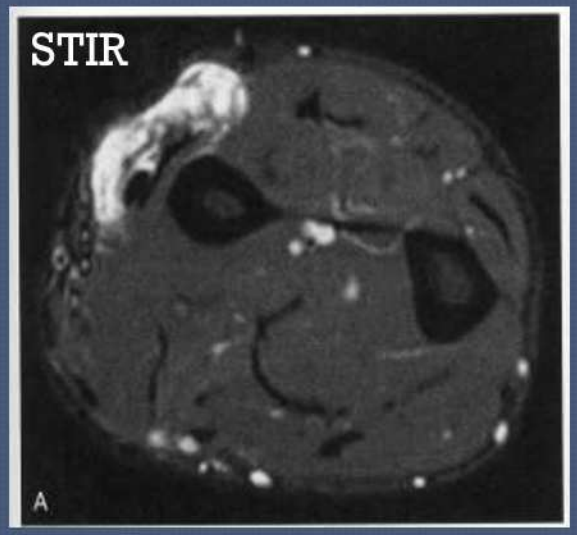

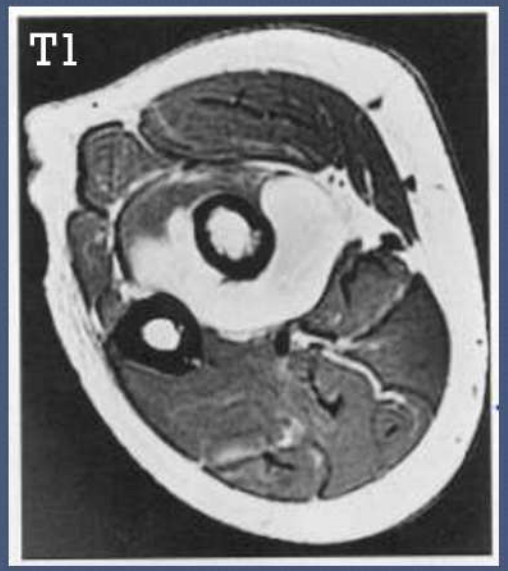

Helms 2009

Metastaasid

Kusepõie transitoor-rakulise vähi mts

Melanoomi mts

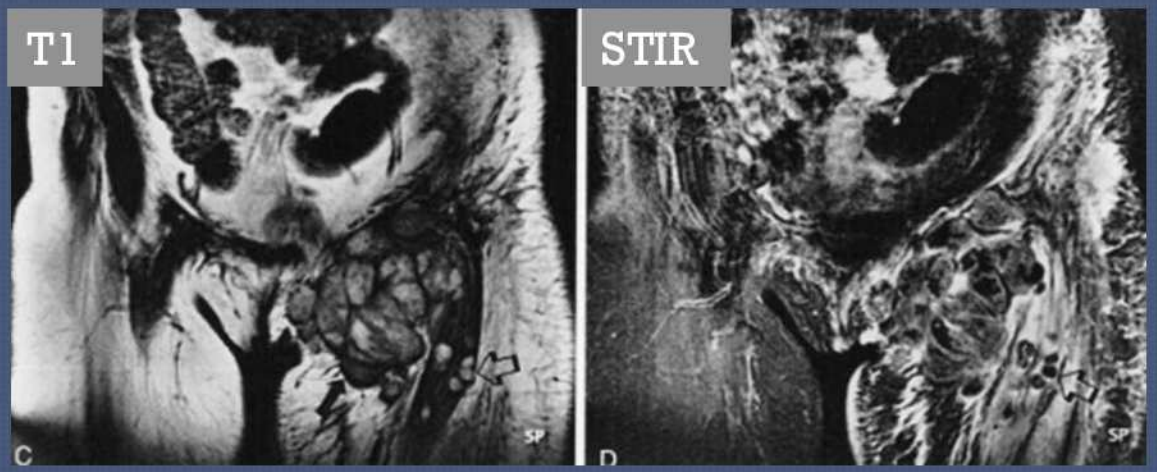

Helms 2009

Kokkuvõte

- MRT ja UH
- Paljud pildilised muutused mittespetsiifilised, oluline anamnees

- 4 aspekti mida jälgida:
  - jaotus
  - lihase suurus ja kuju
  - muutunud T1 signaal
  - muutunud T2 signaal
  - (kontrasteerumine)

INVITED REVIEW

MAGNETIC RESONANCE IMAGING OF MUSCLE DISEASE: A PATTERN-BASED APPROACH

ANDREU F. COSTA, MD, MSc,[1] GINA A. DI PRIMIO, MD, FRCPC,[1,2] and MARK E. SCHWEITZER, MD[1,2]

[1]Department of Medical Imaging, Ottawa Hospital, General Campus, 501 Smyth Road, Ottawa, Ontario K1H 8L6, Canada
[2]Department of Radiology, Faculty of Medicine, University of Ottawa, Ottawa, Ontario, Canada

Accepted 25 February 2012

ABSTRACT: Magnetic resonance imaging (MRI) is a powerful tool to assess the severity, distribution, and progression of muscle injury and disease. However, a muscle's response to a pathological insult is limited to only a few patterns on MRI, and findings can be nonspecific. A pattern-based approach is therefore essential to correctly interpret MR studies of abnormal muscle. In this article we review the anatomy, function, and normal MRI appearance of skeletal muscle. We present a classification scheme that categorizes abnormal MR appearances of muscle into 4 main pattern descriptors: (1) distribution; (2) change in size and shape; (3) T1 signal; and (4) T2 signal. Each category is further subdivided into the various patterns seen on MRI. Such an approach allows one to systematically assess abnormal findings on muscle MRI studies and ascertain clues to the diagnosis or differential diagnosis, particularly when findings are correlated with the clinical context.

Muscle Nerve 46: 465–481, 2012

and metabolic properties, as determined by their motor neuron.[1] Muscle fibers are broadly categorized as type I ("slow twitch") and type II ("fast twitch"). Type II fibers are further subdivided into types IIA, IIX, and IIC. Typically, 50% of skeletal muscle fibers in humans are type I, 25% type IIA, 25% type IIX, and a small proportion (1–2%) type IIC.[1] However, this proportion varies based on the function of the muscle, hereditary factors, and activity level.[2–4]

Type I fibers are slower to contract (~110 ms) and are more resistant to fatigue.[1] These fibers are used for lower intensity, extended activities; for example, up to 70% of skeletal muscle fibers in marathoners may be type I. In comparison to fast-

Mirror NEWS
Real news, real entertainment . . . in real

By Andrew Gregory | Comments | 29 Jul 2013 08:01

Manchester United stars get MRI and CT scanners worth millions at training grounds as Tory cuts hammer NHS

Yet Tory health chief Jeremy Hunt has announced he will close the local A&E unit at Trafford General Hospital just three miles away

Manchester United's Aon Training Complex and Trafford General Hospital

Manchester United/PA

Kasutatud kirjandus

- Tiitellehe pilt - Juan Valverde de Amusco *Anatomia del corpo humano*
- Campbell RSD, Dunn AJ: Radiological Interventions for soft tissue injuries in sport. *The British Journal of Radiology*, 85:1186, 2012
- Costa AF *et al* Magnetic resonance imaging of muscle disease: a pattern-based approach. *Muscle & Nerve* 46: 465, 2012
- Datir A, Connell DA. Muscle Injury and Complications. In: Robinson P. Essential Radiology for Sports Medicine. Springer, 2010.
- Davies CE *et al*. Soft Tissue Tumors with Muscle Differentiation. *Semin Musculoskelet Radiol* 14:245, 2010
- Fleckenstein JL *et al*: Acute effects of exercise on MR imaging of skeletal muscle in normal volunteers. *AJR* 151:213, 1988
- Helms CA *et al*. Musculoskeletal MRI. Saunders, 2009
- Kim SJ *et al*. MR Imaging mapping of Skeletal Muscle Denervation in Entrapment and Compressive neuropathies. *Radiographics* 31:319, 2011
- Lawrimore T *et al*. Traumatic Muscle Injuries. *in* Imaging of Arthritis and Metabolic Bone Disease. Mosby, 2009.
- Morrison WB & Sanders TG. Problem Solving in Musculoskeletal Imaging. Mosby, 2008.
- Orchard JW, Farhart P, Leopold C. Lumbar spine region pathology and hamstring and calf injuries in athletes: is there a connection? *Br J Sports Med* 38:502, 2004
- Ross MH, Pawlina W. Histology: A Text and Atlas. 6ed. LWW, 2010
- Schleip R *et al*. What is 'fascia'? A review of different nomenclatures. *Journal of Bodywork & Movement Therapies*, 16: 496, 2012
- Tyler P *et al*. The Imaging of Myositis Ossificans. *Semin Musculoskeletal radiol*. 14:201, 2010
- Woodhouse JB, McNally EG: Ultrasound of Skeletal Muscle Injury: An Update. *Semin Ultrasound CT MRI* 32:91, 2011

Tänan tähelepanu eest!