Tallinna Kolmapäevaseminarid 2006

Mammogramm – kas vaid arusaamatu “tähistaevas”?

Sulev Ulp

SA TÜ Kliinikum

radioloogiateenistus

Tähistaevas

Tähistaevas

Mammogramm



“Tähistaevast” uurimas

Kvaliteetne mammogramm

- Positsioneerimine
- Aparatuur
- Kassetid – filmid
- Ilmutusprotsess
- Vaatlustingimused
- Digitaalne mammograafia

Üks rind – erinevad aparaadid

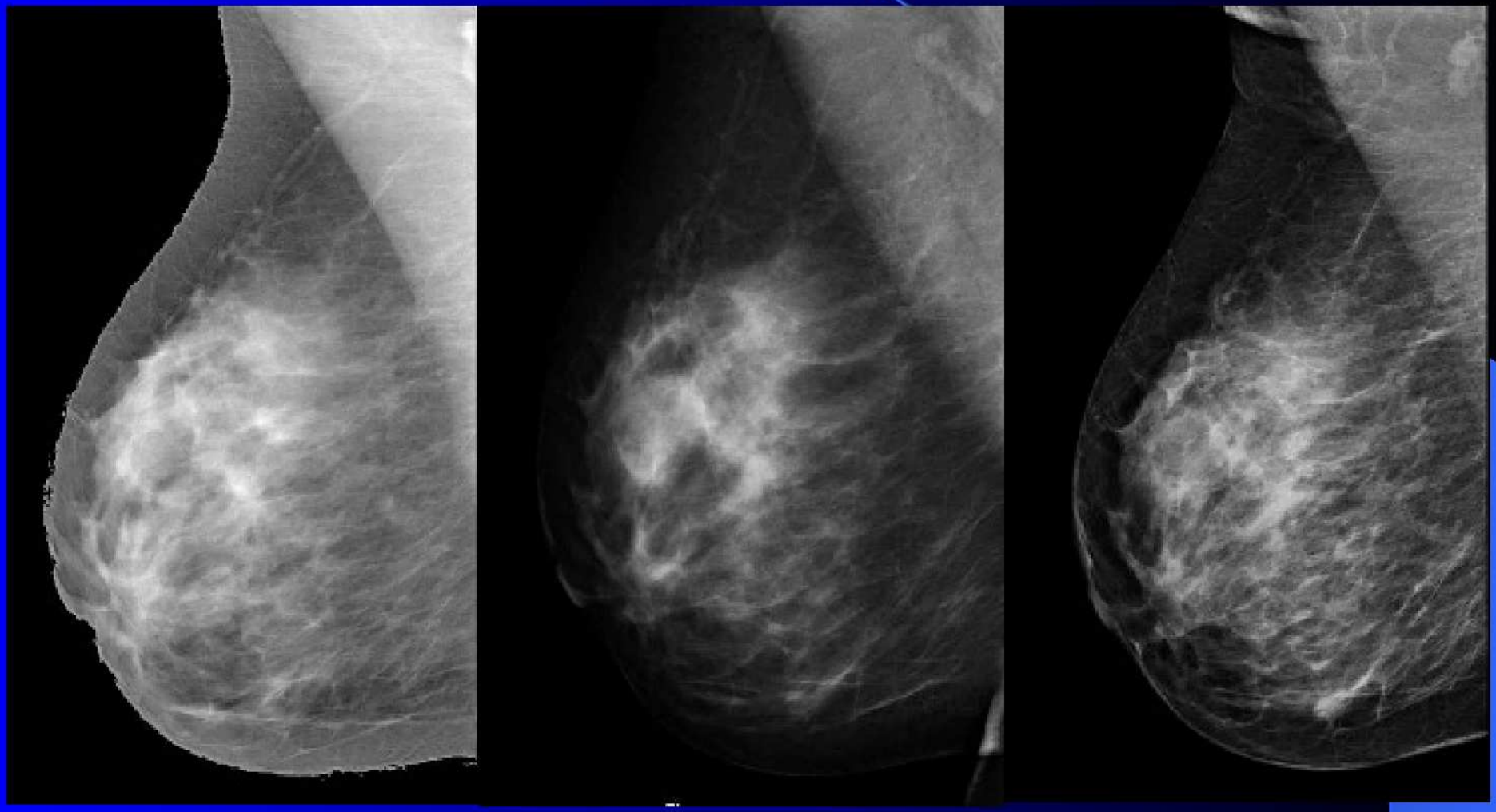

“Issanda loomaaed” on rikkalik…

Rinna perimeeter

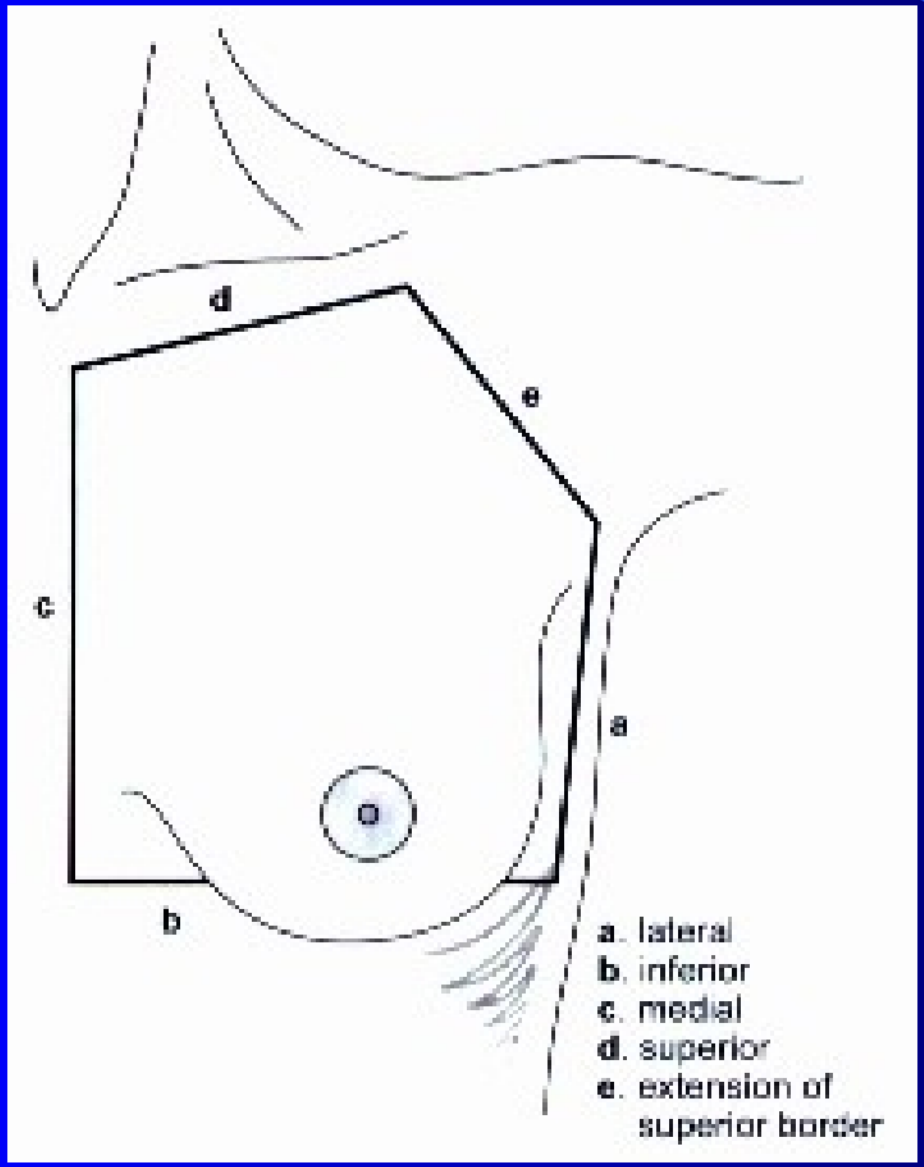

- a. – axilla → RAV
- b. – RAV → sternum
- g. – sternum → SKL
- d. – SKL → õlavarreluu pähik
- e. – õlavarreluu pähik → aksilla

Põhiprojektsioonide kvaliteedikriteeriumid

Medio-lateraalne põikiprojektsioon :

- Maksimaalne osa **rinnast** on mammogrammil
- Rind on komprimeeritud **optimaalses** asendis (on piisavalt eemale tõmmatud rindkerest, **ei ripu!**) ja kompressioonplaadi serv on maksimaalselt rindkereseina **lähedal**
- Visualiseeritud on näärmekoetagune **rasvkude**
- Ü/v-l on rinnaalune **volt**
- Rinnanibu on **kontuuril**
- Rinnalihas visualiseerub **vastavuses** kvaliteedi kriteeriumitega

Rinnalihase kvaliteedi kriteeriumid

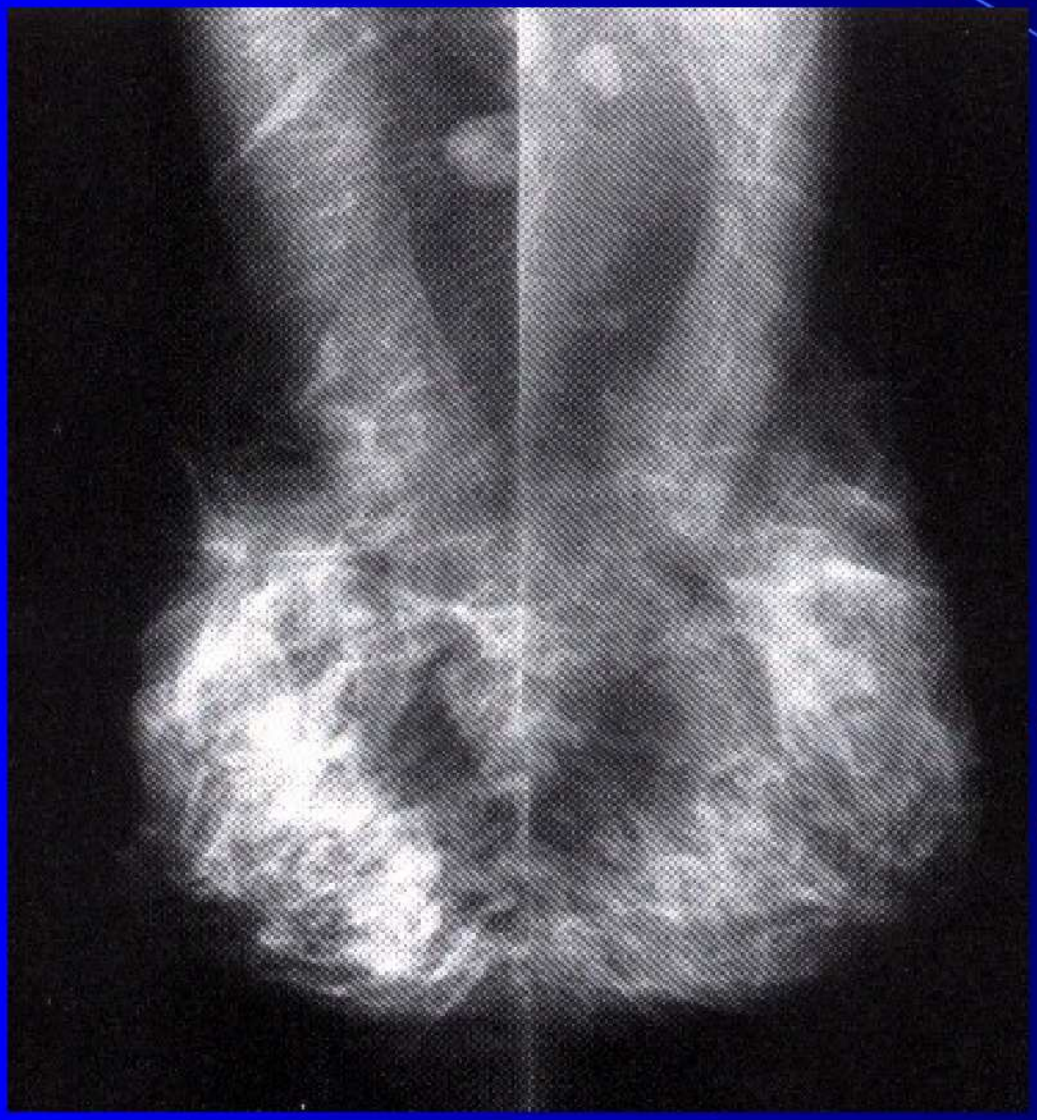

- Lihas kulgeb **sümmeetriliselt** aksillaarselt → nibutasapinnani
- Aksillaarosa on **lai**
- **Konveksne** kontuur
- Lihas on **transparentne**

Õige nurga valik (60* v. 40*)

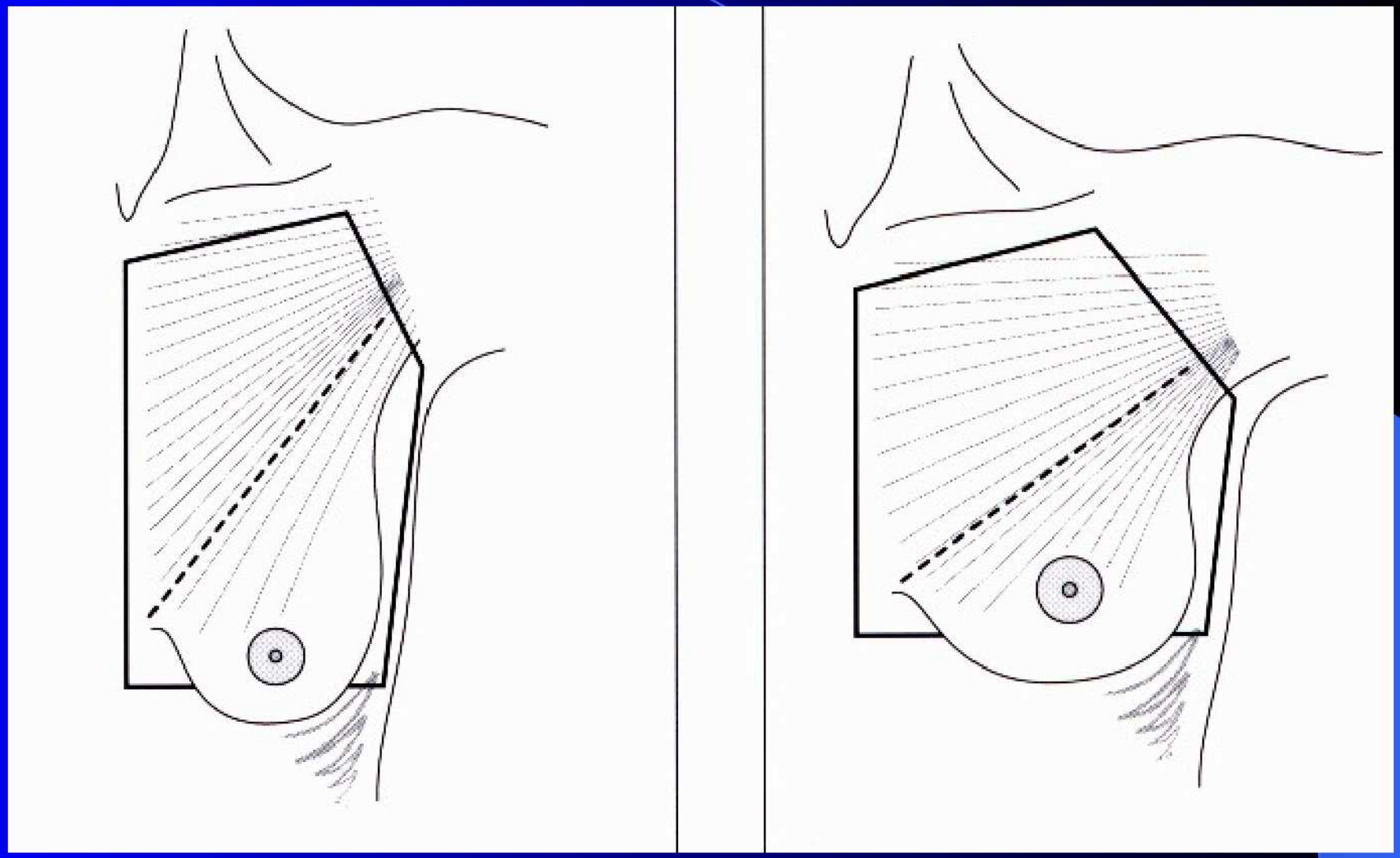

Nibu tasapind (MLO)

Põhiprojektsioonide kvaliteedikriteeriumid

Kraniokaudaalne projektsioon :

- Maksimaalselt peab olema visualiseeritud **rinnakudet**
- Rinna keskmise, subareolaarse ja mediaalse osa visualiseerimine optimaalse **kompressiooniga**
- Rinnalihas ilmestub ca **30%** juhtudest
- Nibutasapinna **joone pikkus** k/k ü/v-l tohib olla kuni **1 cm lühem** kui sama joon MLO ü/v-l
- Nibu peaks olema **kontuuril**
- Ilmestub näärmekoetagune **rasvkude**

Kranio-kaudaalne projektsioon

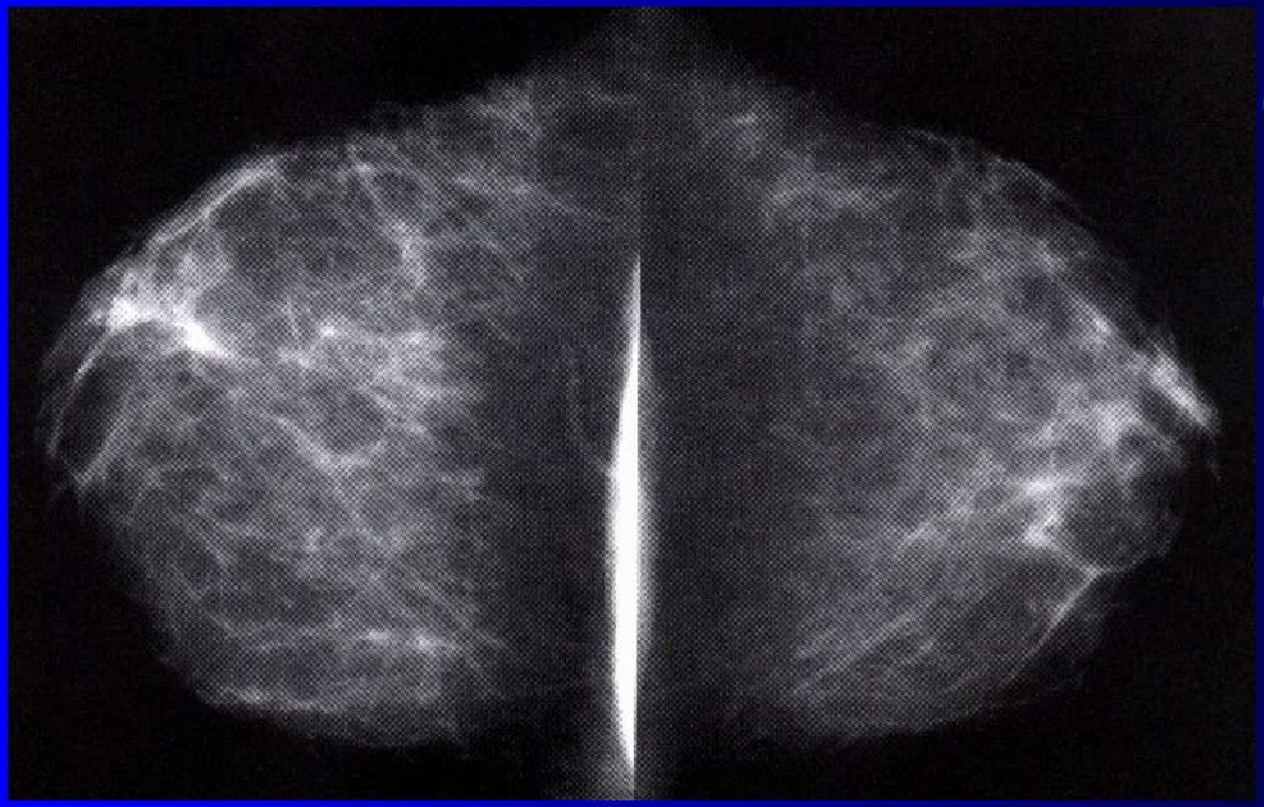

- Lihas ilmestub ca **30%** ü/v-tel
- Tavaliselt **tsentraalsel** või **mediaalsel**

Nibu tasapinna mõõdud

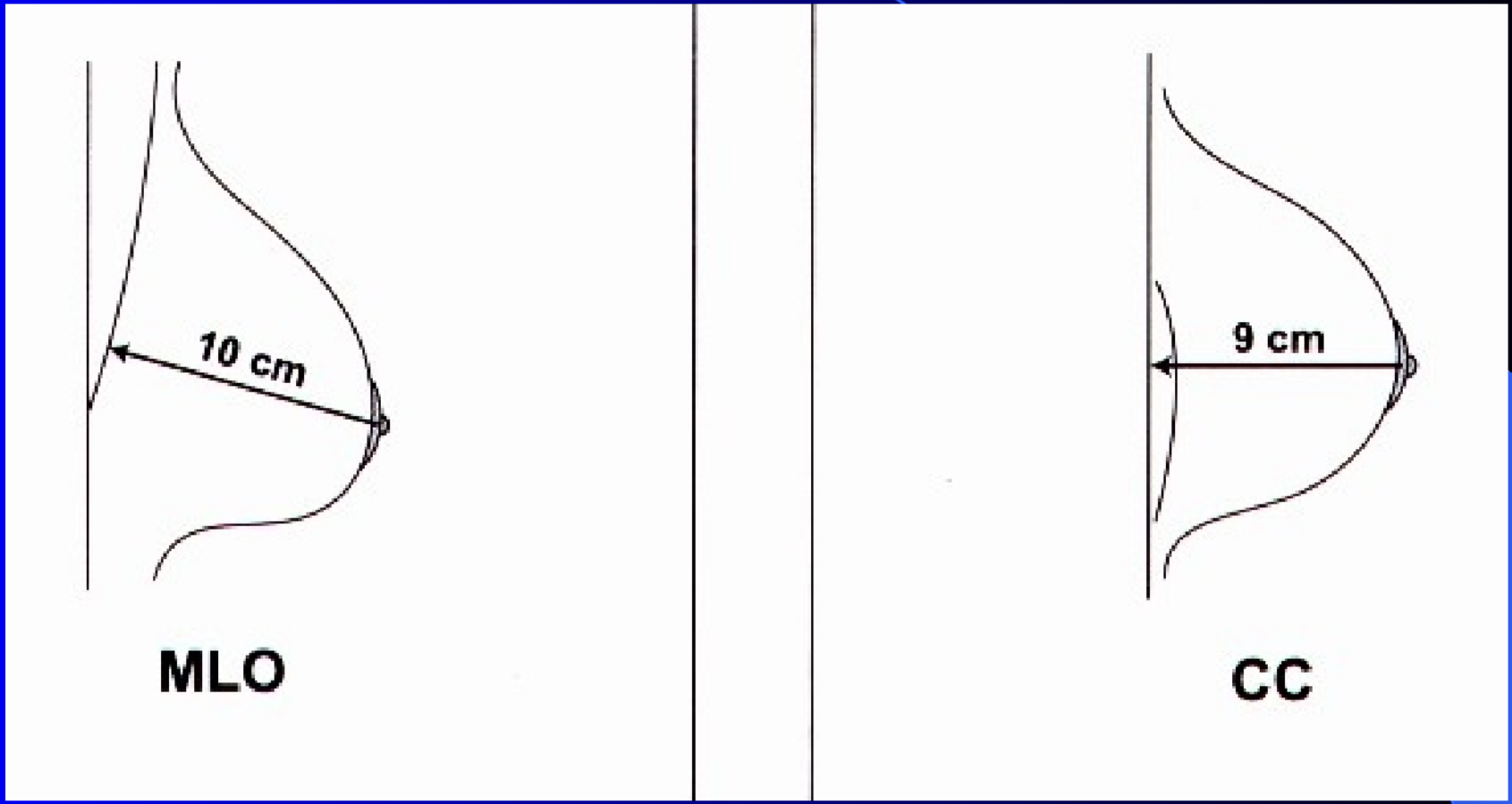

Tabari koolkond



Tabari “laboratoorium” Falunis

Mammogrammide lugemine

- Rindade areng ja normaalne **anatoomia**
- **Parenhüümi** tüübid ja **normi** variandid
- **Patoloogilised** muutused :
  - Mikrolubikolded
  - Ümar-ovaalsed lisavarjustused
  - Kiirjate jätketega ja asümmeetrilised varjustused
  - Infiltreeritud rinna sündroom

Rinnanäärmete areng

- Rinnanäärmed on arenguliselt muundunud apokriinsed **higinäärmed**, mis tekivad rudimentidena juba 2. raseduskuul
- Näärmeslised osad lähtuvad **rinnaväädist**, mis kulgeb lootel **aksillaarkoopast kubemeni**
- Pektoraalpiirkonnas rinnaväät pakseneb ja moodustab tulevase **rinnanäärme alge**
- Viimane invagineerub ja selles tekivad 15-20 **näärmepunga**, millest igast areneb hiljem rinnanäärme **sagar**
- Algselt soliidsed näärmepungad **kanaliseeruvad** 8. raseduskuul ja moodustuvad **piimajuhad**
- Tekivad sagartevahelised sidekoelised **septid**
- 5. raseduskuul tekib rinnanäärmes **rasvkude**
- Sünnimomendiks formeerub ka **areool** ja **rinnanibu**, milles avanevad piimajuhad

Rinna anatoomia

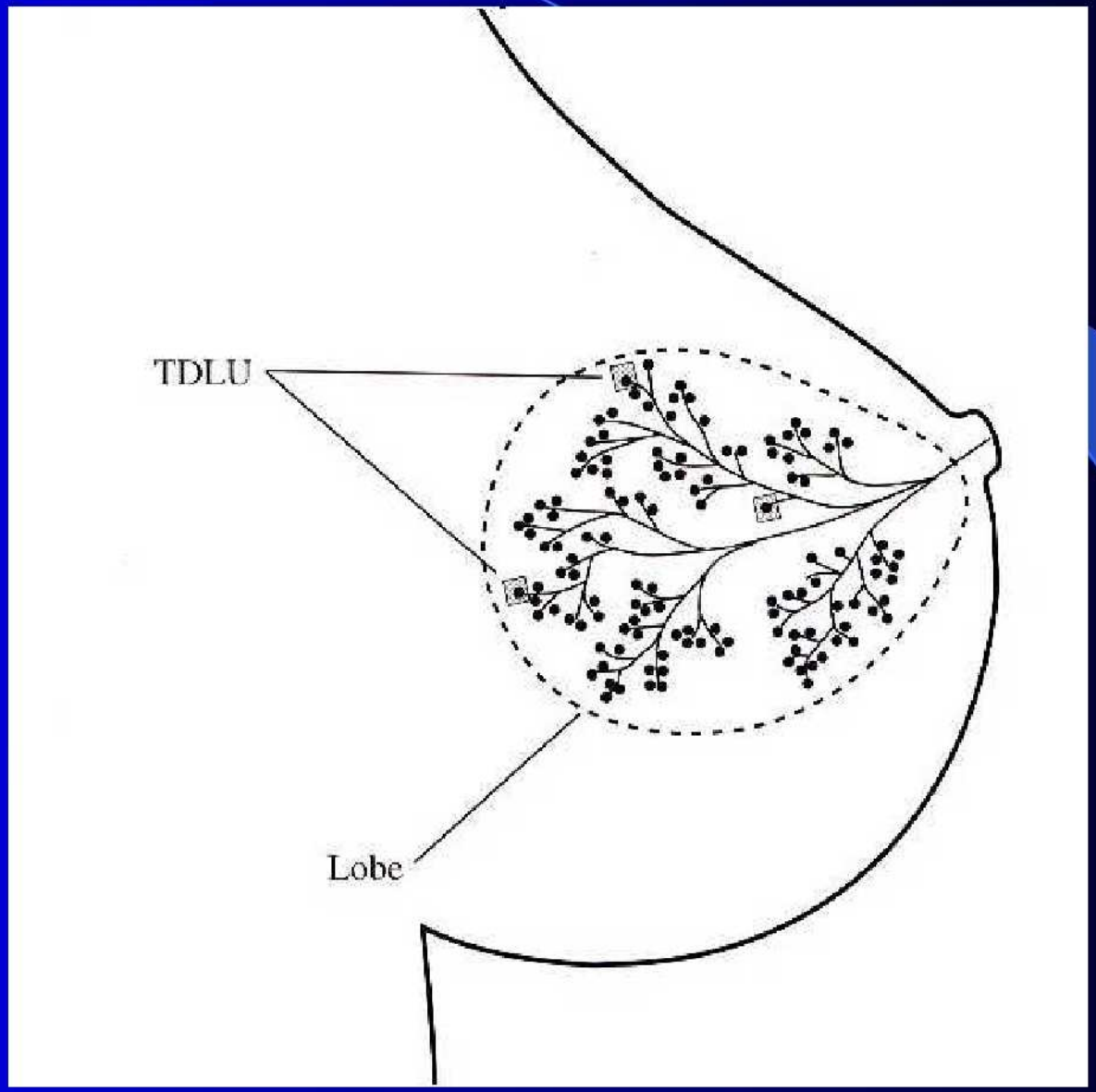

Terminaalne duktaal-lobulaarne üksus

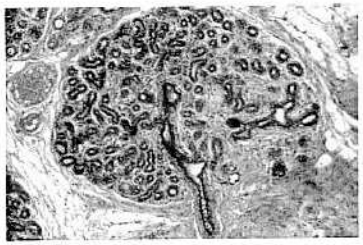

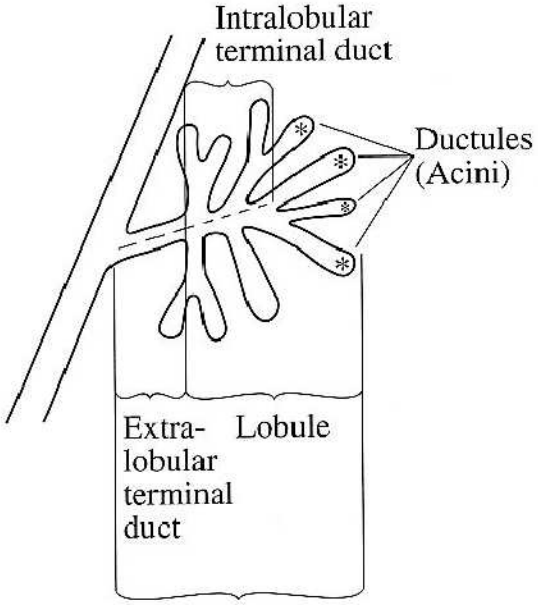

Terminal Ductal Lobular
Unit (TDLU)

I Parenhüümi tüüp - fibroglandulaarne rind

The three main features are:

1. Scalloped contours and Cooper's ligaments.
2. Evenly scattered TDLU-s, 1-2 mm nodular densities.
3. Oval-shaped lucent areas, corresponding to fatty replacement, giving a harmonic structure.

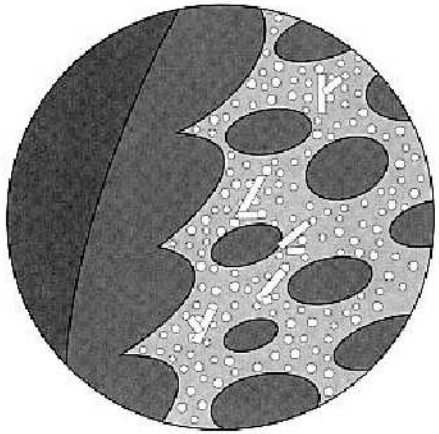

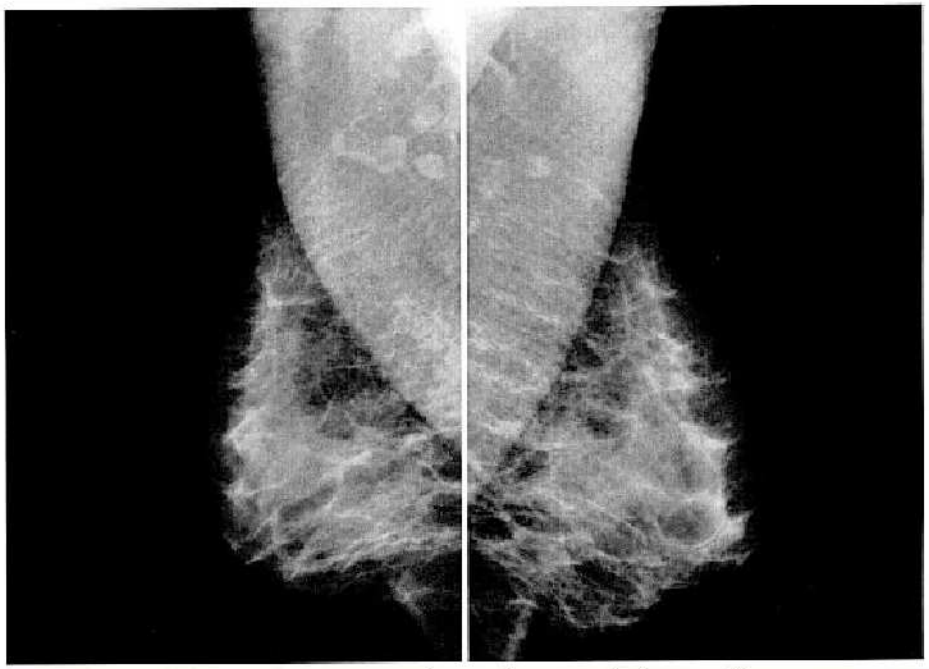

I tüübi variatsioon - **lisanäärmekude**

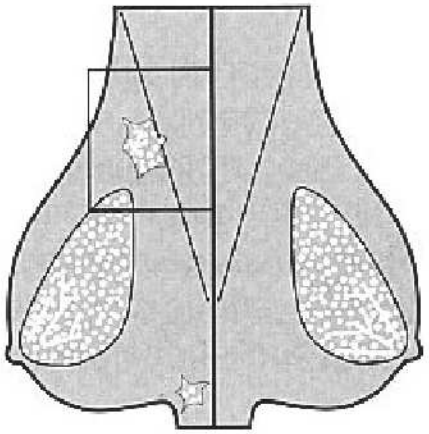

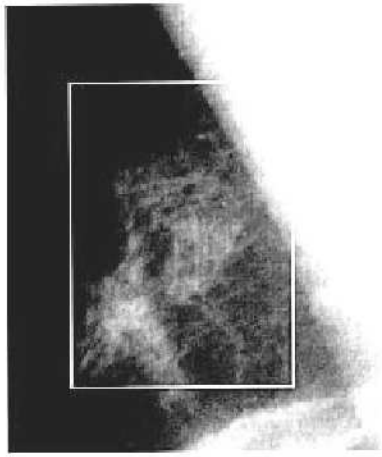

A.

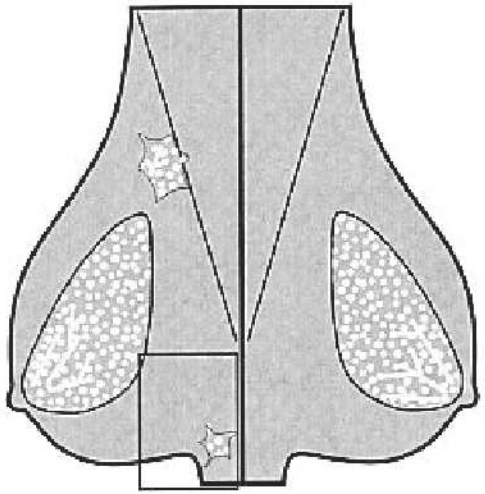

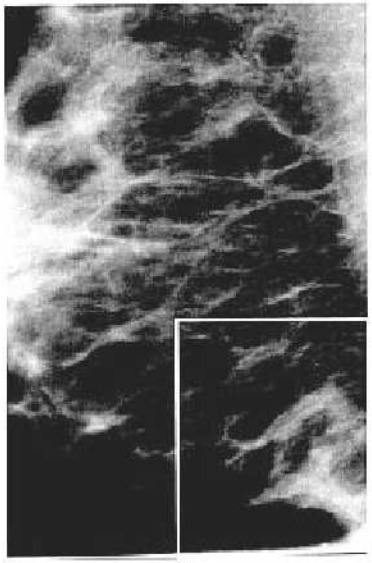

B

II Parenhüümi tüüp - rasvinvolutiivne rind

Entirely fatty replaced breast without nodular densities

Note: "The persistence of mature mammary lobules after menopause is considered to be an abnormality associated with increased risk for subsequent development of carcinoma"

WELLINGS, ET AL. 1975

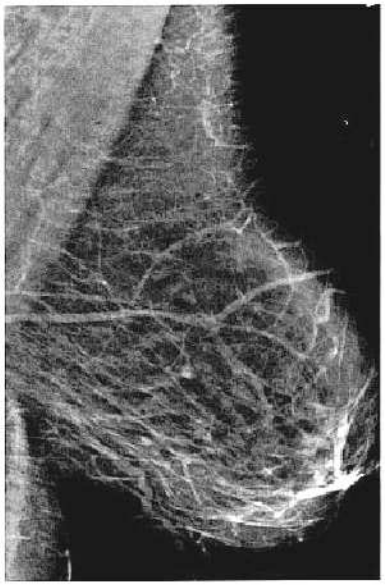

It is easy to perceive abnormalities in Patterns II & III, i.e. after the breast tissue has undergone involution.

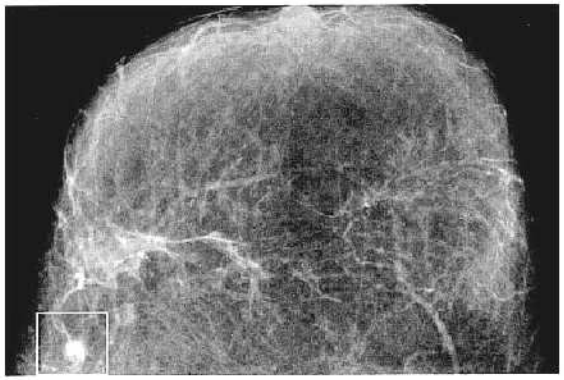

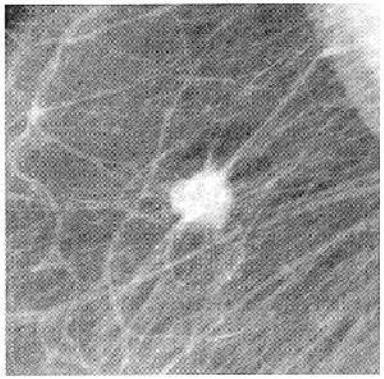

III Parenhüümi tüüp - periduktaalne fibroos

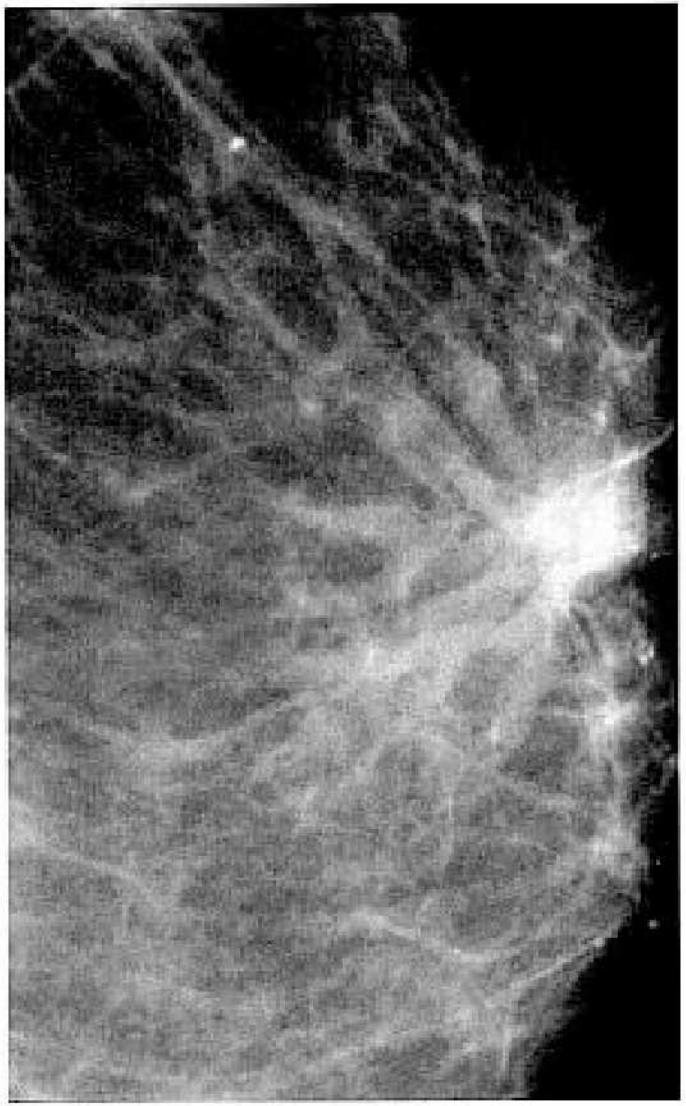

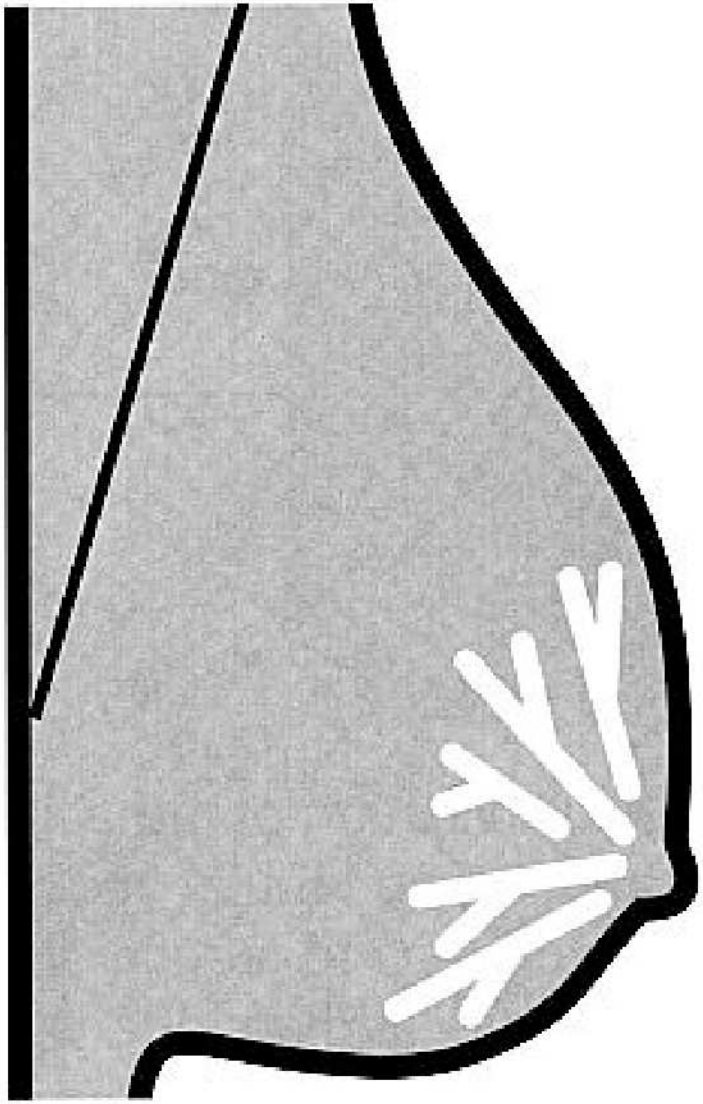

IV Parenhüümi tüüp - adenoos

Adenosis.

Hyperplasia and hypertrophy of the glandular elements.

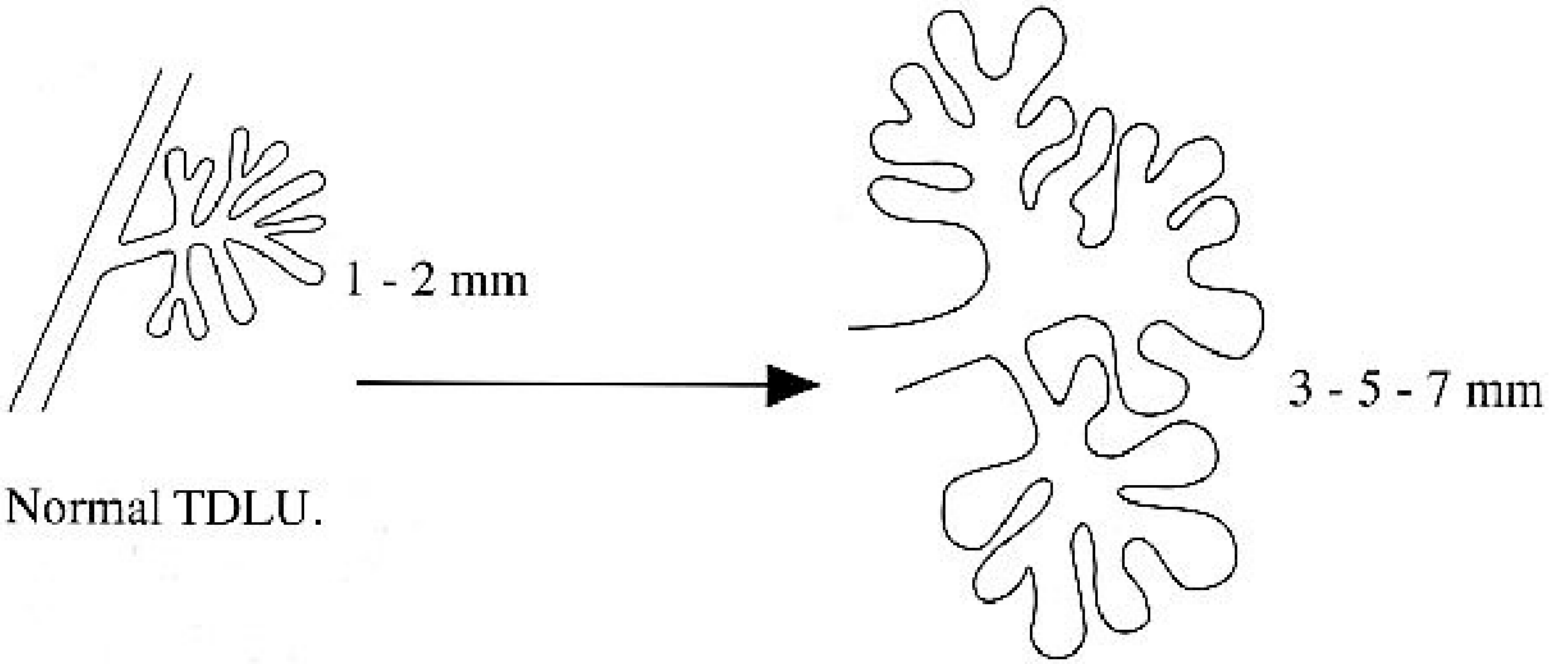

Normal TDLU.

IV Parenhüümi tüüp - adenoos

Adenosis.

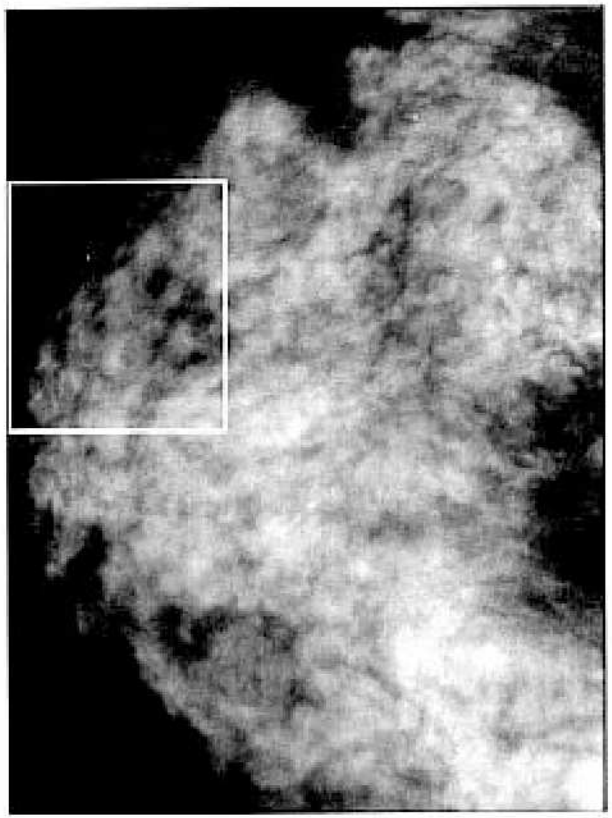

True adenosis

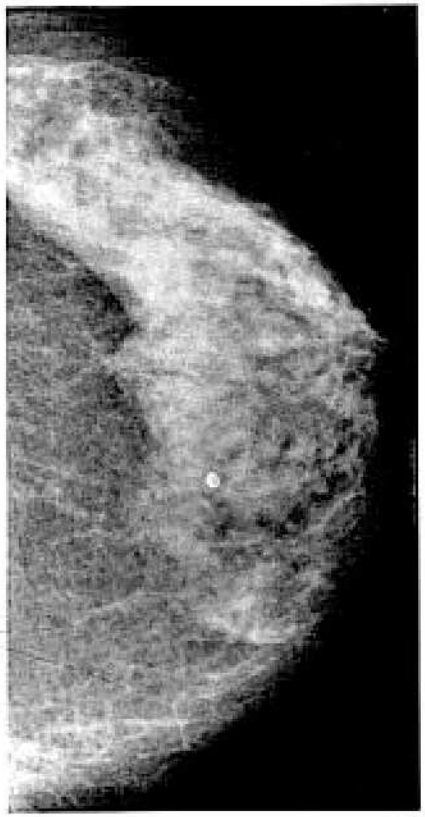

Fibrosis and adenosis

V Parenhüümi tüüp - fibroos

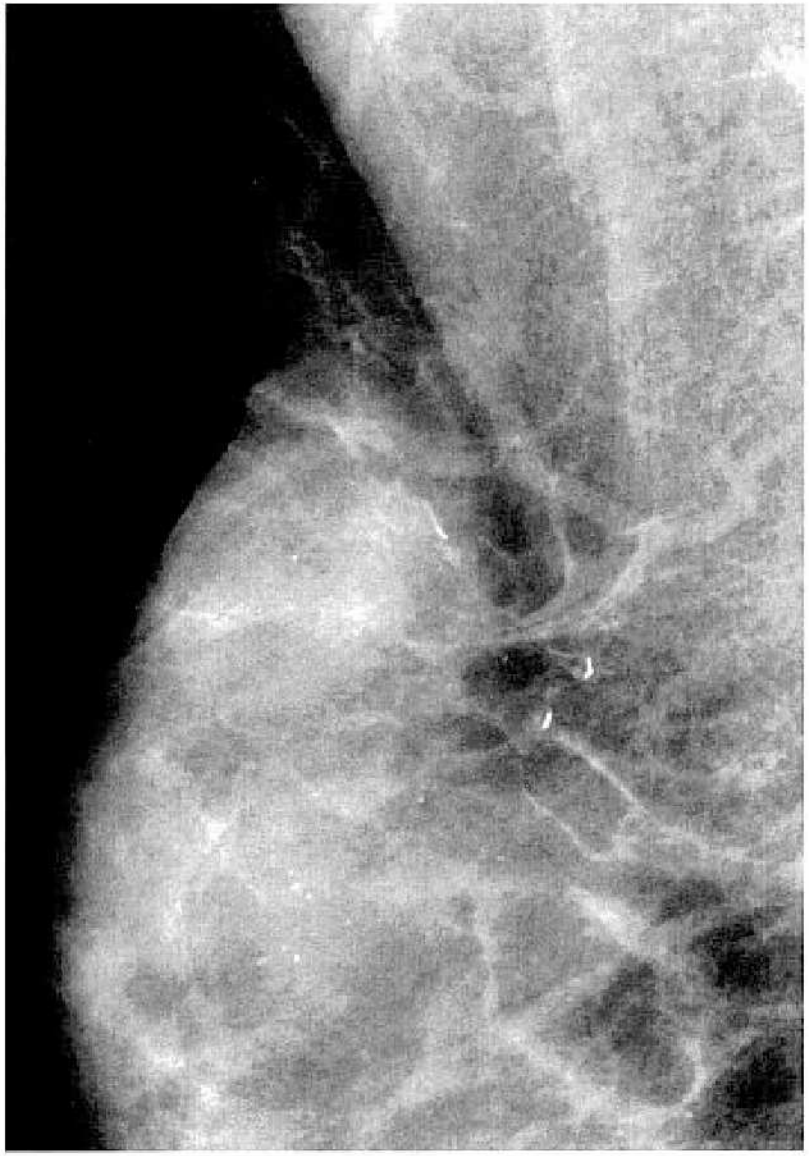

Parenhüümitüüpide **muutused** ajas

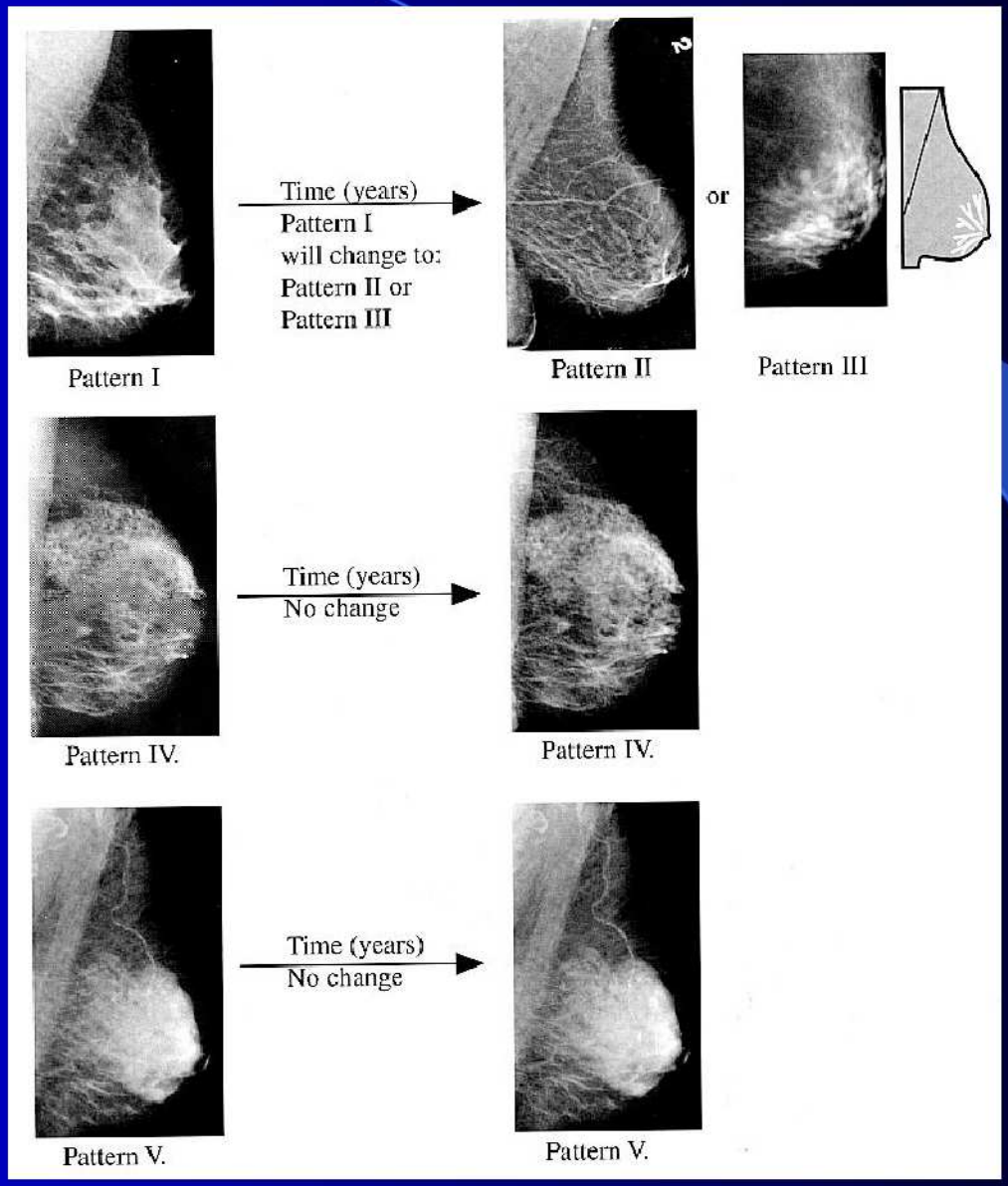

Mammogrammide **lugemine**

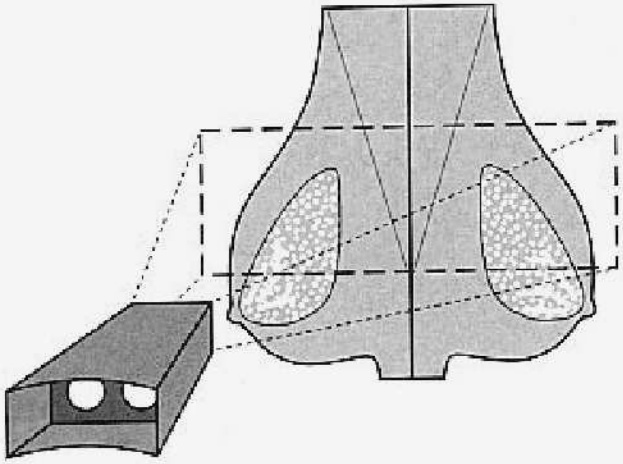

Right and left M-L-O projection

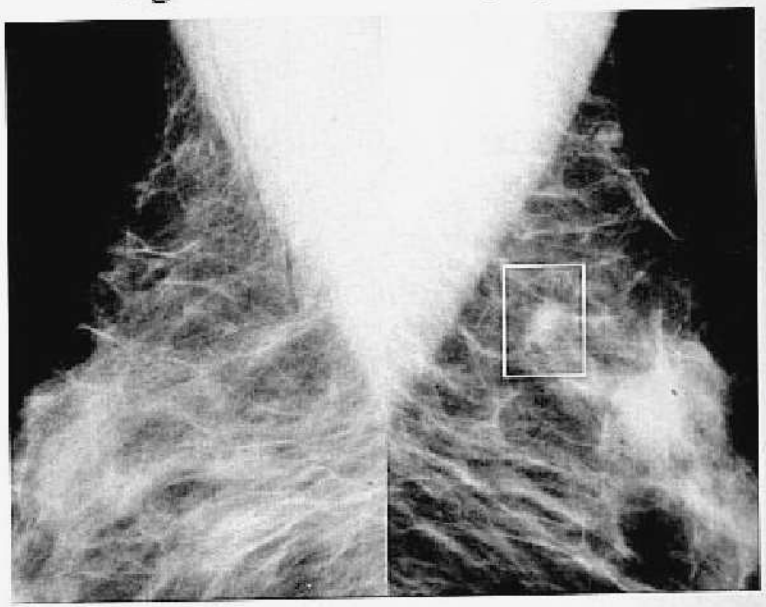

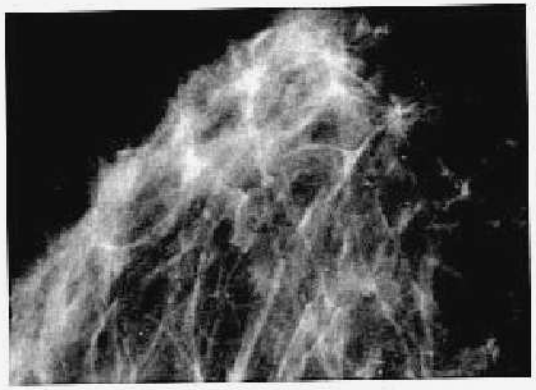

Right CC projection

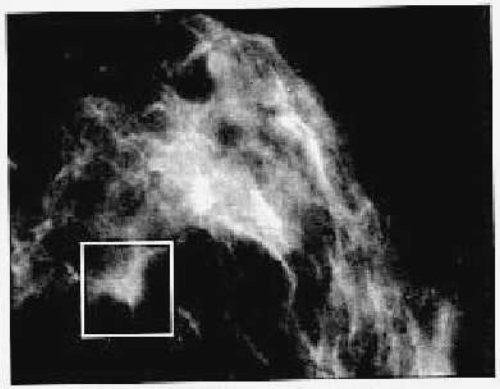

Left CC projection

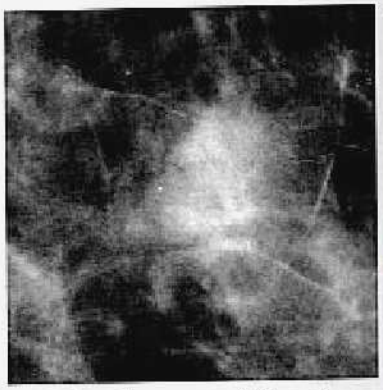

M-L-O magnification

Patoloogiliste muutuste leidmine ja analüüs

FINDING	PERCEPTION, PICK UP	DIFFERENTIAL DIAGNOSIS, ANALYSIS
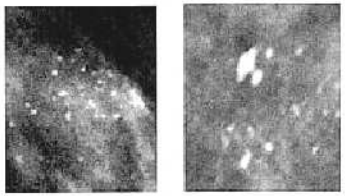 Microcalcification	P	A
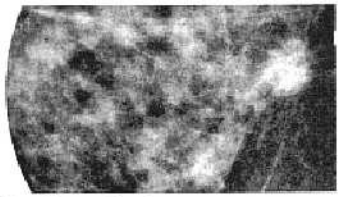 Stellate lesion	P	A
Circular lesion	P	A
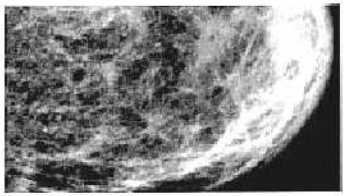 Thickened skin syndrome	P	A

Mikrolubikolded

- Lubistumised **juhades**
- Lubistumised **sagarikes**
- Lubistumised **väljaspool näärmekudet**

- Diferentsiaaldiagnostilised **kriteeriumid** :
  - Esmased : lubistumiste **kuju** ja **jaotuvus**
  - Teisesed : lubistumiste **tihedus** ja **arv**

Lubistumised juhades - **healoomused**

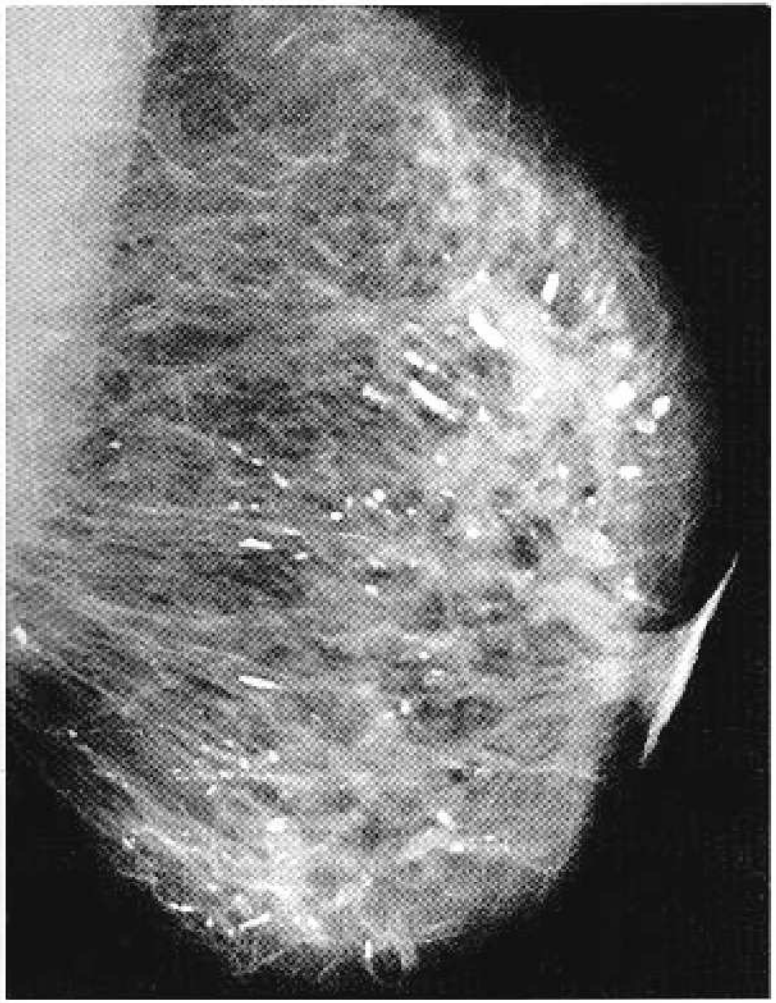

Periductal and intraductal forms

DCIS - duktaalne *in situ* kartsinoom

a) **Nuclear grade.** This is determined on the basis of nuclear size, nuclear outline, chromatin distribution, presence or absence of numerous mitoses - as predominantly high nuclear grade / intermediate / predominantly low nuclear grade.

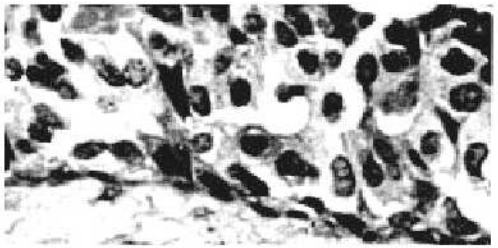

High nuclear grade

Low nuclear grade

b) **Growth pattern** / architecture of the proliferating malignant cells:

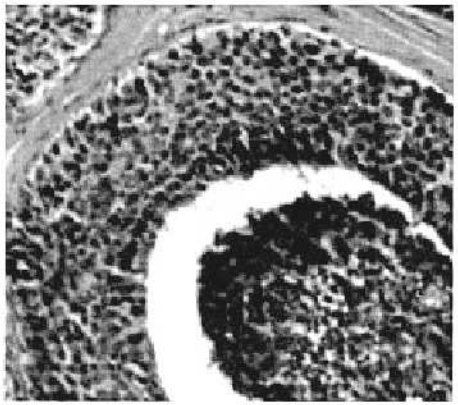

Solid

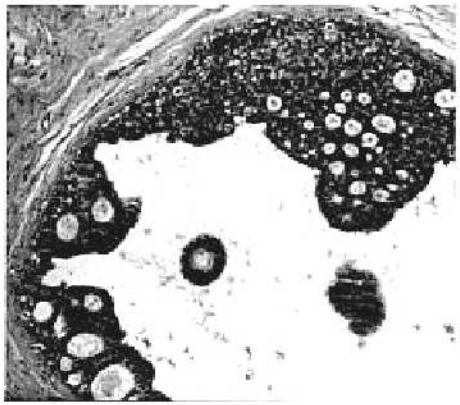

Cribriform

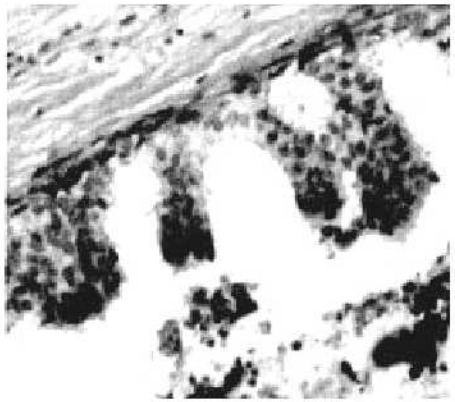

Micropapillary

Maliigset tüüpi **(“casting”)** lubikolded

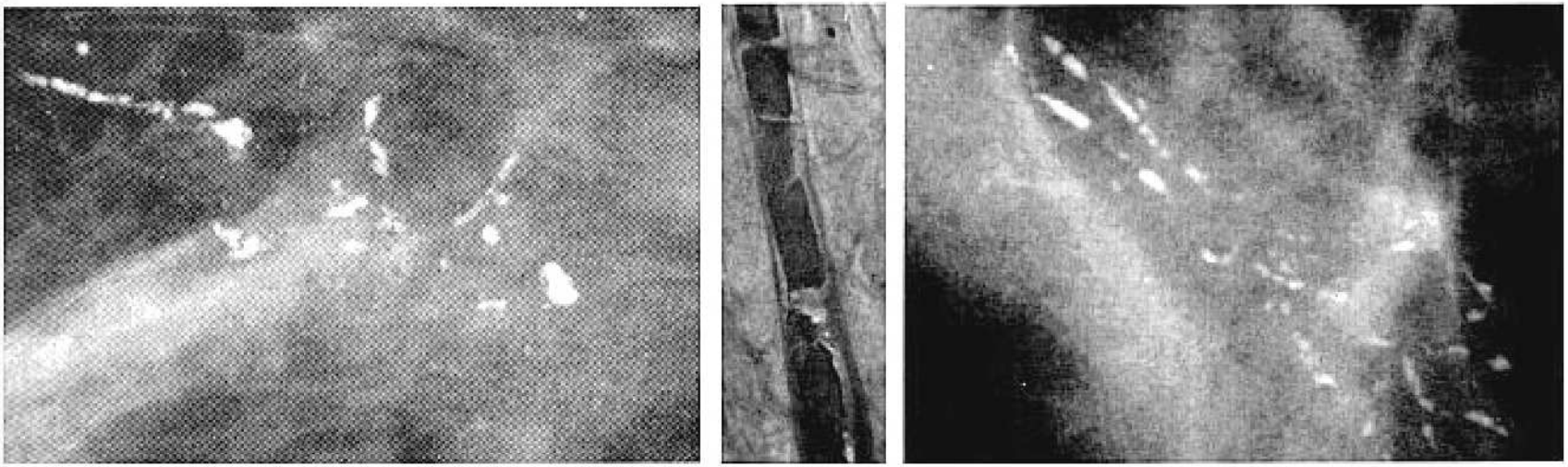

Casting type calcifications

“Maonaha-taolised” lubistumised

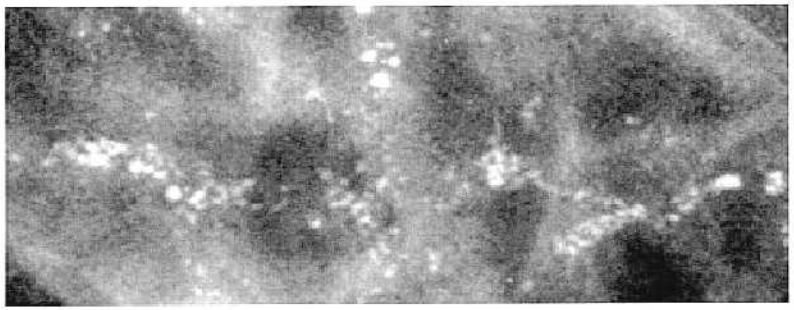

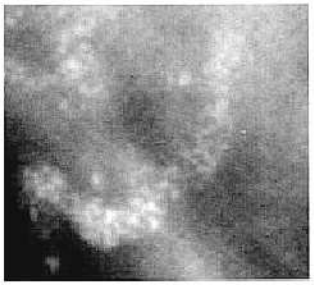

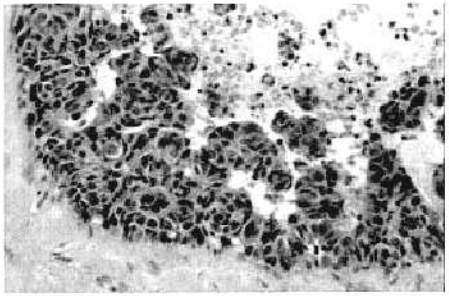

High nuclear grade DCIS, micropapillary growth pattern

Morbus Paget

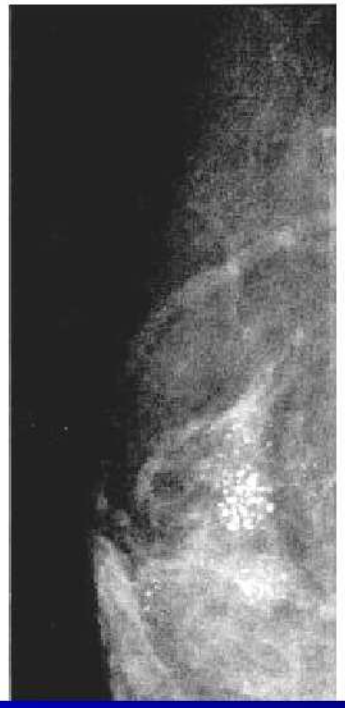

Lubistumised **sagarikes**

Multiple lobules / clusters

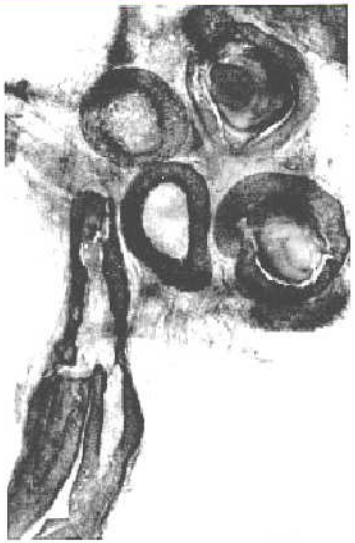

DCIS-solid cell prolif.

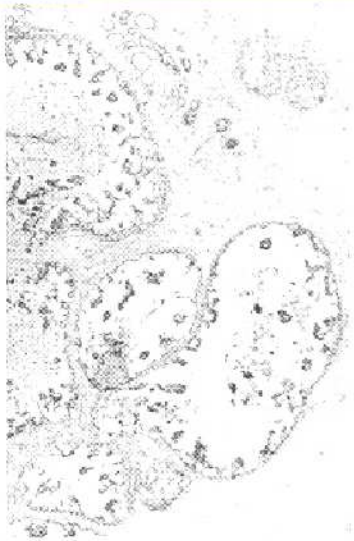

DCIS-micropapillary prolif.

"Involutional type" calcif.

Sclerosing adenosis

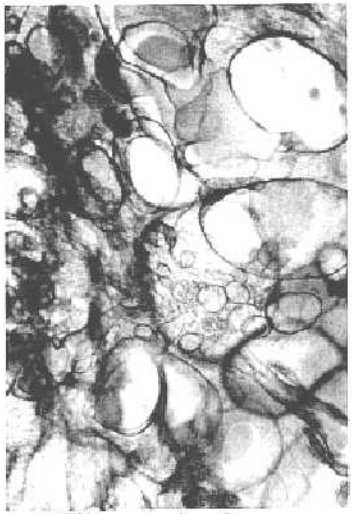

Fibrocystic change

Fibrotsüstilised muutsed

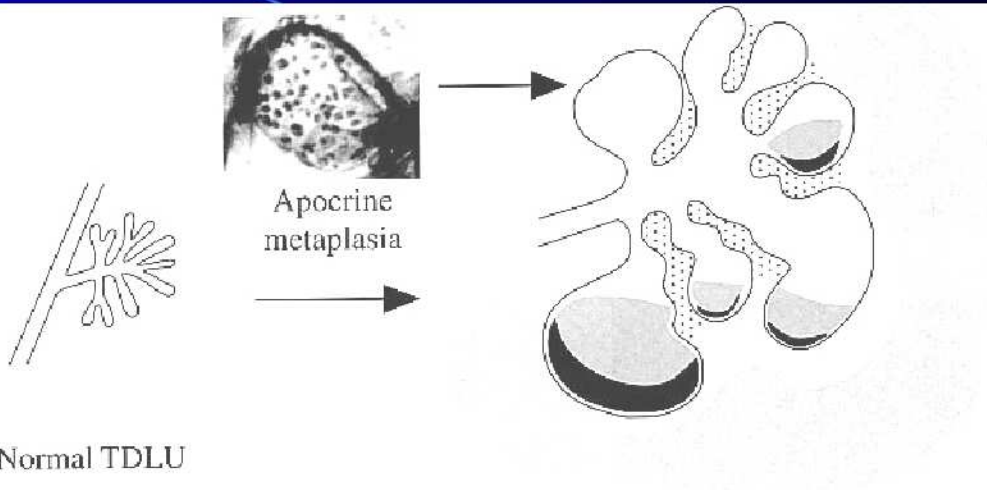

Calcifications in fibrocystic change

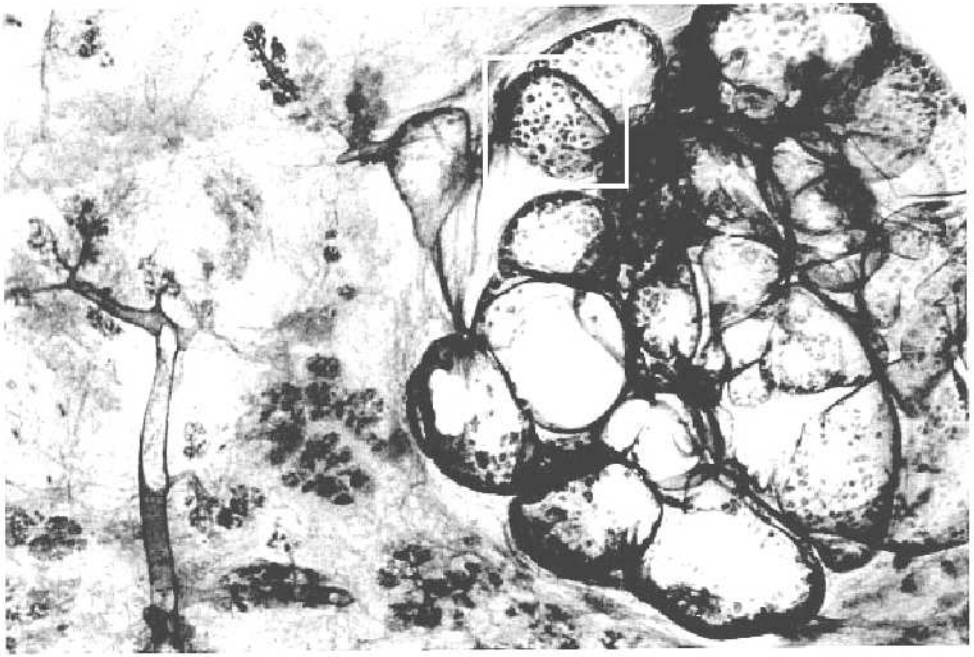

Nn. “teetassi” sümptom

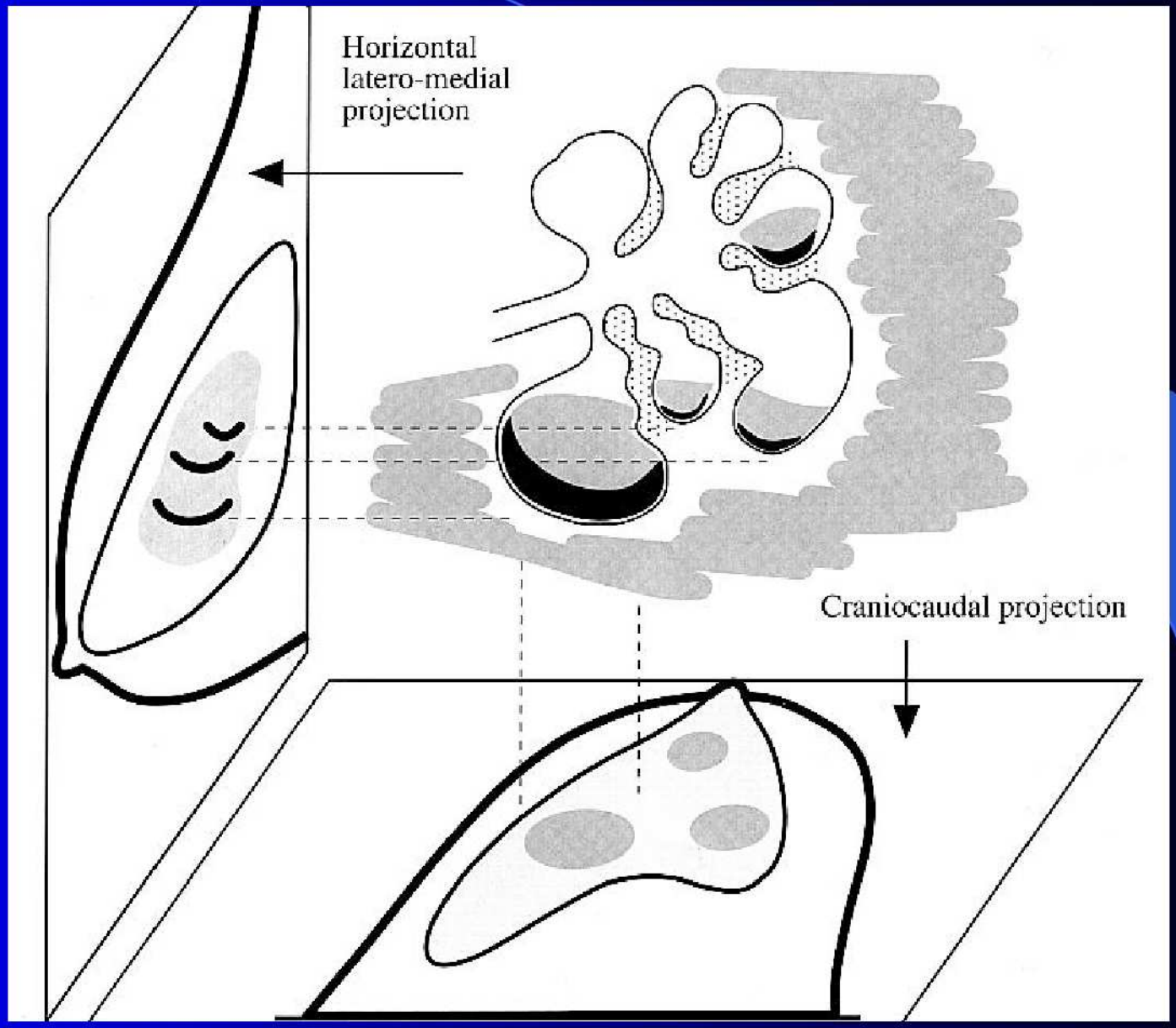

Lubistumised **väljaspool** näärmekudet

1. **Calcified artery**

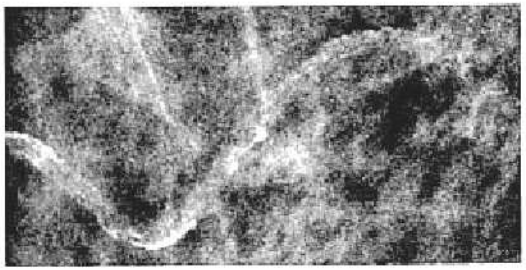

2. **Sebaceous glands**

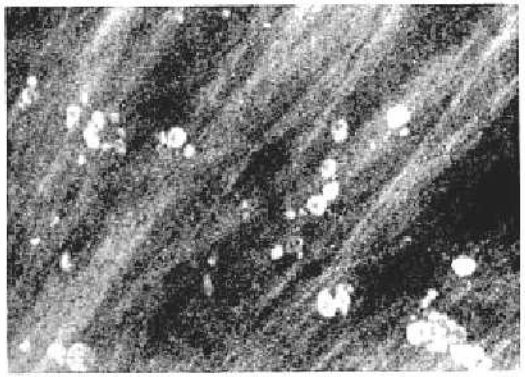

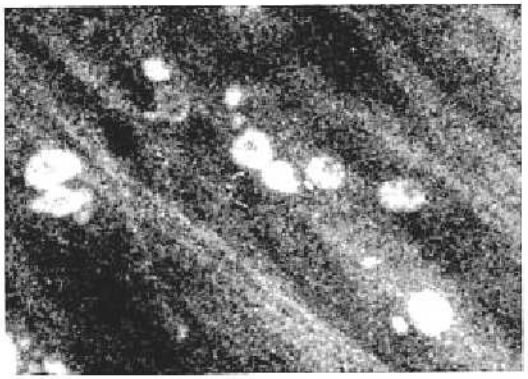

Lubistumised **väljaspool** näärmekudet

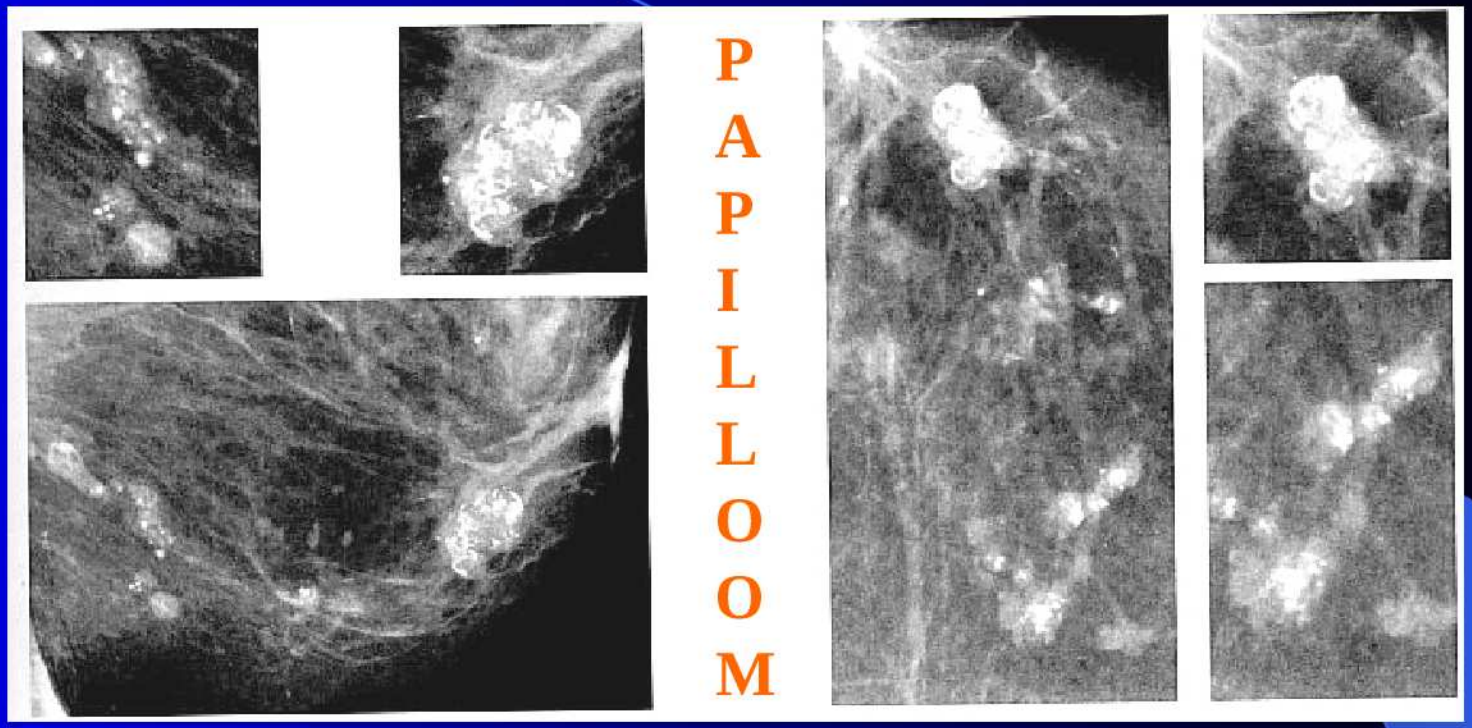



A. Coarse, "pop-corn" like calcification. No differential diagnostic problem.

Lubistumised **väljaspool** näärmekudet

7. Calcified suture.

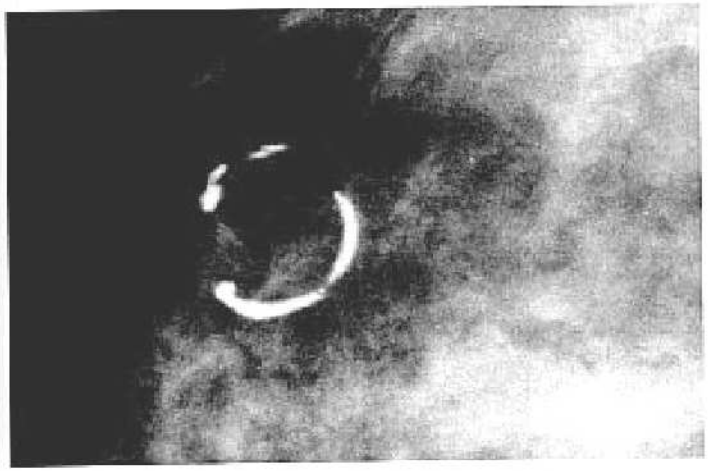

8. Cavernous hemangioma.

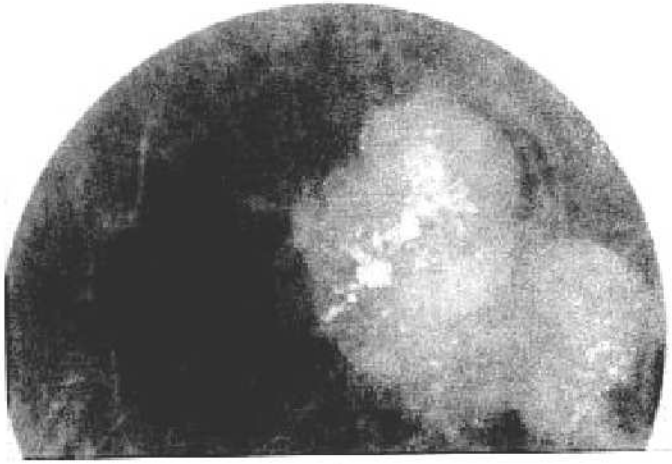

9. Calcifications in postsurgical scar.

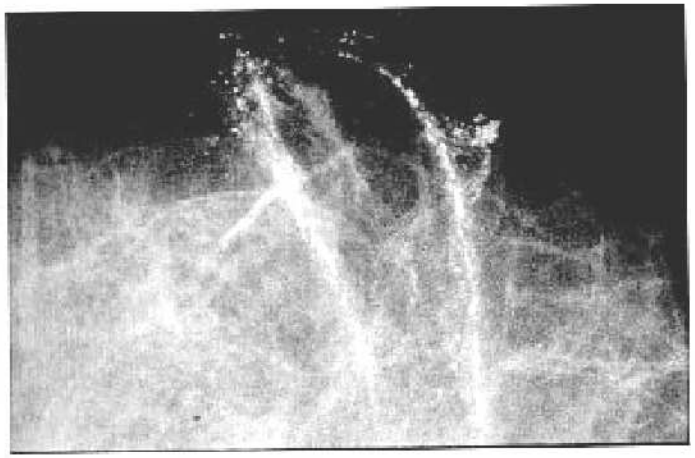

10. Wart.

Ümar-ovaalsed lisavarjustused

- **Kontuuri** analüüs :
  - **Teravalt** piirdunud
    - Kapsliga piirdunud
    - Halo sümptom
    - Lihtsalt hästipiirdunud
  - **Ebateravalt** piirdunud (**sageli maliigsed!**)
- **Tiheduse** analüüs :
  - **Madala** tihedusega
  - **Inhomogeense** tihedusega
  - **Tihedad**
    - Väga tihedad (**sageli maliigsed!**)
    - Isodenssed (näärmekoe tihedusega)

Kapsliga piirdunud ja **“halo”** sümptom

- Lipoma
- Oil cyst
- Galactocele
- Fibro-adeno-lipoma

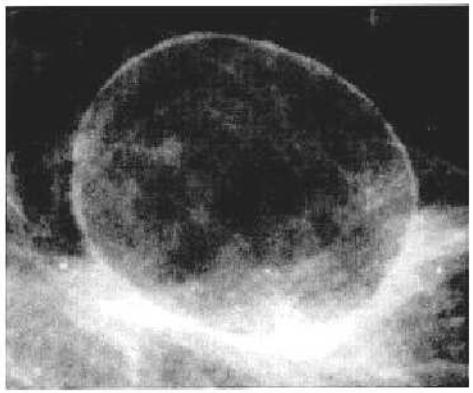

Halo sign - partial or extensive - is seen at the contour of growing benign lesions. Best seen on compression views. It is a very thin lucent line following the contour of the lesion (Mach band).

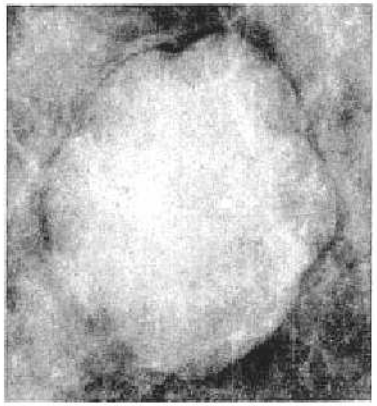

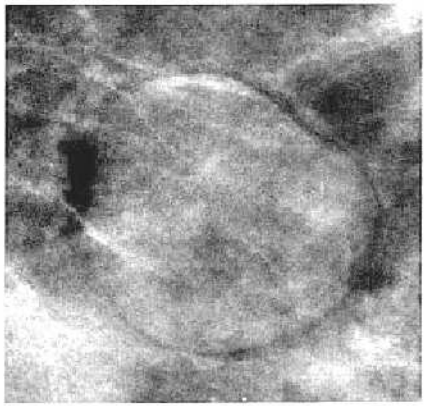

Lihtsalt hästipiirdunud

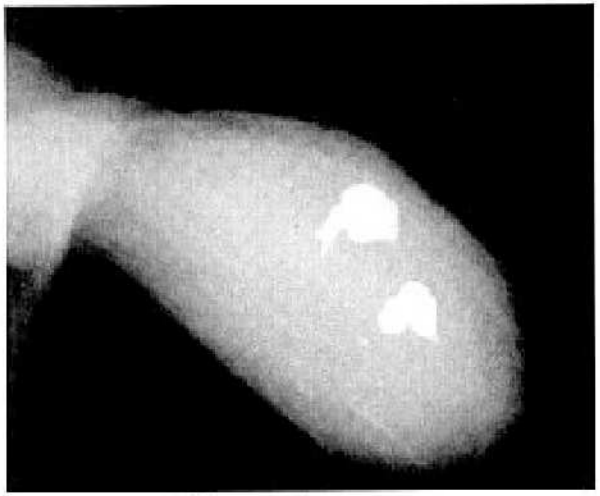

Fibroadenoma

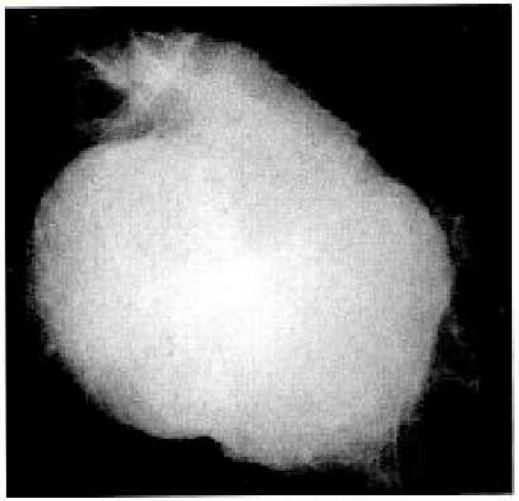

Fibroadenoma

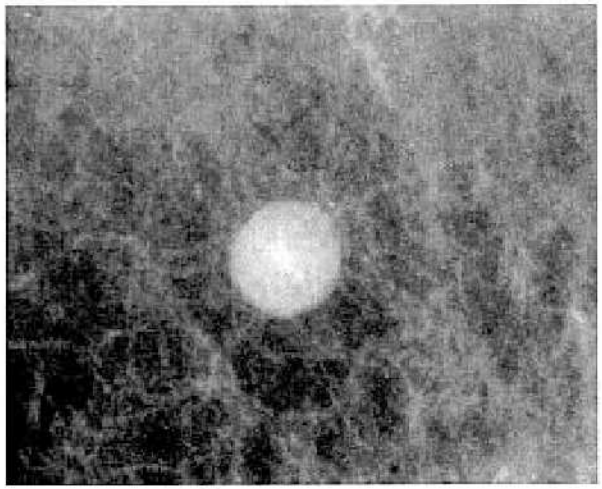

Sebaceous cyst

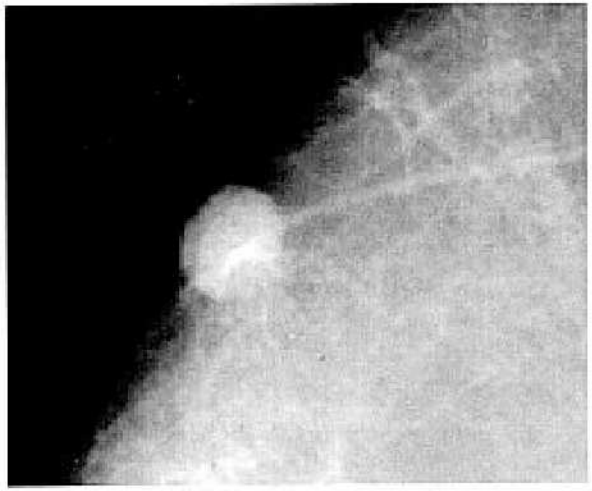

Sebaceous cyst

Halvasti piirdunud lisavarjustused

Comet tail sign

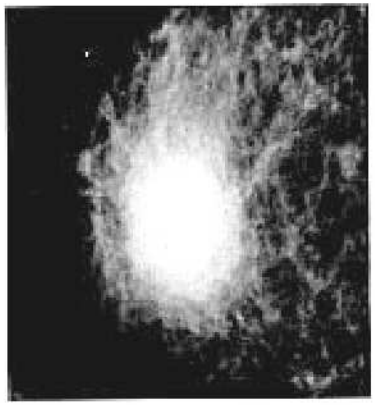

Poorly outlined

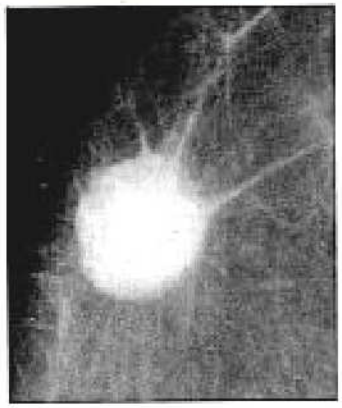

Spiculated

Madala tihedusega

Lipoma

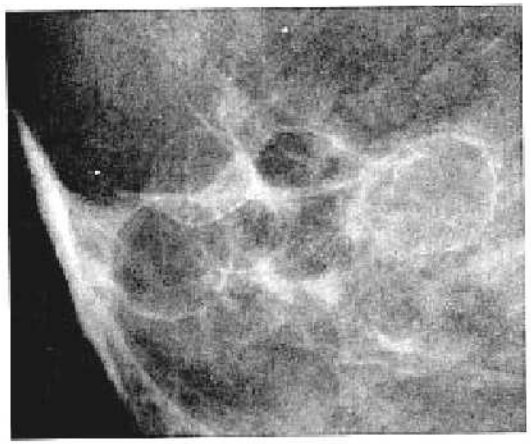

Oil cysts

- Oil cyst
- Lipoma
- Galactocele

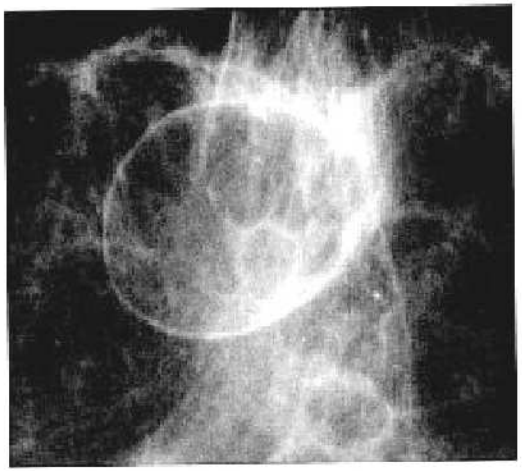

Oil cysts following breast reduction surgery

Inhomogeense tihedusega

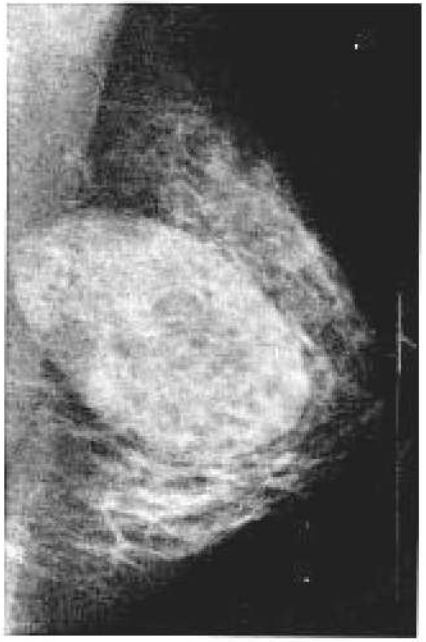

Fibroadenolipomas are always encapsulated and usually large.

Galactocele.



Tihedad lisavarjustused

Väga tihedad

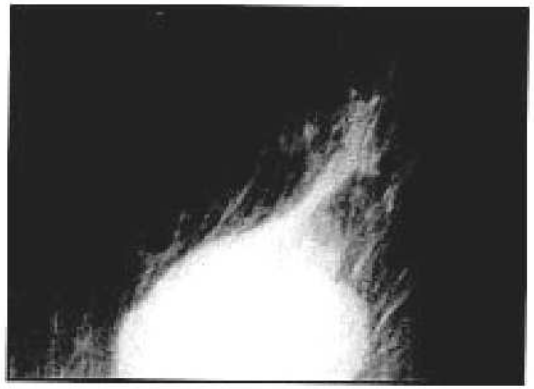

Carcinoma

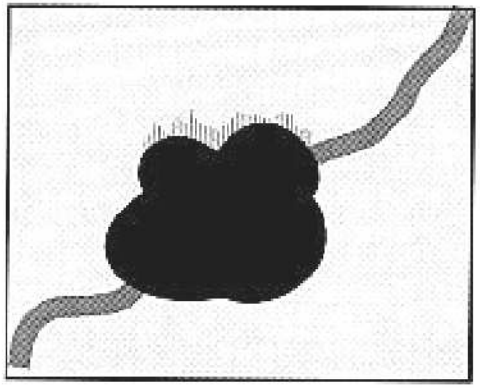

Postop. hematoma

Isodenssed

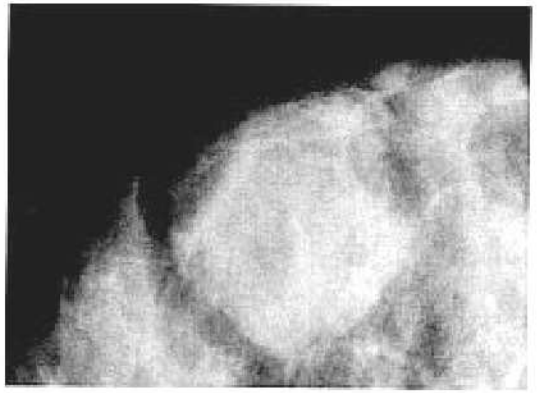

Cyst

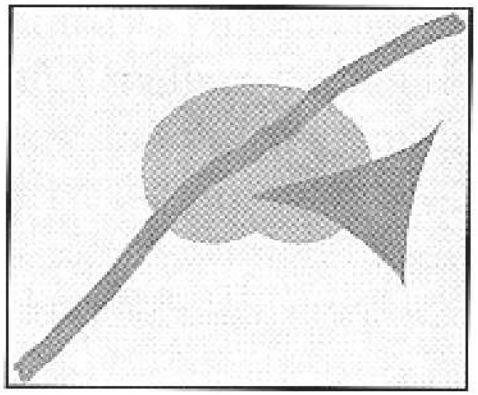

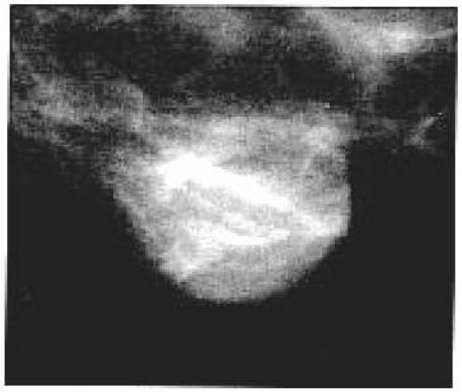

Fibroadenoma

Piirdunud kartsinoomid!

Mutsinoosne vähk

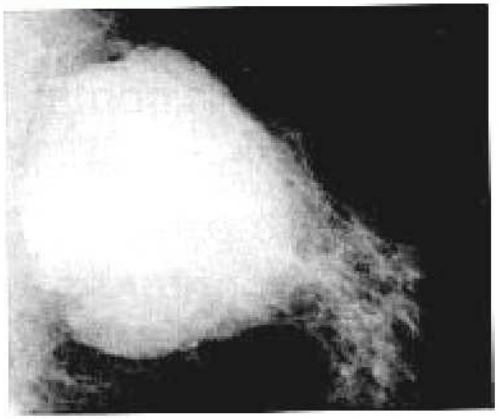

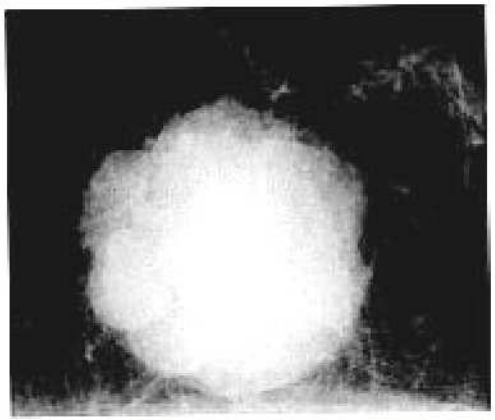

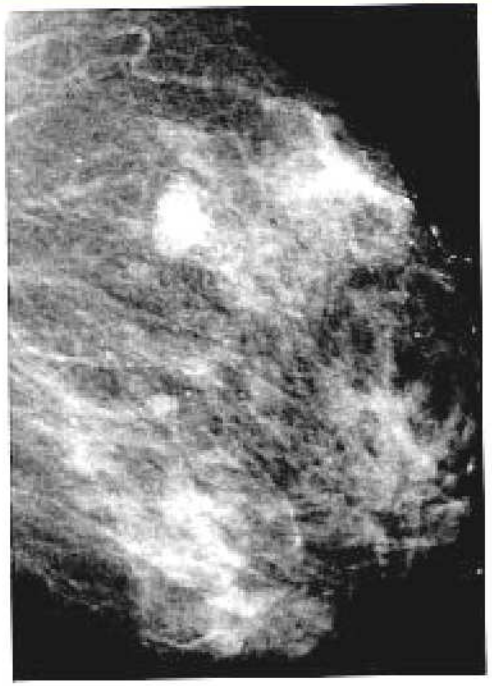

Medullaarne kartsinoom!

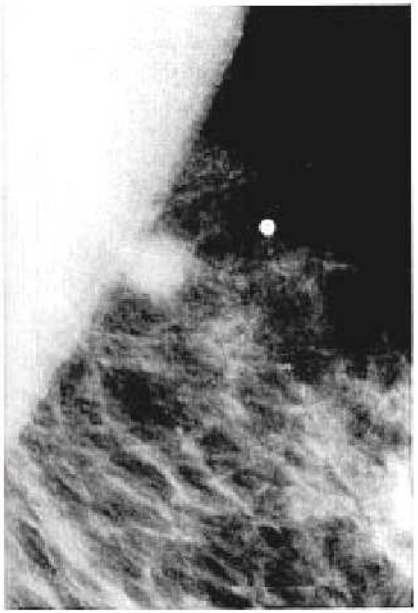

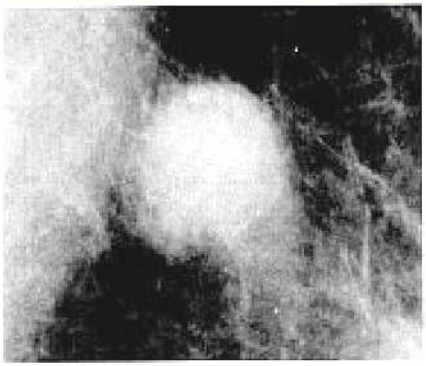

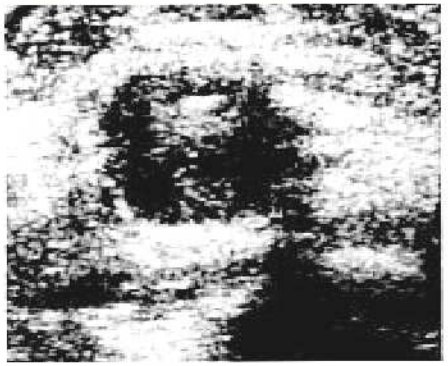

Cumulative survival of women aged 40-74 years with medullary carcinoma. W-E trial.

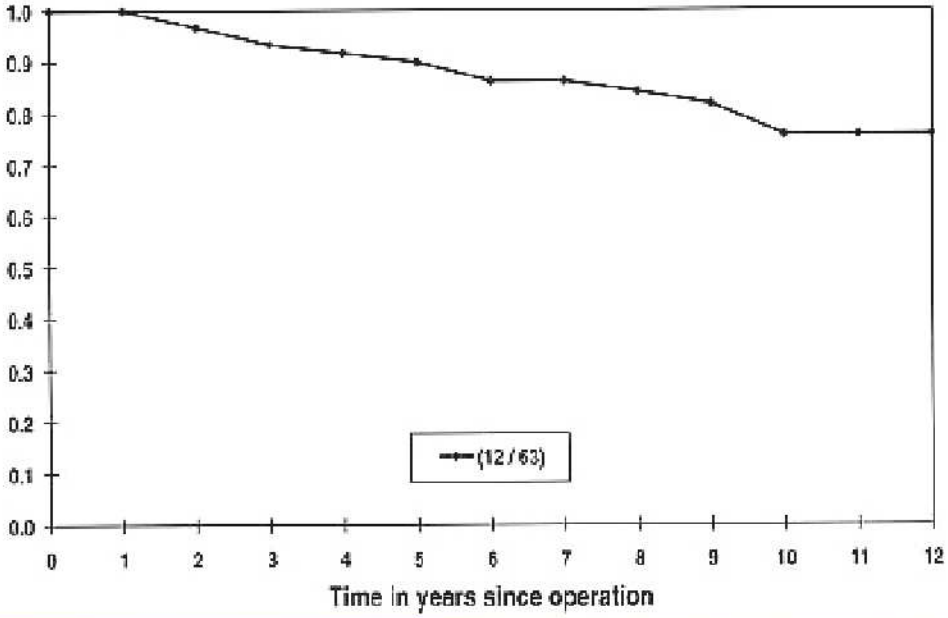

Asümmeetrilised ja kiirjate jätketega lisvarjustused

- **Parenhüüm või fibroos**
- Mittespetsiifiline lisavarjustus
- **Konkreetne** patoloogiline muutus
  - S.h. **kiirjate jätketega** lisavarjustus

Asümmeetriline involutsioon

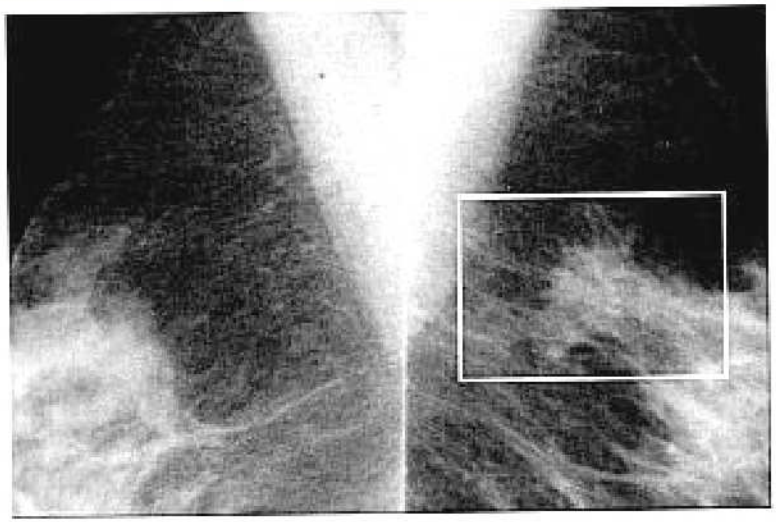

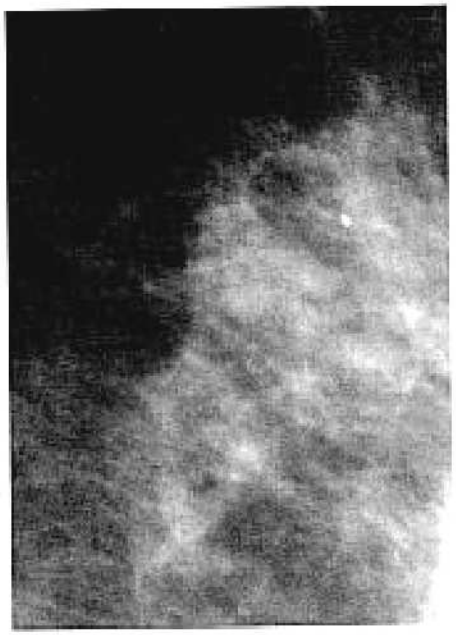

Fokaalne **fibroos** või **armkude**

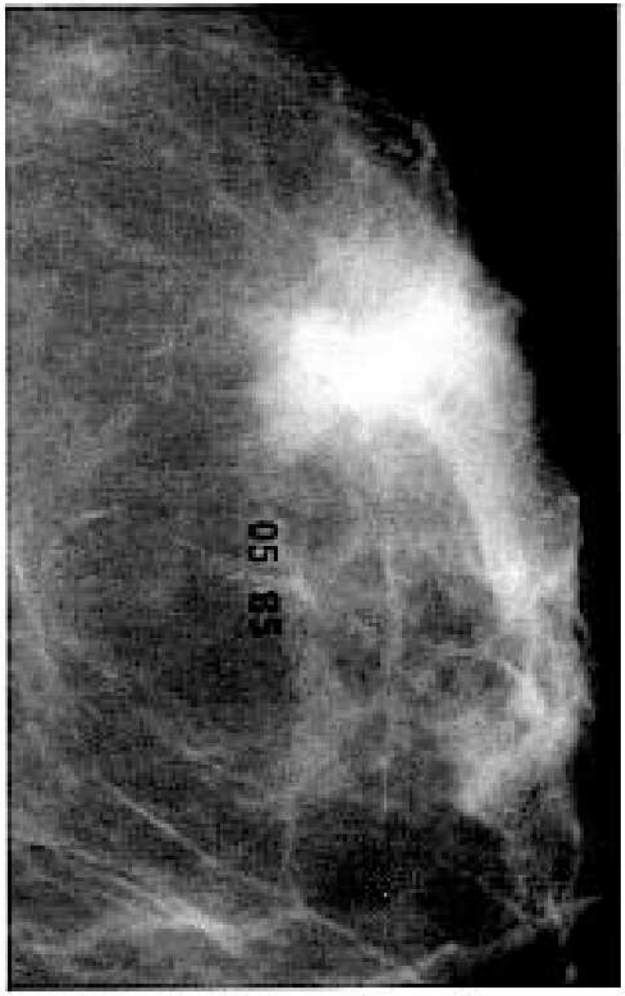

MLO projection

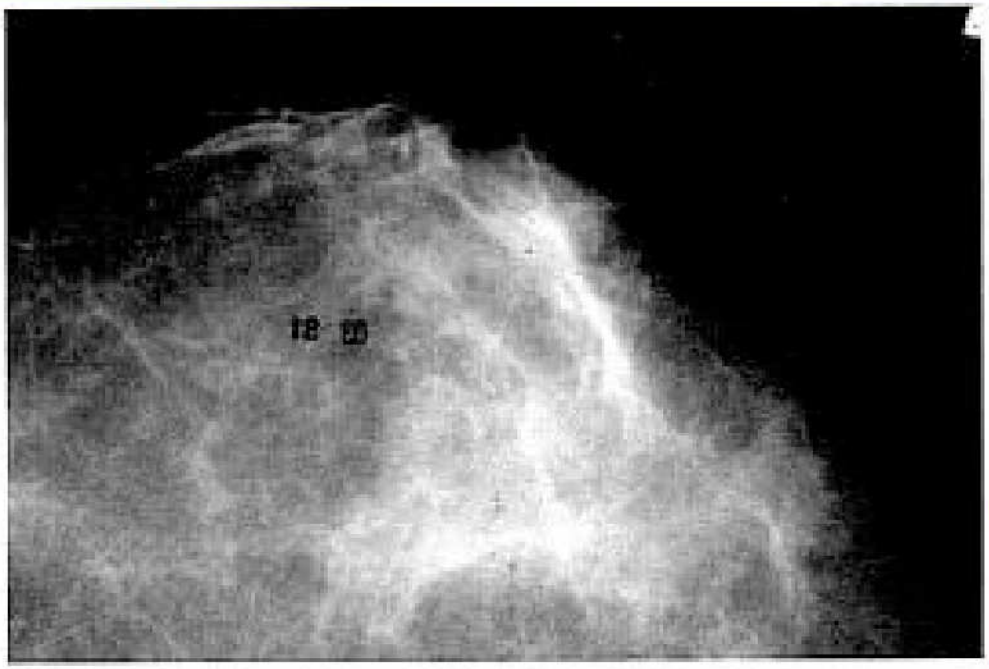

CC projection

Parenhüümi **kontuuri** sissetõmme

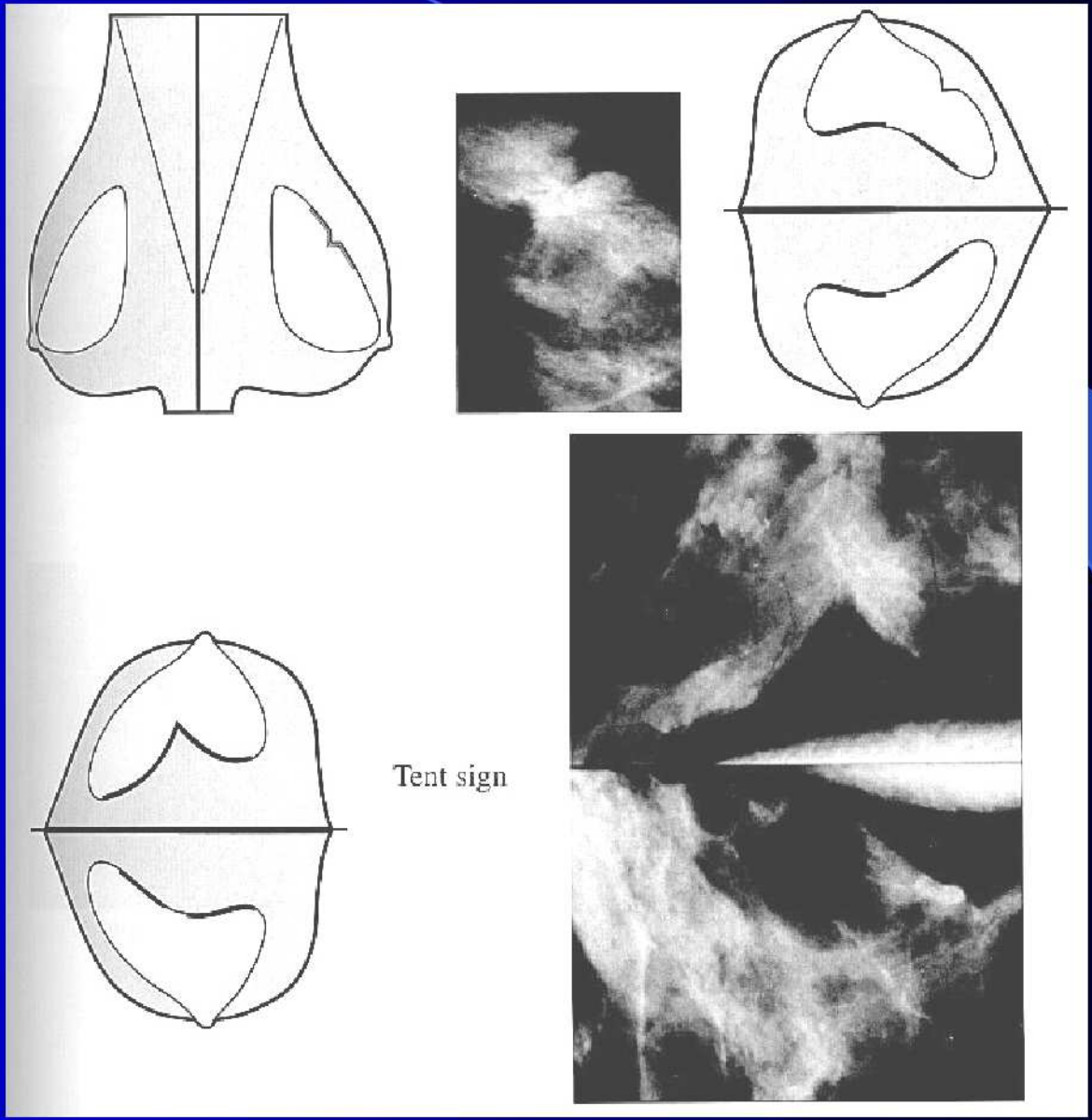

Strooma **deformatsioon**

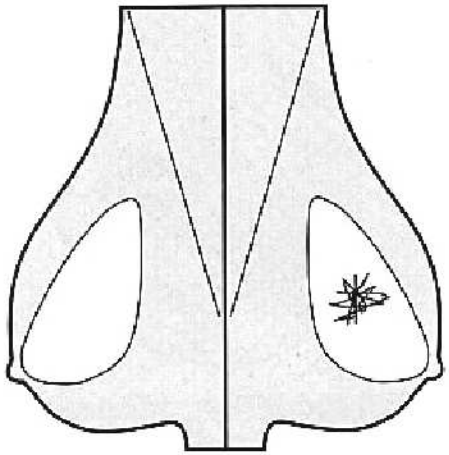

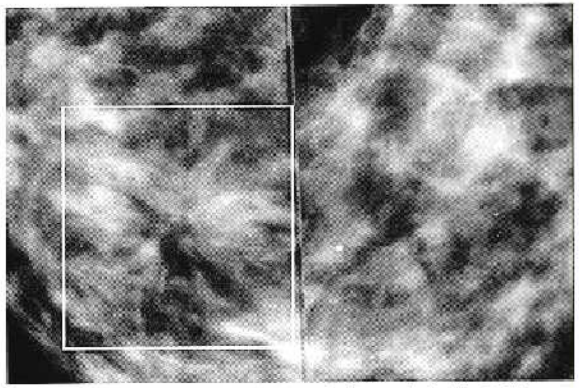

Example 1. Right CC and left CC

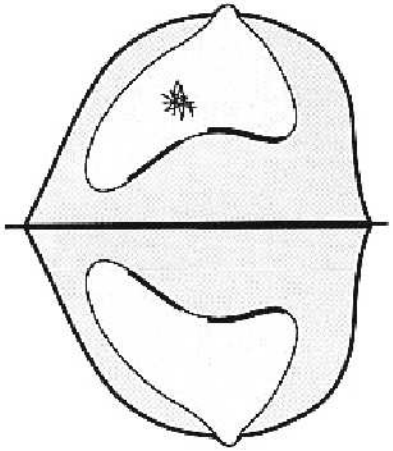



Example 2

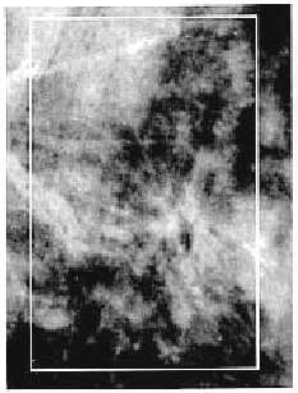

Example 3

Kiirjate jätketega lisavari

- Nn. **“valge täht”** - invasiivne duktaalne **Ca!**
- Nn. **“must täht”** - radiaalne arm; skleroseeruv juhade hüperplaasia (adenoos)

Kiirjate jätketega lisavari

- **“Valge täht”** - invasiivne **duktaalne Ca!**
  - Eristatav tihe **tsentraalne** tuumorimass
  - Igas suunas radieeruvad **tihedad** spiikulad
  - Spiikulad on **proportsionaalsed** tu!-i suurusega
  - Nahani või lihaseni ulatuvad spiikulad võivad põhjustada **sisse(ära)tõmmet** ja lokaalset naha **paksenenmist**

“Valge täht” - invasiivne duktaalne Ca!



“Valge täht”
Invasiivne duktaalne kartsinoom



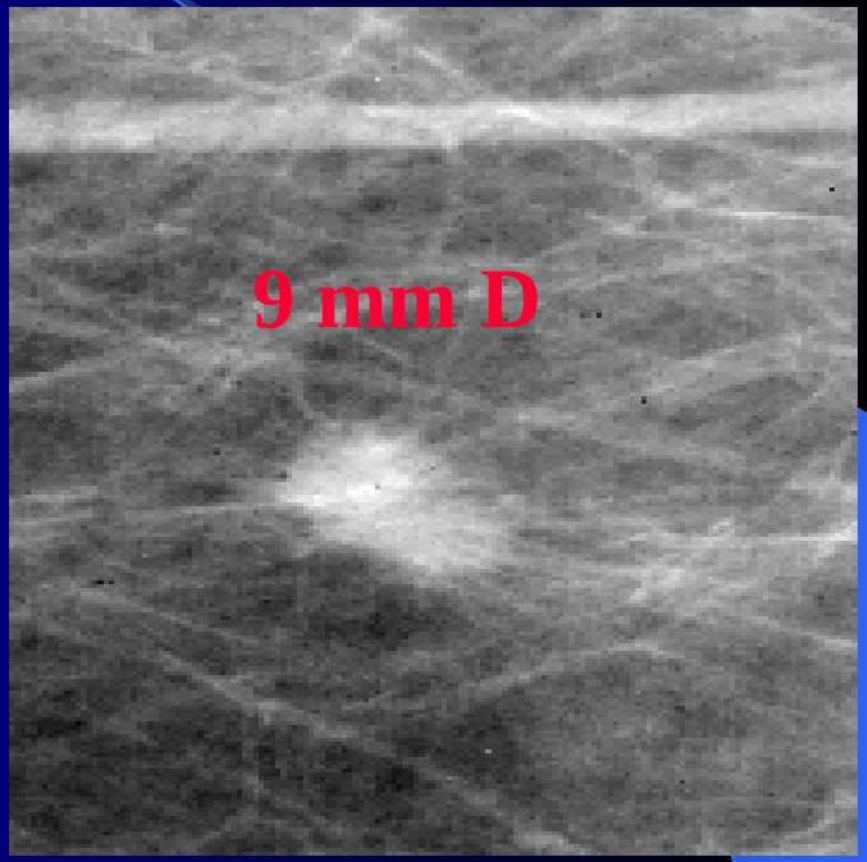

“Valge täht” - invasiivne duktaalne Ca!

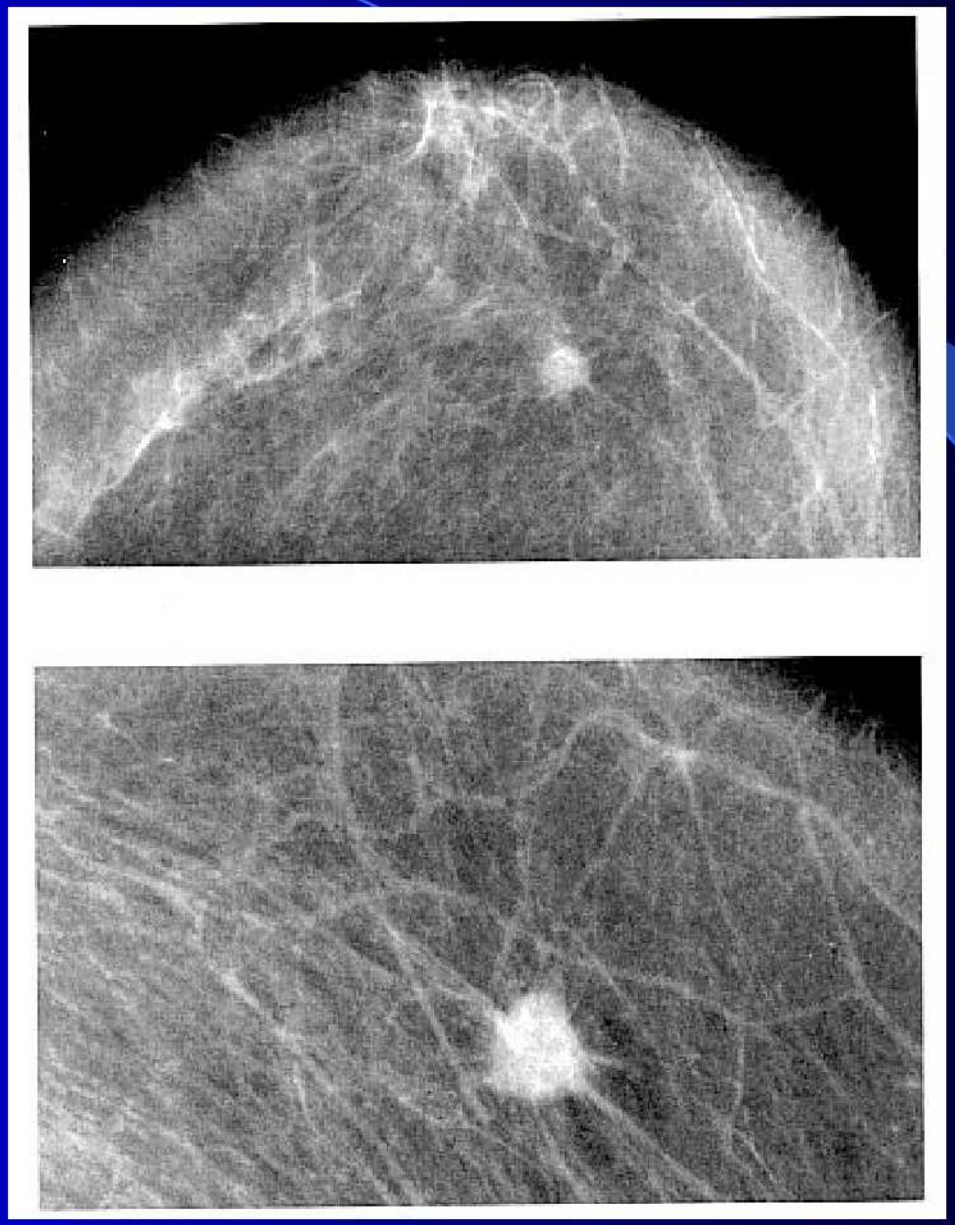

Kiirjate jätketega lisavari

- **“Must täht”** - radiaalne arm; skleroseeruv juhade hüperplaasia
  - **Puudub** tsentraalne tihe **tuumorimass** (ilmestuvad ümar-ovaalsed hõrenemised)
  - Spiikulad **ei ole** proportsionaalsed muutuse suurusega, on ebaühtlase kuju ja tihedusega, sageli **kimpudena** (eriti tsentraalsemal)
  - Kunagi **ei ole** naha paksenemist ega sissetõmmet
  - Olenemata lisavarjustuse suurusest

    ei ole muutus palpeeritav!

“Must täht” - radiaalne arm



Radiaalne arm

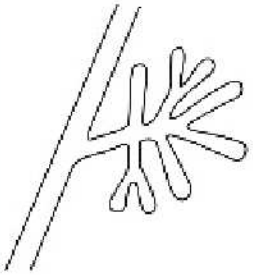

Normal TDLU

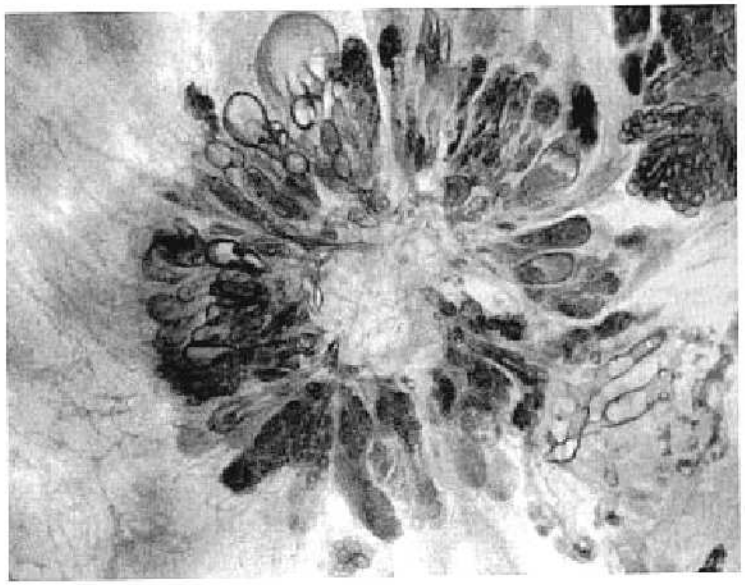

Radial scar

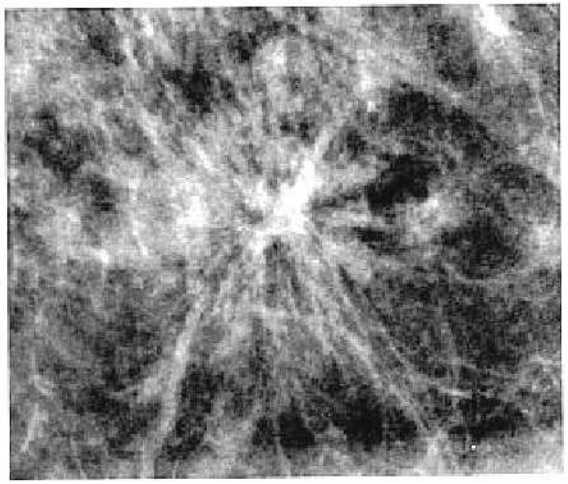

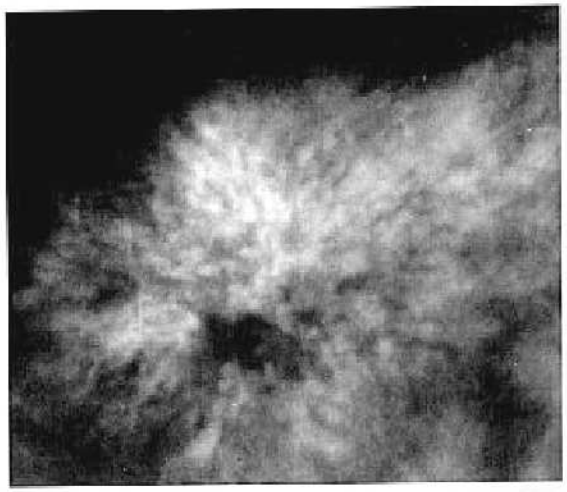

Infiltreeritud rinna sündroom

- **Objektiivselt :**
  - “apelsinikoore” fenomen
  - rinna punetus (võib puududa)
  - suur tuumor / haavandumine
- **Mammogrammidel :**
  - nahk on **paksenenud** (rohkem alaosades)
  - rind on **intensiivse(ma)lt** varjustatud
  - ilmestub **jämetrabekulaarne** joonis

Infiltreeritud rinna sündroom

- Põhjused :
  - Kaugelearenenud **rinnavähk**
    - primaarne
    - sekundaarne (akslill. mts!-d kontralateraalselt)
  - Rinna **põletikud** (abstsess)
  - Krooniline **südamepuudulikkus**
  - Krooniline **neeruhaigus** (hüpo-albumineemia)
  - Kaugelearenenud **günekoloogiline** tuumor

    (**metastaasid** aksillaarsel torako-hüpogastriliste kollateraalide kaudu)

Infiltreeritud rinna sündroom

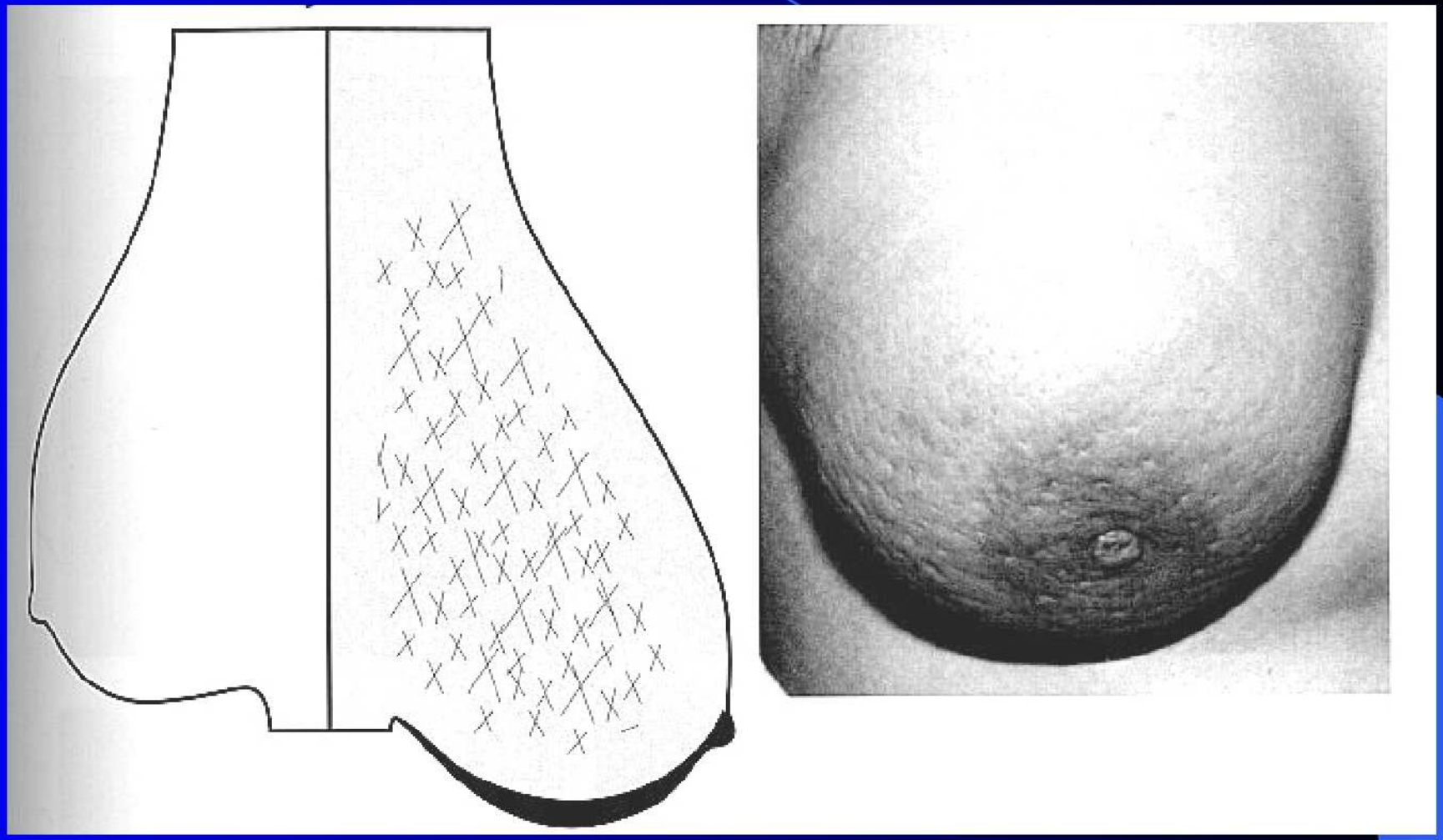

Mikrolubistumistega rinnavähk



“Keelatud alad” I - nn. **“linnutee”**

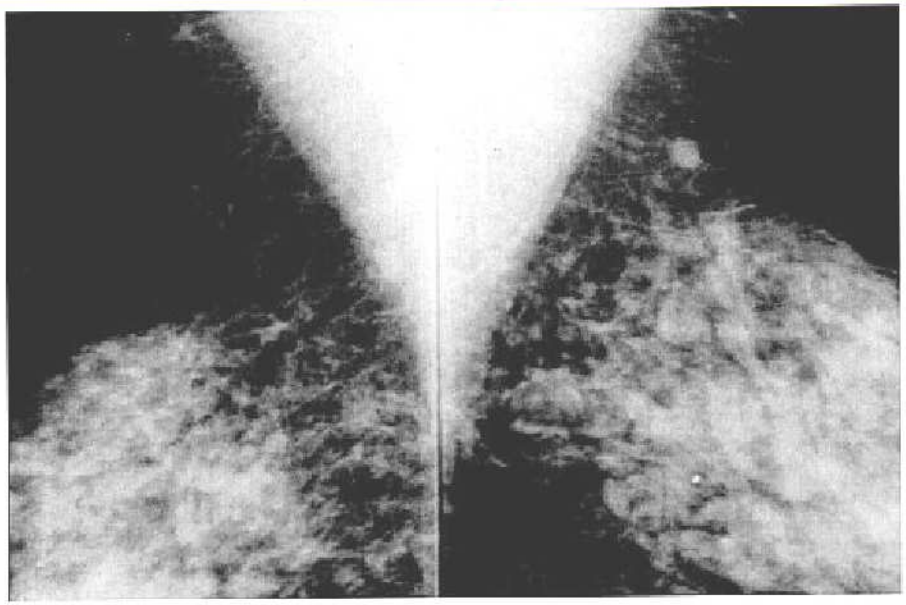

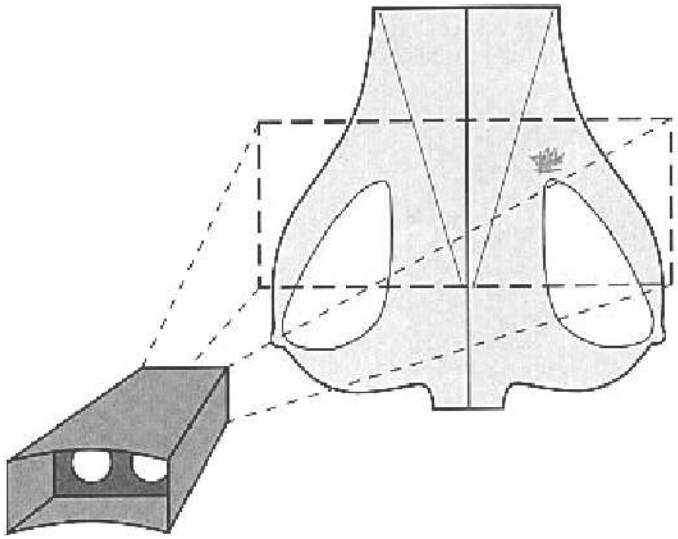

“Keelatud alad” II - nn. **“eikellegimaa”**

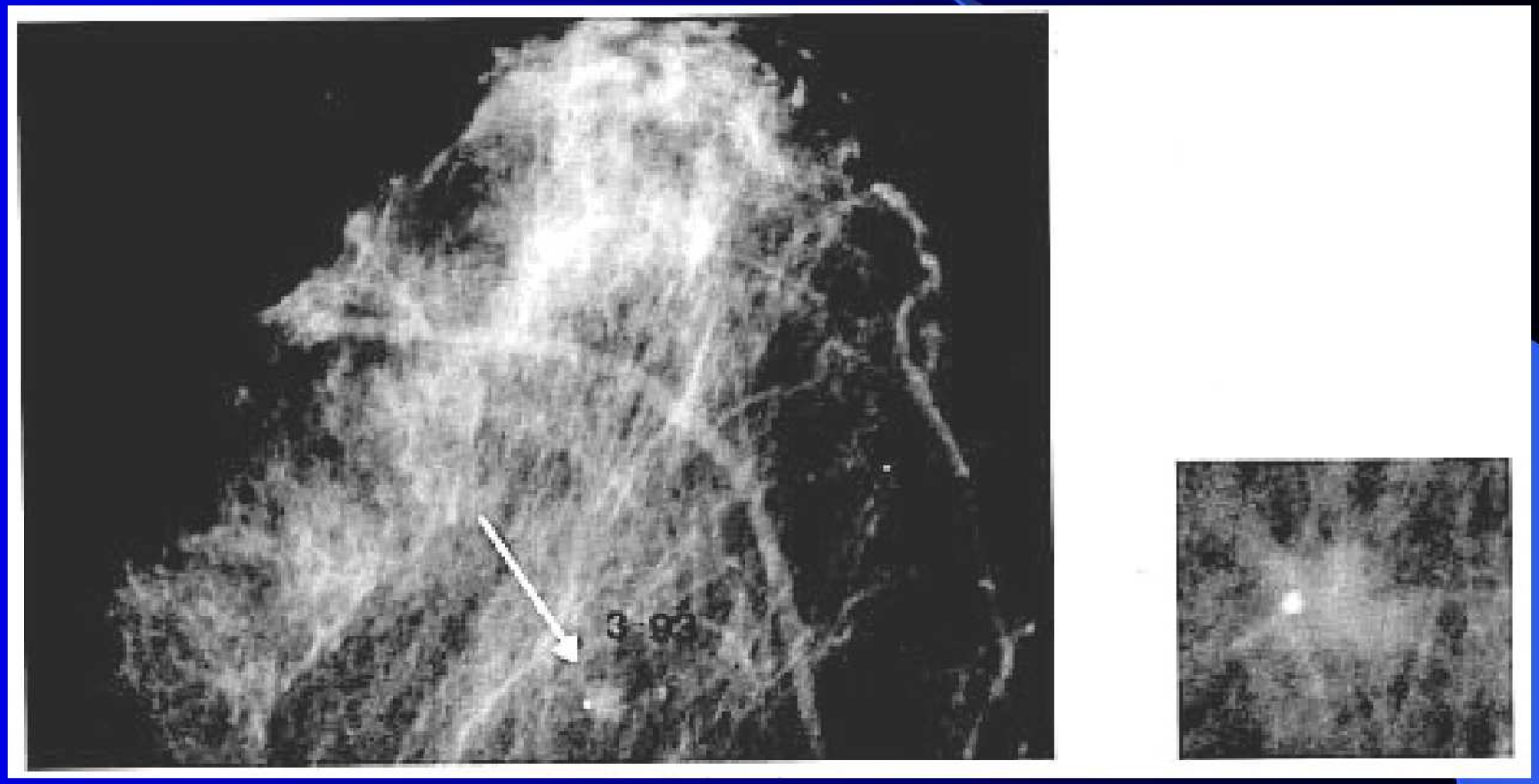

“Keelatud alad” III – rindade **mediaalsed osad**

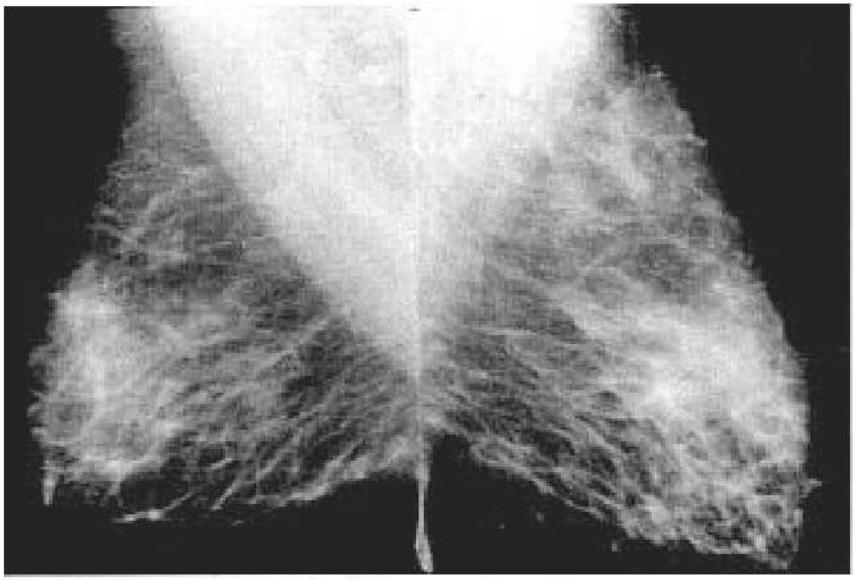

M-L-O projection

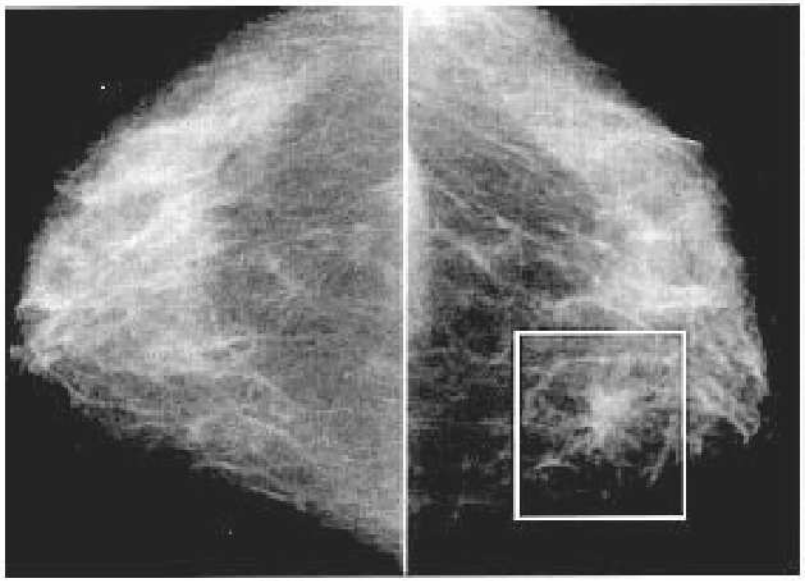

CC projection

“Keelatud alad” IV - **nibutagune** piirkond

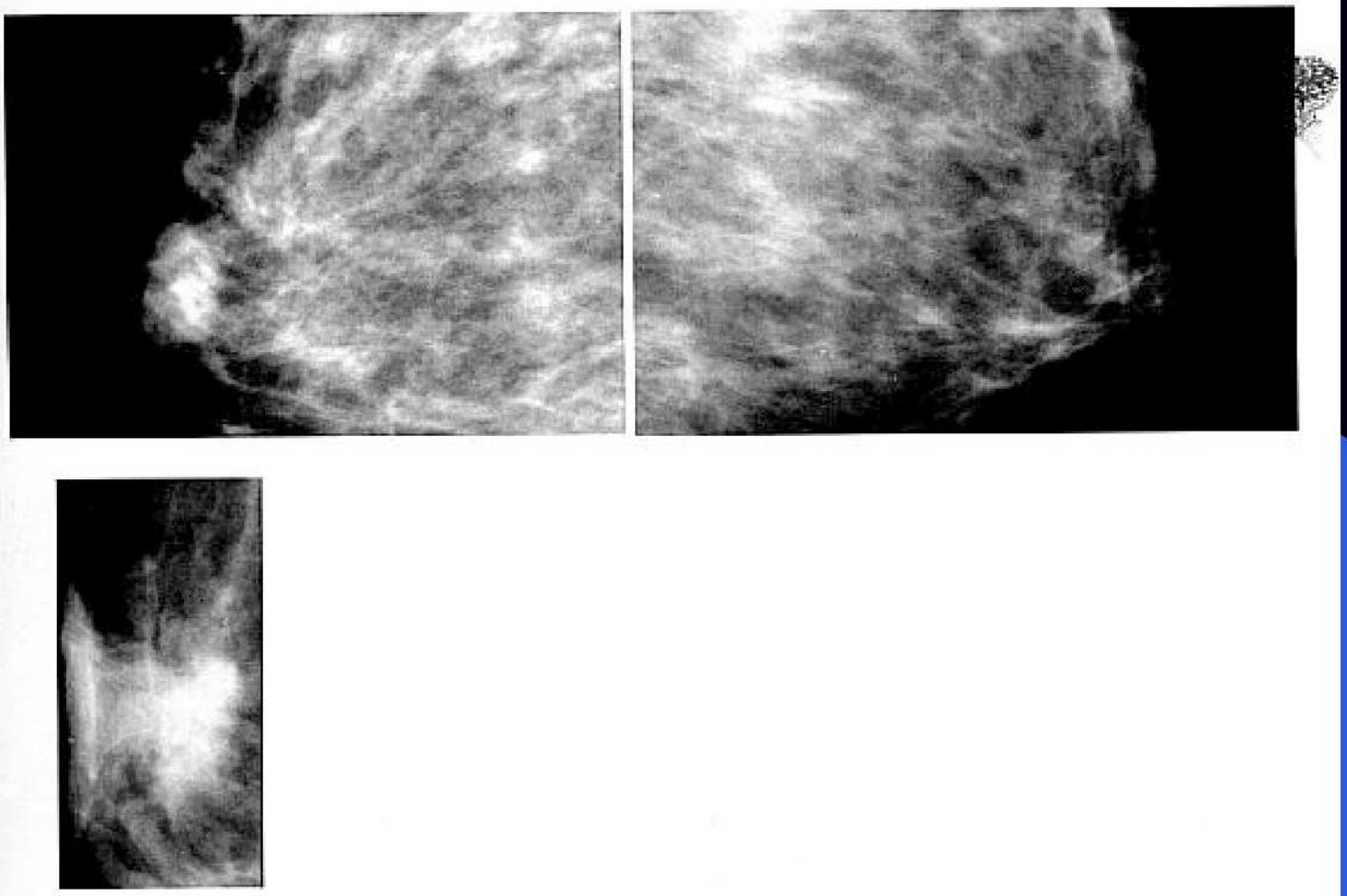

Spot compression

FREE
MAMMOGRAM
PLACE BOOBS HERE

Kasutatud kirjandus

- **L. Tabar** “Diagnosis and in-depth differential diagnosis of breast cancer” (European Seminars of Diagnostic and Interventional Radiology, Turku, Finland 1996)
- **Shirley M. Long et al** “The Handbook of Mammography” 4-th Edition, Mammography Consulting Services Ltd., Canada, 2000
- **Audrey K. Tucker et al** “Textbook of Mammography” Second Edition, Churchill Livingstone, 2001
- **http://www.auntminnie.com**