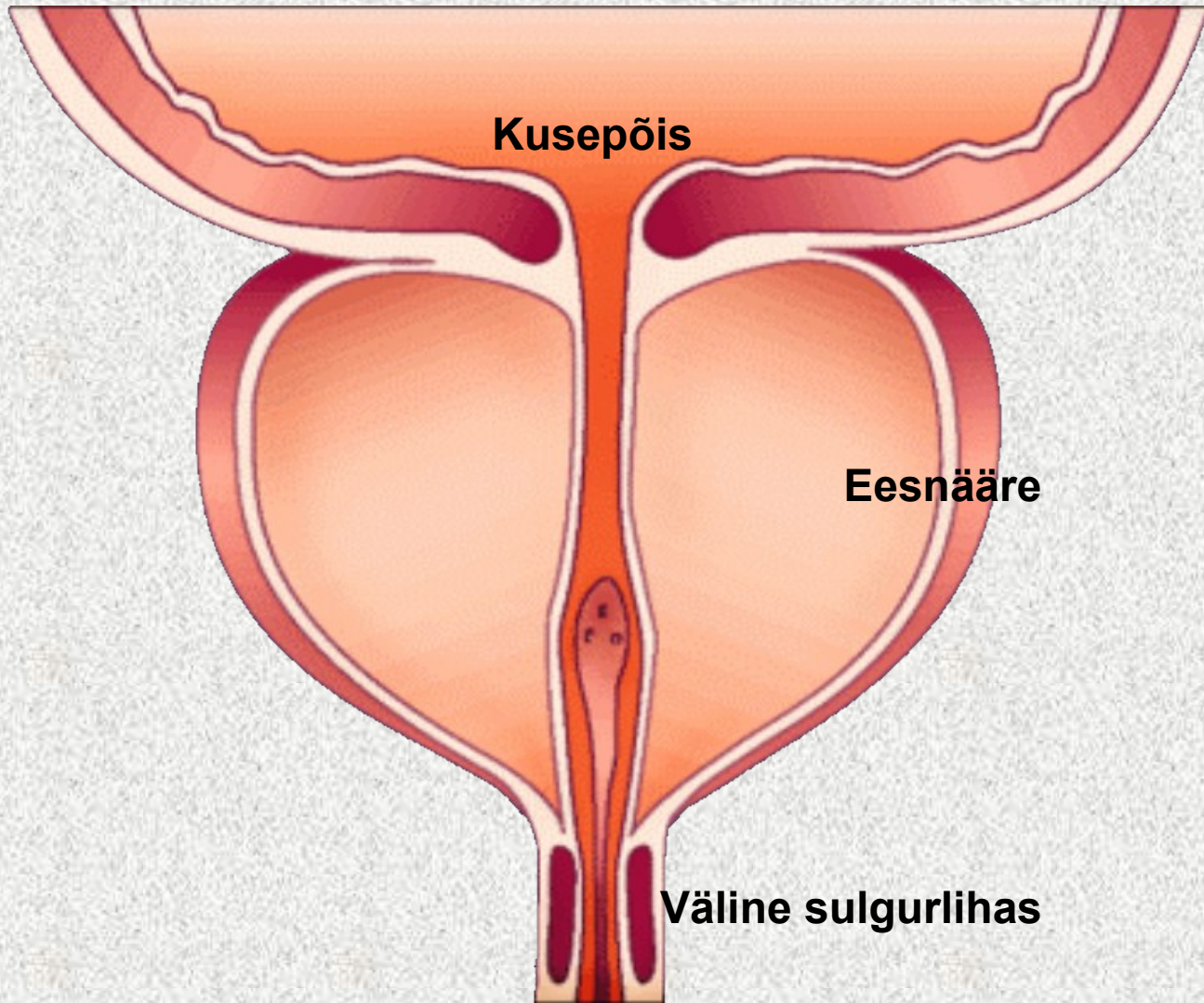
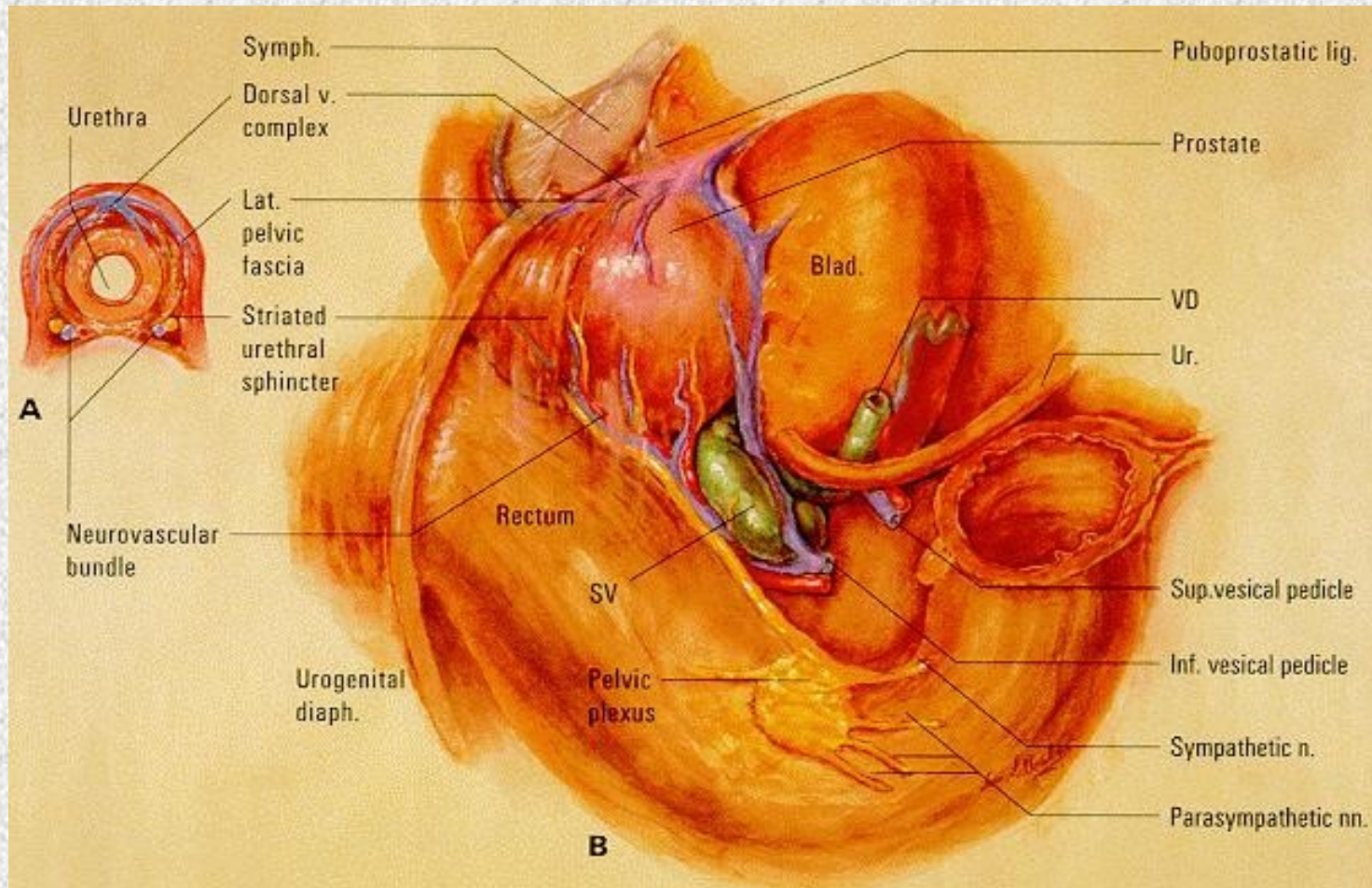


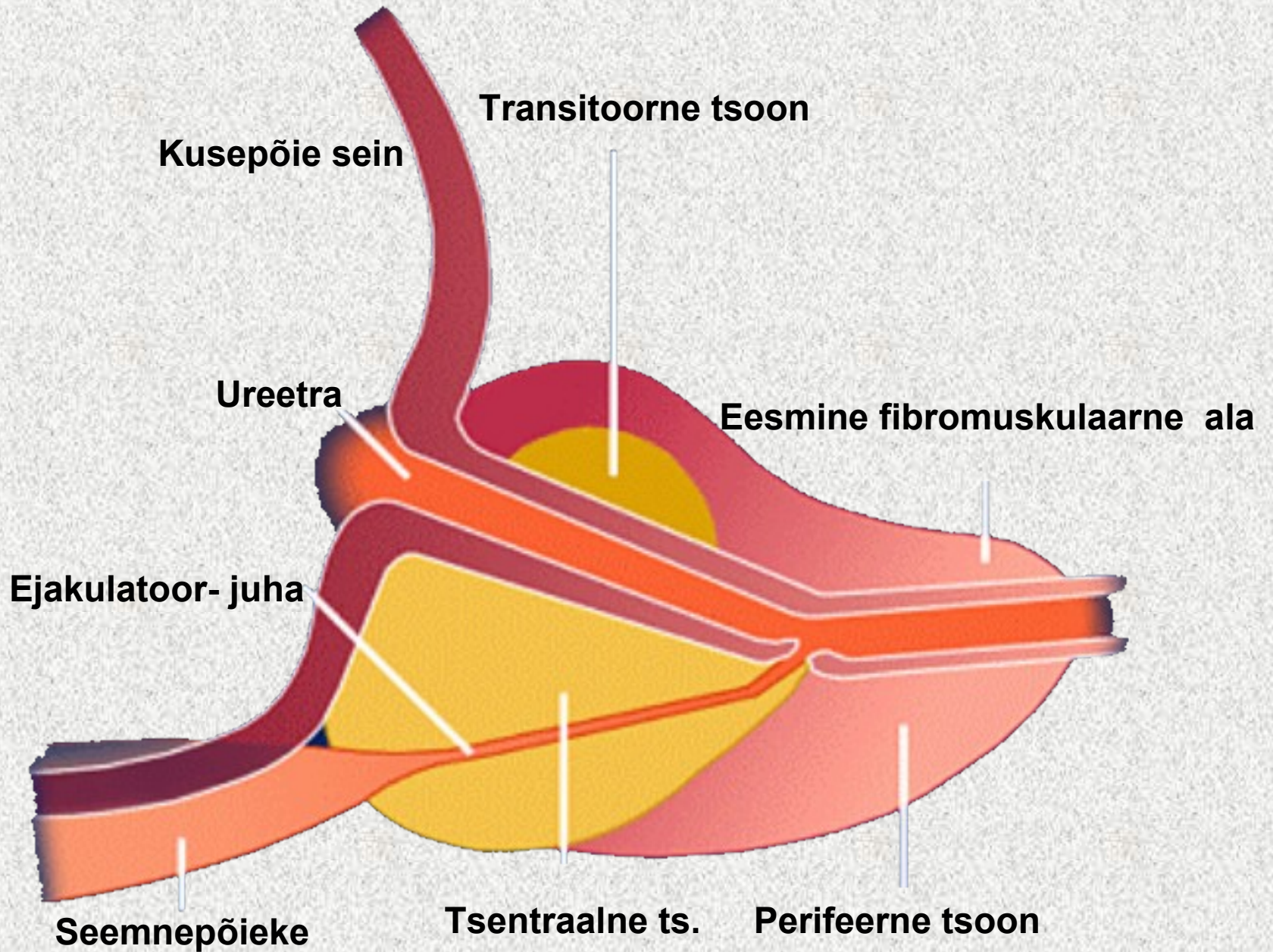
Eesnäärme kliiniline anatoomia

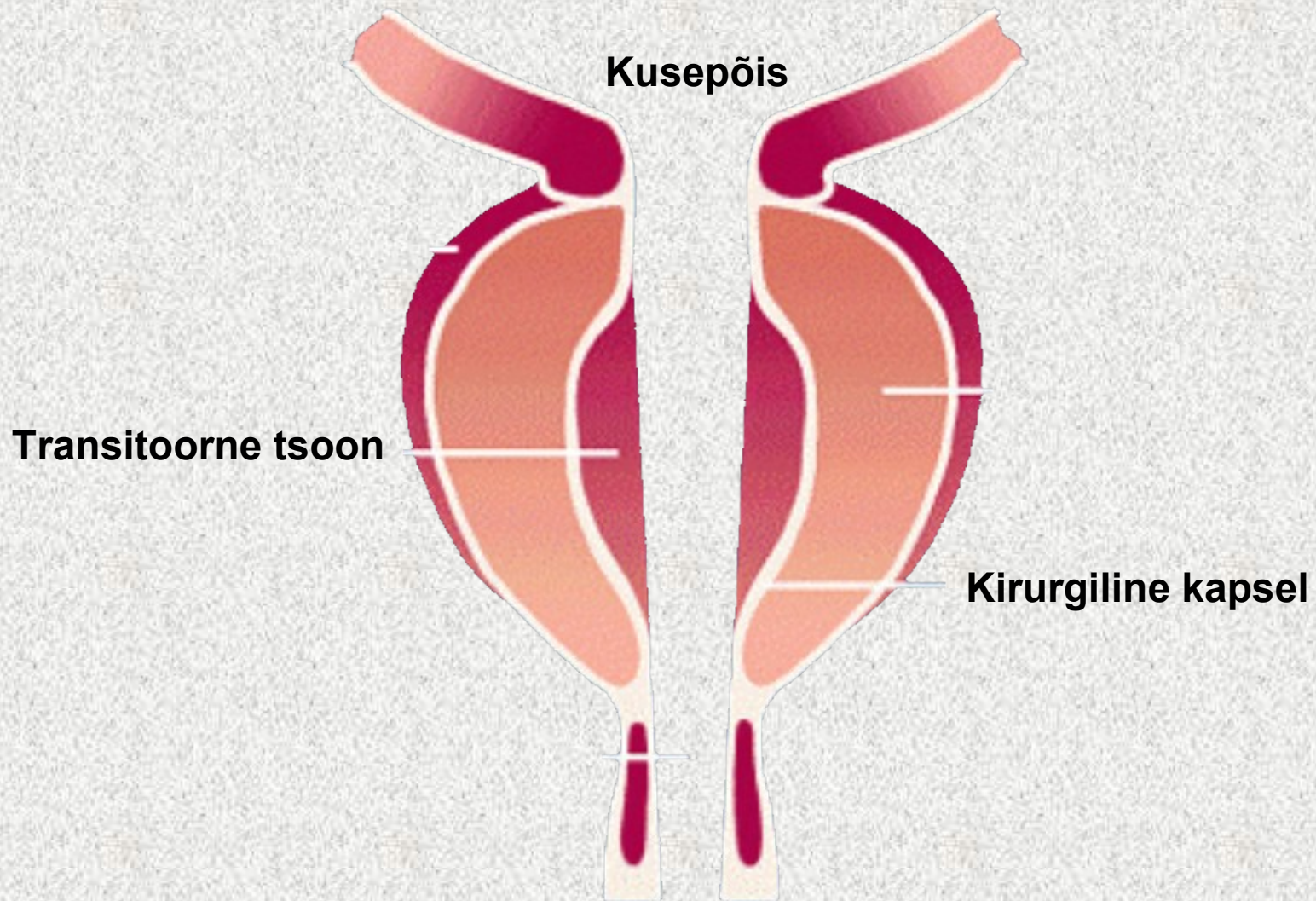
Dr. Tanel Muul
SA TÜ Kliinikum
uroloogia ja neerusiirdamise osakond

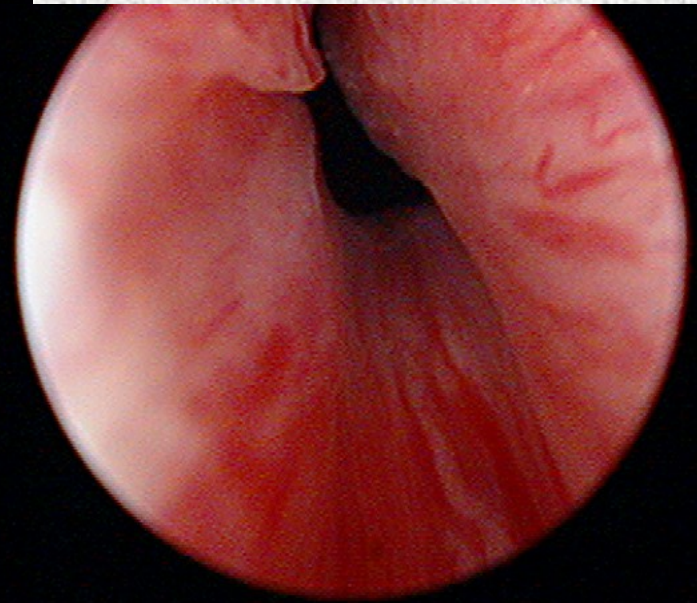

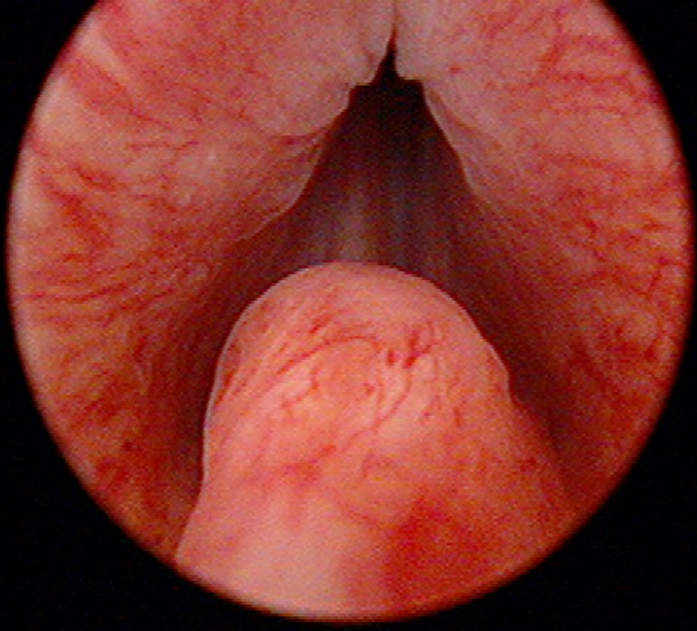


Eesnäärme anatoomia





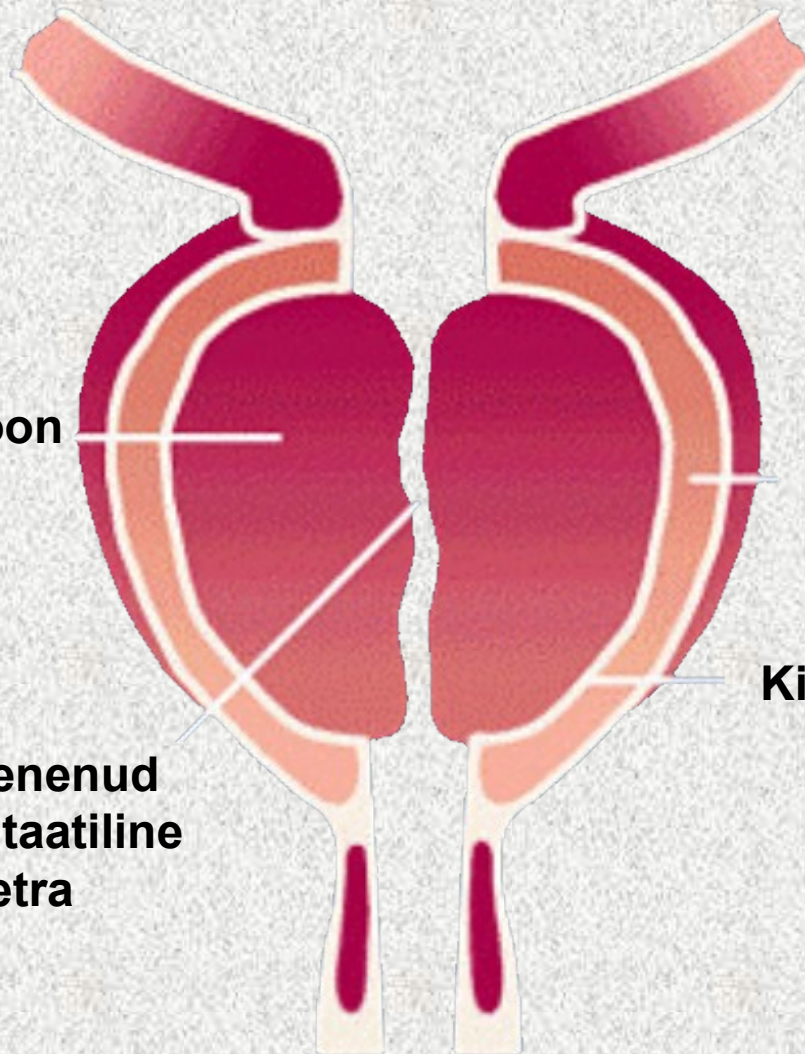


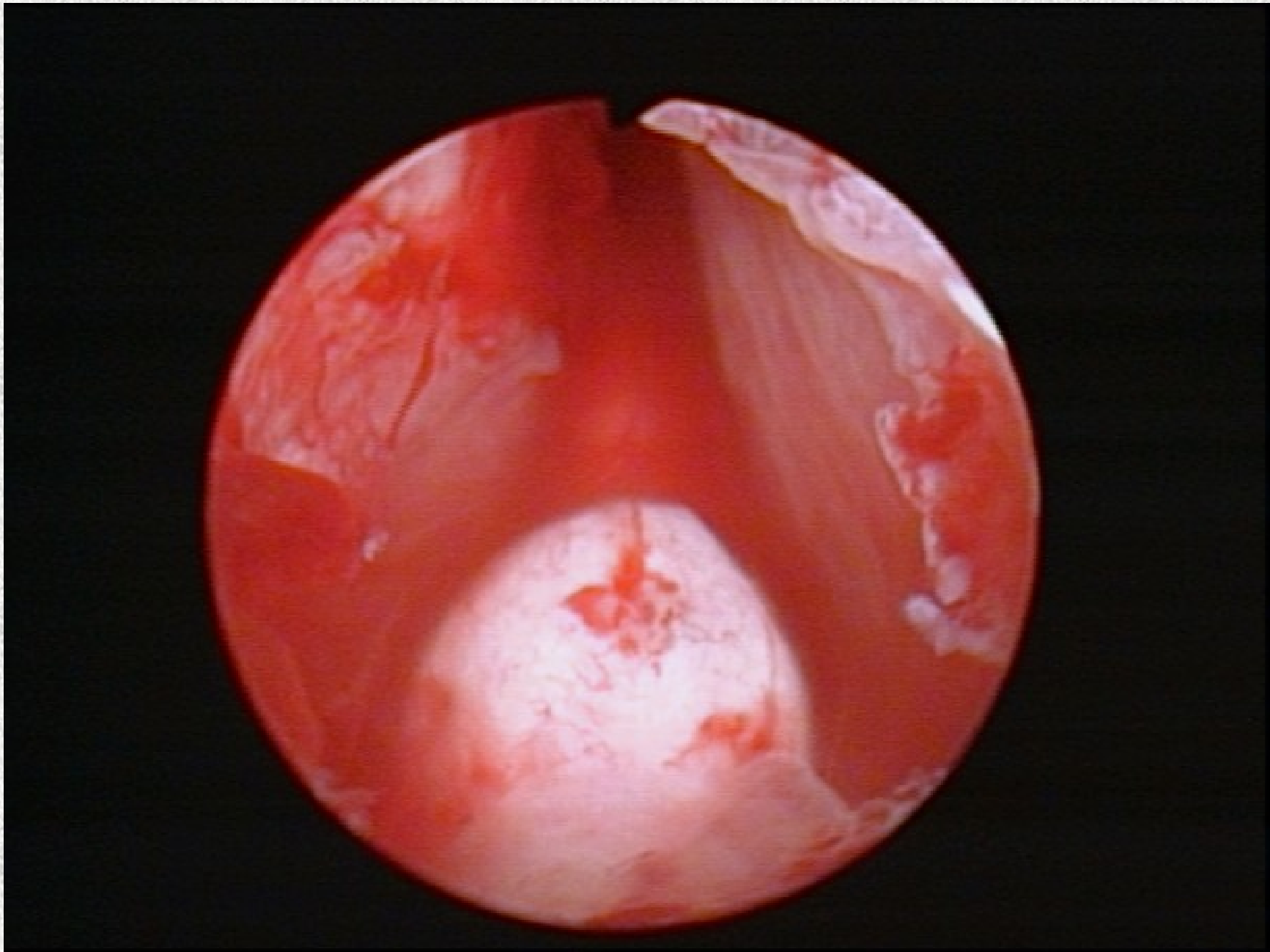


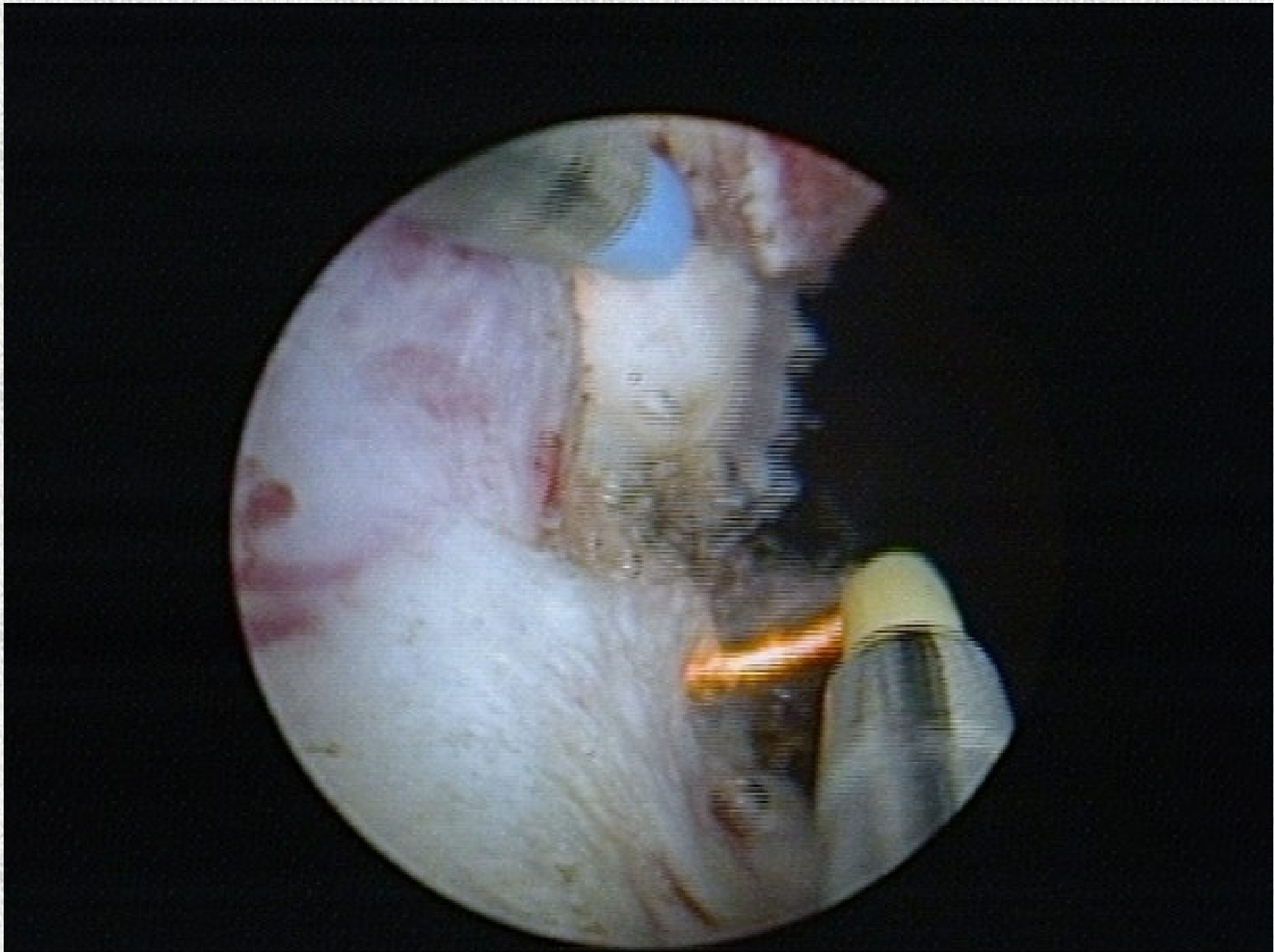
Transitoorne tsoon

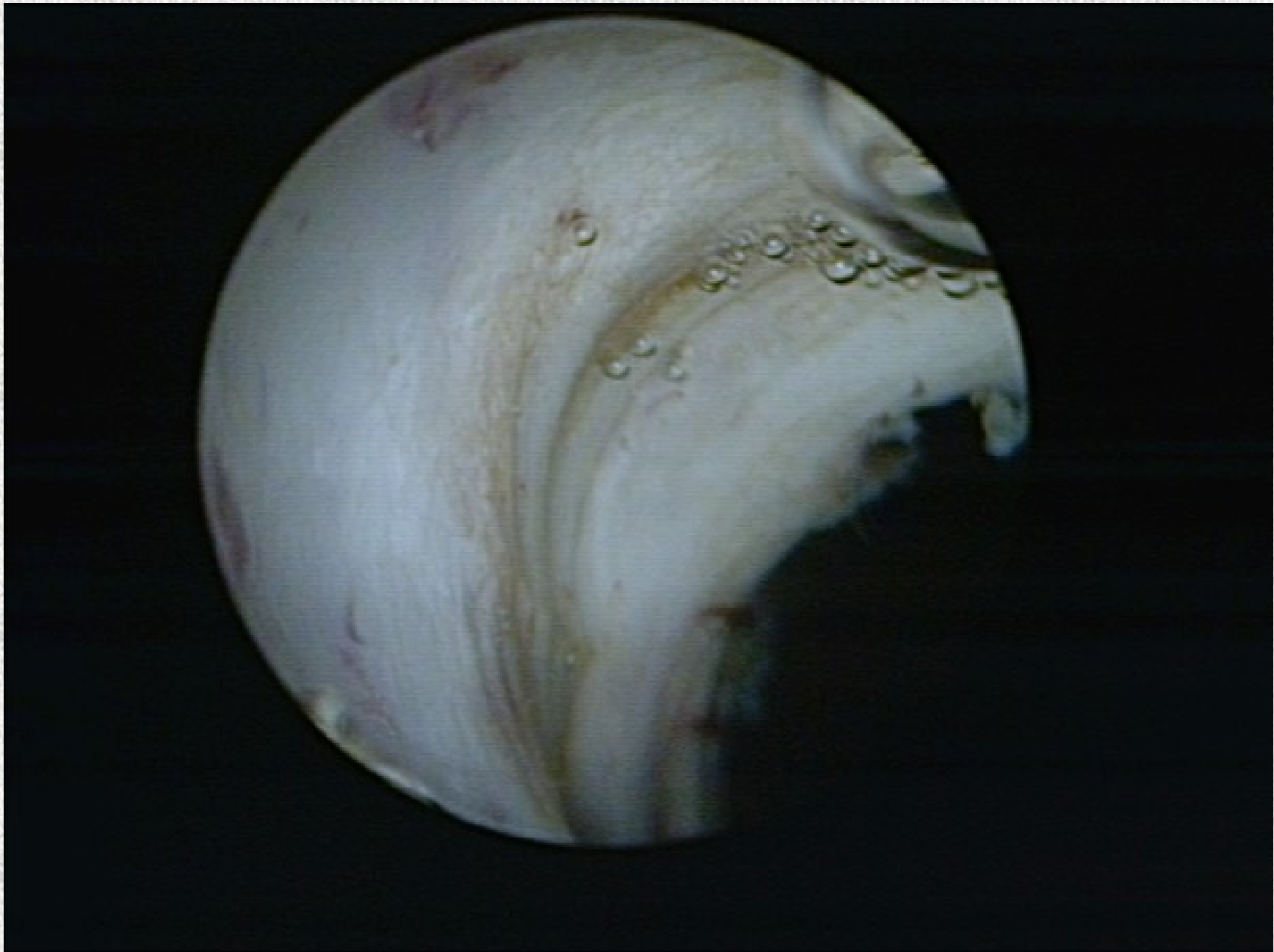**Kitsenenud
prostaatiline
ureetra**

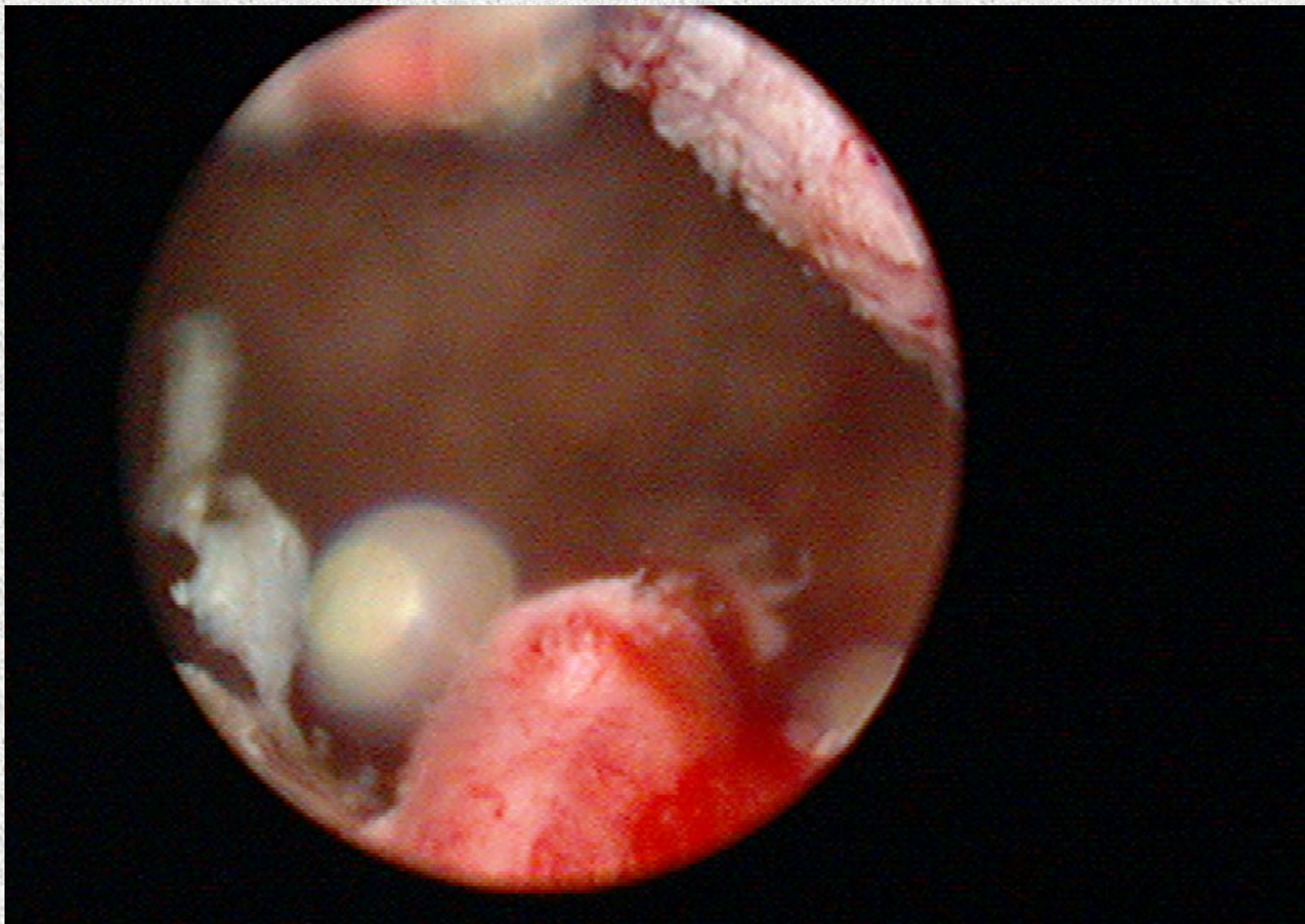
Kirurgiline kapsel



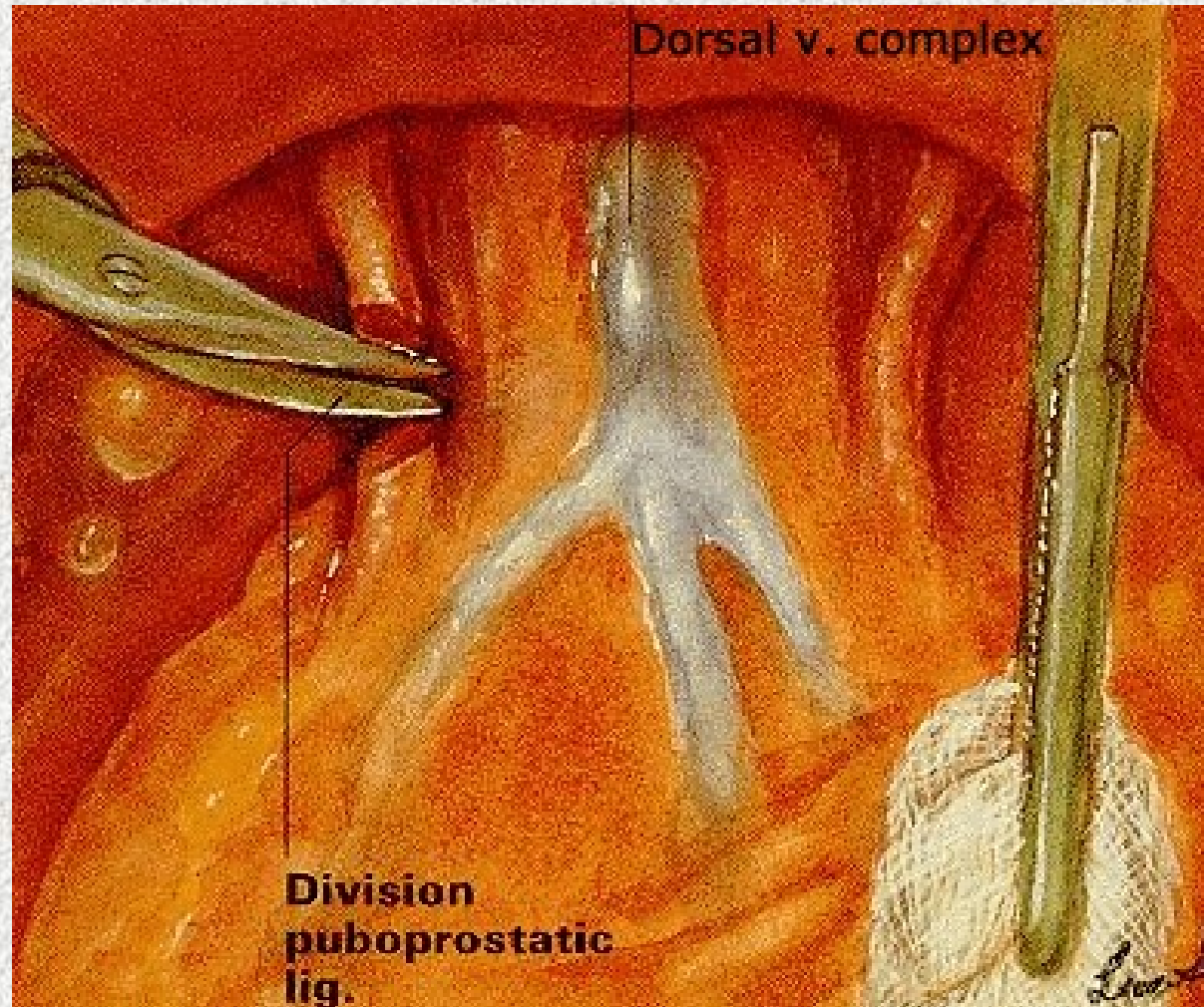








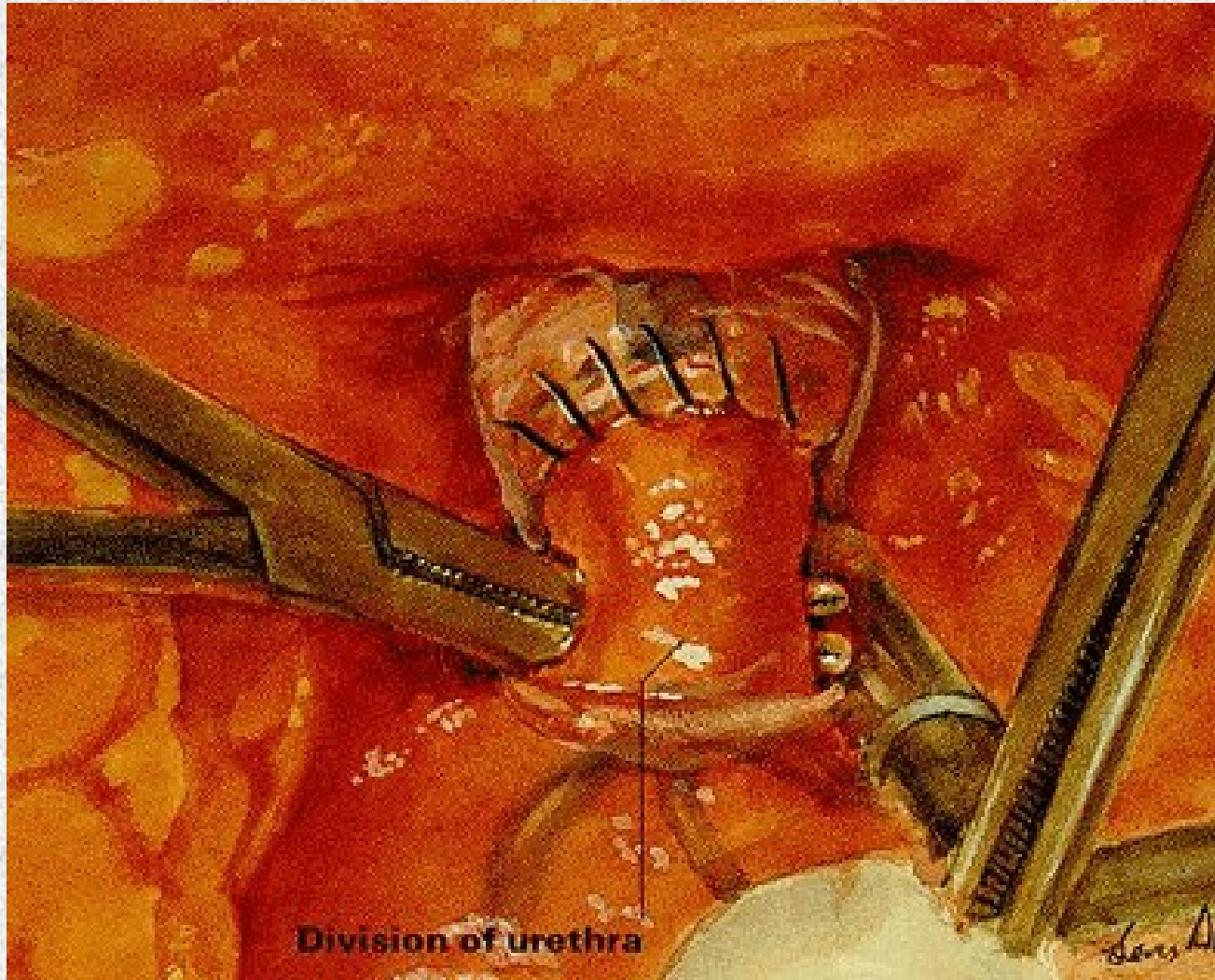Puboprostaatiliste ligamentide läbimine



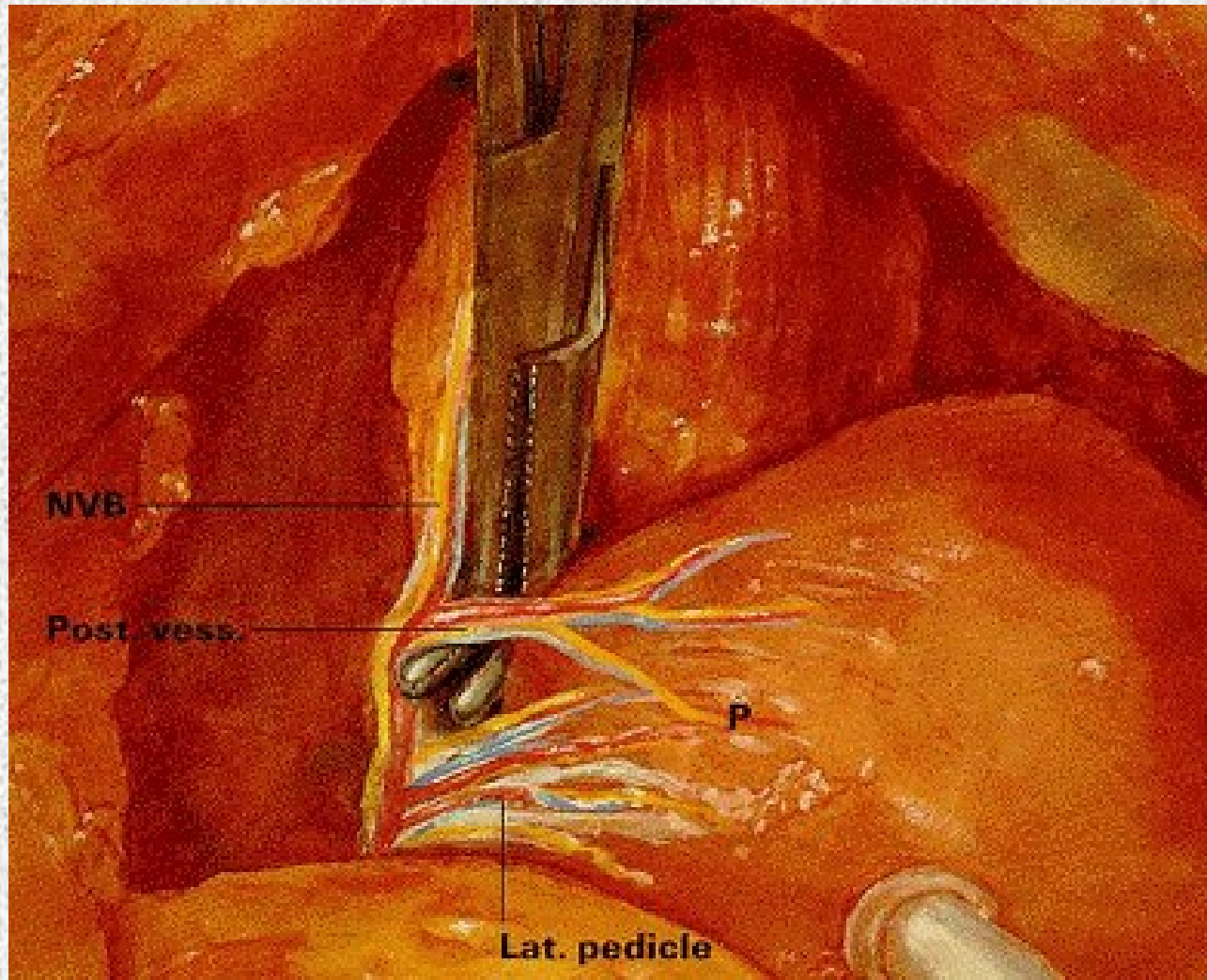
Dorsaalveenide ligeerimine



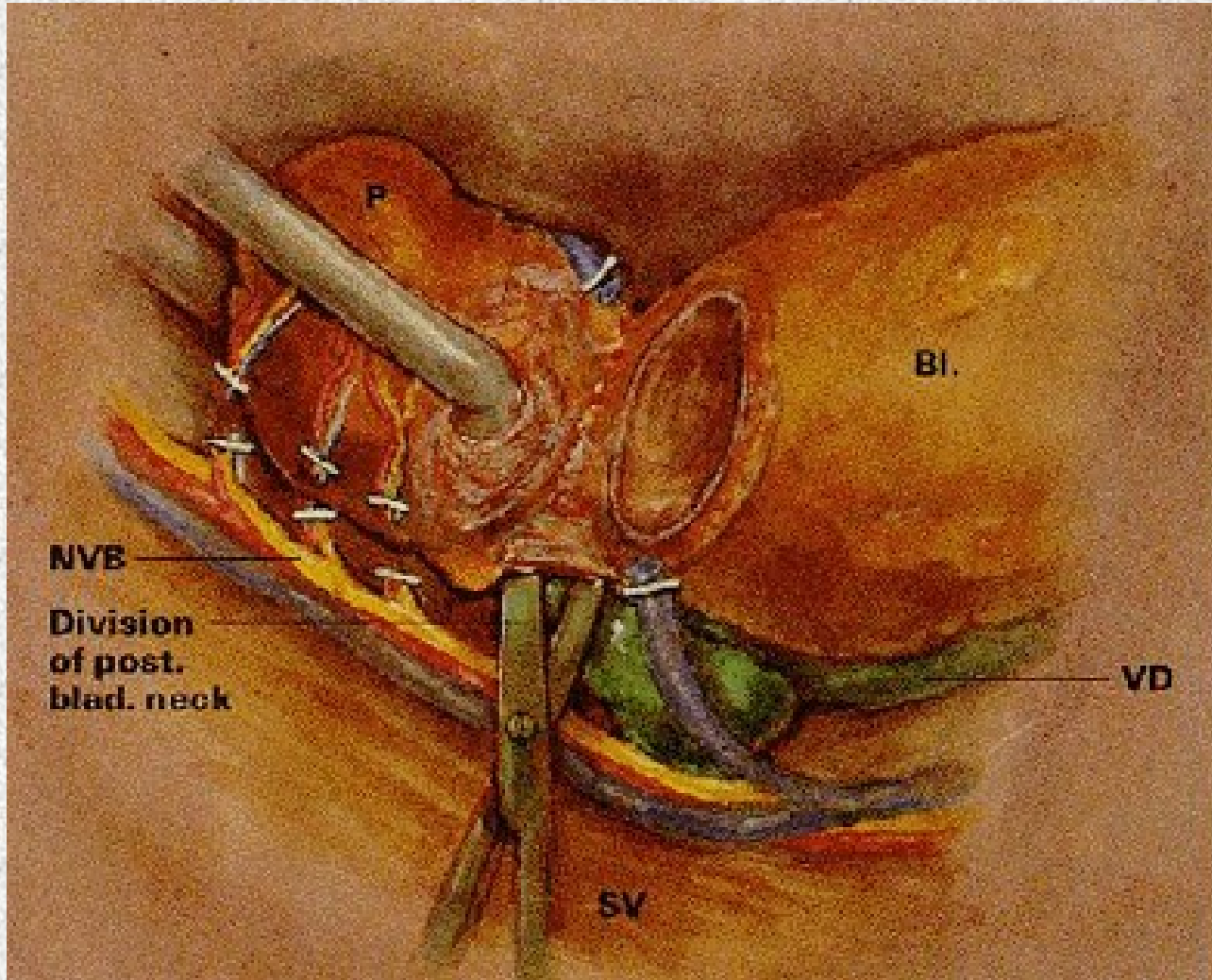
Uretra mobiliseerimine



Lateraalse vaagna fastsia ja pedikli vabastamine



Põiekaela vabastamine



Prostata eemaldatud.

