^{99m}Tc -MIBI brain SPECT in the diagnosis and follow up of gliomas

Lithuania Kaunas Medical University hospital
Nuclear Medicine department
Dr. N.Jurkienė, D.Vajauskas
*Neurosurgery department
*dr.A. Tamašauskas, dr. V. Deltuva

Introduction

- The incidence of primary brain tumors in Europe and United States is age-related and is just about 1-10 cases/ 100.000 persons.
- There are two main peaks of incidence: the former in childhood between 0 and 4 years, the latter in the elderly between 65 and 79 years
- In persons older than 20 y, gliomas compose more than 90% of primary intracranial tumors.
- About 25% of gliomas are low-grade astrocytomas.
- Most low-grade astrocytomas are not amenable to complete resection, and radiotherapy is the most effective no surgical therapy.
- Many low-grade gliomas convert to high-grade gliomas during follow-up.

Stiller CA, Parkin DM. Geographic and ethnic variations in the incidence of childhood cancer. Br Med Bull 1996; 52: 682-703.
Karatsu J, Ushio Y. Epidemiological study of primary intracranial tumours in eldery people. J Neurol Neurosurg Psychiatry 1997; 63: 116-118.
Stiller CA, Allen MB, Eatock EM. Childhood cancer in Britain: the National Registry of Childhood Tumours and incidence rates 1978- 1987. Eur J Cancer 1995; 31A: 2028-2034.
Herfarth KK, Gutwein S, Debus J. Postoperative radiotherapy of astrocytomas. *Semin Surg Oncol.* 2001;20:13–23.

Brain tumors in Lithuania

- 1,8% of all tumors
- 85% adults, 15%children
- 400-450 newly diagnosed patients with brain tumors each year (220-250 patients – malignant tumor)

Incidence:

- malignant tumors of CNS- 6,4/100 000
- benign tumors of CNS- 5,3/ 100 000

WHO Classification Tumors of the Nervous System (2000)

Brain tumors are classified in relation to their cellular origin and immunophenotypic features

- Tumors of neuro-epithelial tissue
- Tumors of peripheral nerves
- Tumor of the meninges
- Lymphomas and haemopoietic neoplasm's
- Germ cells tumours
- Tumors of the sellar region
- Metastatic tumors

- Pituitary fosse tumors
- Adenomas
- Tumors of the posterior hypophysis
- Other

Tumors of neuroepithelial tissue

- Astrocytic tumors
- Oligodendroglial tumors
- Mixed tumors
- Choroid plexus tumors
- Glial tumors of uncertain origin
- Neuronal and neuronal–glial tumors
- Neuroblastic tumors
- Pineal parenchyma tumors
- Embryonic tumors

Astrocytic tumors – CNS glioma

- Most common primary brain tumors
- 33-45% of all brain tumors
  - 50-80% glioblastomas
  - 20-40% anaplastic astrocytomas
  - 10-15% low grade astrocytomas

CNS glioma

Astrocytomas are classified into four grades of malignancy according to their histopathological characteristic

Criteria – histopathological characteristics:

- Mitoses
- Nuclear atypical
- Endothelial proliferation
- Necrosis

- I° low grade
- II° low grade -1 criteria
- III° high grade – 2 criteria
- IV° high grade -3,4 criteria

Radiological diagnosis of gliomas

Anatomical imaging

- CT
- MR

Functional imaging

- SPECT
- PET
- MRI spectroscopy

Anatomical + functional imaging

- SPECT-CT
- PET-CT

CT and/or MR Imaging of gliomas

Advantages

- allow exact localization
- define extension of tumor mass
- CT remains most widely used due to its aviability and lower cost
- CT detect over 90% of brain tumors
- CT scans has shorter scanning time than MRI
- CT is more sensitive for detecting acute hemorage, calcifications, and bony injuries
- MRI provides much greater anatomic detail in multiple planes
- MRI is especialy useful for visualizing skull base, brain steam, and posterior fosa tumors

Limitations of Structural MR/CT Imaging

- Limited prognostic value
- Poor indicator of true extent of tumor, especially in high grade lesions
- Post-treatment changes (surgical, radiation) limit capability to detect tumor recurrence
- Overlap in imaging appearance among tumor types and between tumors and non-neoplastic lesions, with potential implications for treatment approach
- Brain regions already infiltrated by tumor cells may show no contrast enhancement on MRI or CT scans.
- Conventional MRI scans often fail to distinguish recurrent tumor from radiation injury or necrosis, because both cause disturbances of the blood– brain barrier (BBB) leading to nonspecific contrast-medium enhancement. (BBB disruption occurs in radiation necrosis).

Byrne TN. Imaging of gliomas. Semin Oncol 1994;21:162-171.
Leeds NE, Jackson EF. Current imaging techniques for the evaluation of brain neoplasms. Curr Opin Oncol 1994:6:254-261.
Dooms GC, Hecht S, Brant-Zawadzki M, et al. Brain radiation lesions: MR imaging. *Radiology 1986;158:149-155.* 5. Di Ghiro G, Oldfield E, Wright Mosskin S, Ericson K, Hindmarsh T, et al. Positron emission tomography compared with magnetic resonance imaging and computed tomography in supratentorial gliomas using multiple stereo tactic biopsies as reference. Acta Radial 1989:30:225-232.

CT and/or MR Imaging of gliomas

Exceptions

Proton magnetic resonance spectroscopy.

- You need- MRI system equipped with spectroscopy package.
- You can get- equivalent values of diagnostic parameters in differentiating tumor recurrence and radiation effects as ^{99m}Tc-MIBI brain SPECT.

Disadvantages:

- Voxel size may be larger than lesion. Irregularly shaped lesions may not conform to voxel margins.

Palumbo B, Lupattelli M et al. Association of 99mTc-MIBI brain SPECT and proton magnetic resonance spectroscopy (1H-MRS) to assess glioma recurrence after radiotherapy. Q J Nucl Med Mol Imaging. 2006 Mar;50(1):88-93.

^{99m}Tc – MIBI SPECT in oncology

- It is minimally taken by the normal brain due to its almost total exclusion by the blood brain barrier (BBB).
- ^{99m}Tc – MIBI is taken up by cancer cells by an active transport mechanism and stored in the mitochondria and cytoplasm.
- As more mitochondria occur in metabolically active cancer cells than in surrounding normal tissue, ^{99m}Tc – MIBI accumulates in cancer cells.
- Maximal cellular concentrations of ^{99m}Tc – MIBI ranging between 5% to 28%of the external medium activity in the tumor cell lines. The maximum level is after 1 h., the time to half maximum is 10 min.

Buscombe J, Hill J, Parbho S, Scintimammography a guide to good practice, 1998: 26-27.
Delmon-Moigeon LI, Piwnica-Worms D et all. Uptake of the cation hexakis (2-methoxyisobutylisonitrile) technetium-99m by humancarcinoma cell lines in vitro.Canser Res 1990;50:2198-2202.

Brain SPECT Radiopharmaceuticals

- ^{99m}Tc MIBI or tetrofosmin (uptake in III°,IV° gliomas)
- ^{201}Tl (uptake in III°,IV° gliomas)
- ^{123}IIMT (uptake in I°,II°,III°,IV° gliomas)

Normal uptake ^{99m}Tc – MIBI

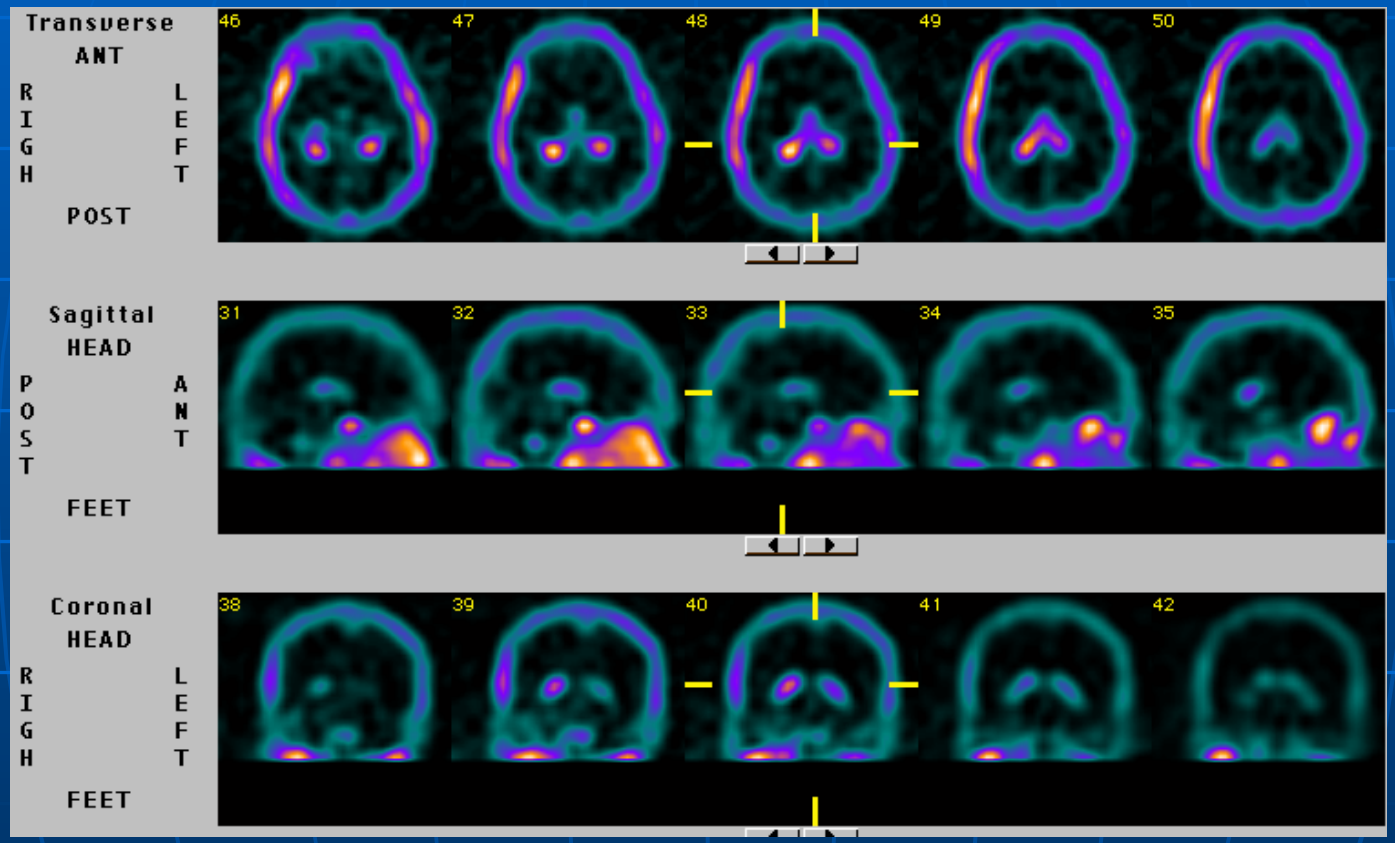

Limitations?

- 99mTc-MIBI uptake in normal plexus chorioideus and pituitary gland.
  - Limits assessment of deeply-seated tumours
  - Gives anatomical landmarks for tumour localization

Indications ^{99m}Tc – MIBI brain SPECT for gliomas

- Determination of hystological grade
- Differentiation of viable tumor from oedema surrouding tumor
- Evaluation response to therapy
- Differentiation of recurrent and persistent tumor from radiation necrosis

IMAGING PROTOCOL

- Injection of 500-700 MBq ^{99m}Tc – MIBI
- Imaging within 30-60 minutes after injection
- SPECT with low energy, high resolution collimators (we use low energy collimators)
- 360 arc of rotation
- 64X64 pixels image size, acquisition time of 30s/ frame
- Zoom factor of 1.78

Clinical protocol ^{99m}Tc – MIBI brain SPECT of gliomas

- I - examination 1-4 days before surgery
- II - examination 9-15 days after surgery
- III - examination 1-2 days after radiation terapy
- IV – examination after 3-4 months after treatment, or earlier if there are indications

Clinical protocol ^{99m}Tc – MIBI brain SPECT

For grade II glioma:

- Mean delay to recurence is 5 years after initial diagnosis
- It is advisible to perform ^{99m}Tc – MIBI SPECT

as part of conventional neuromorphological exploration conducted every year

For grade III glioma:

- Mean delay to recurence is shorter- approximately 3 years after initial diagnosis
- For these patiens ^{99m}Tc – MIBI SPECT could be included in the follow-up with the neurological examination and neuromorphology imaging generaly performed every 4 month

Florence Prigent –Le Jeune et al. Sestamibi technetium-99m brain single-photon emission computed tomography to identify recurrent glioma in adults: 201 studies. Journal of Neuro-Oncology (2006) 77: 177–183

^{99m}Tc MIBI brain SPECT before surgery

- Determination of hystological grade

^{99m}Tc MIBI brain SPECT before surgery

Glioblastoma (IV)

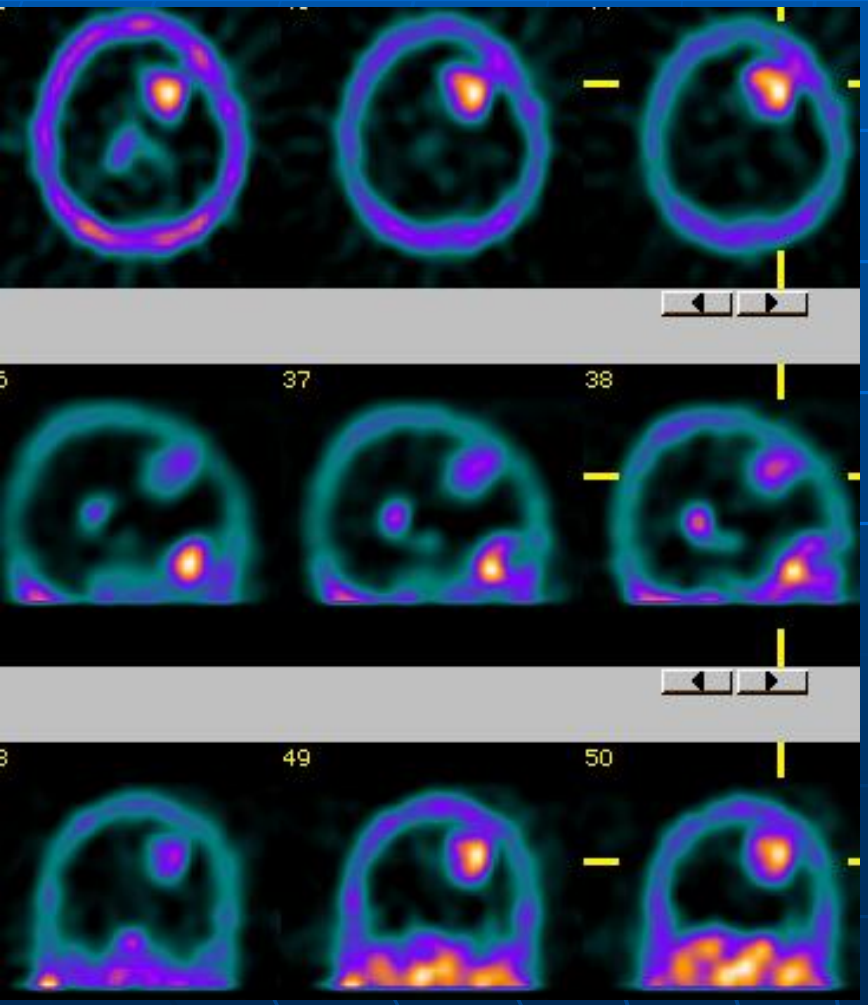

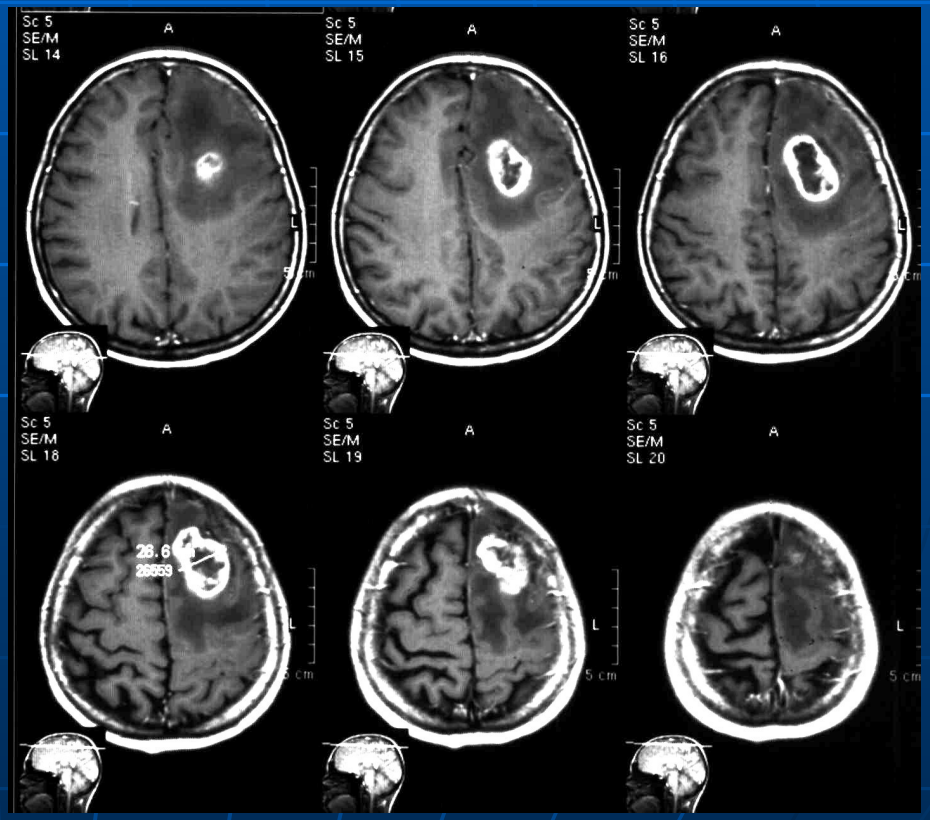

^{99m}Tc MIBI brain SPECT before surgery

Astrocytoma III

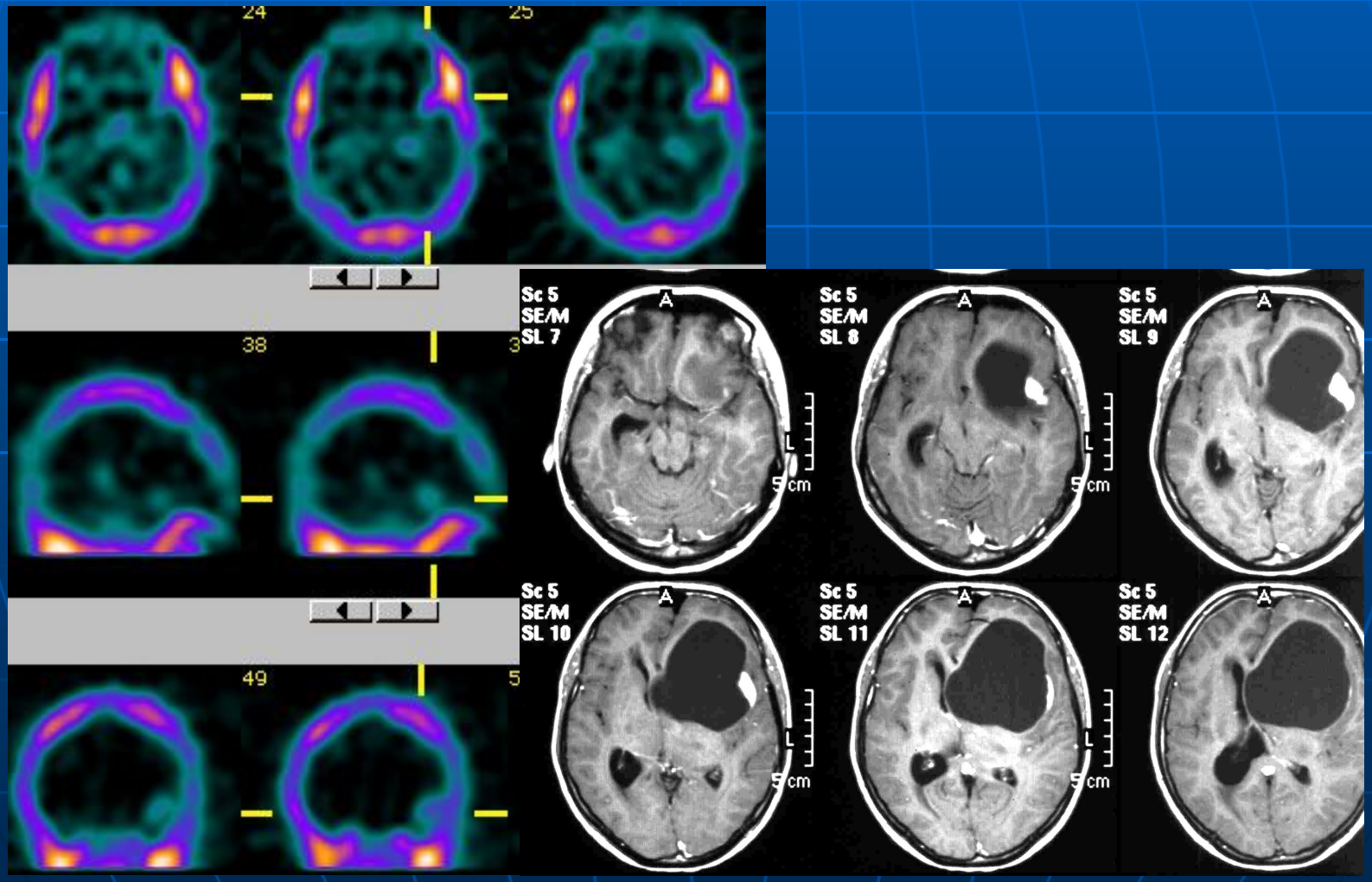

^{99m}Tc MIBI brain SPECT before surgery

Oligodendrogioma (II)

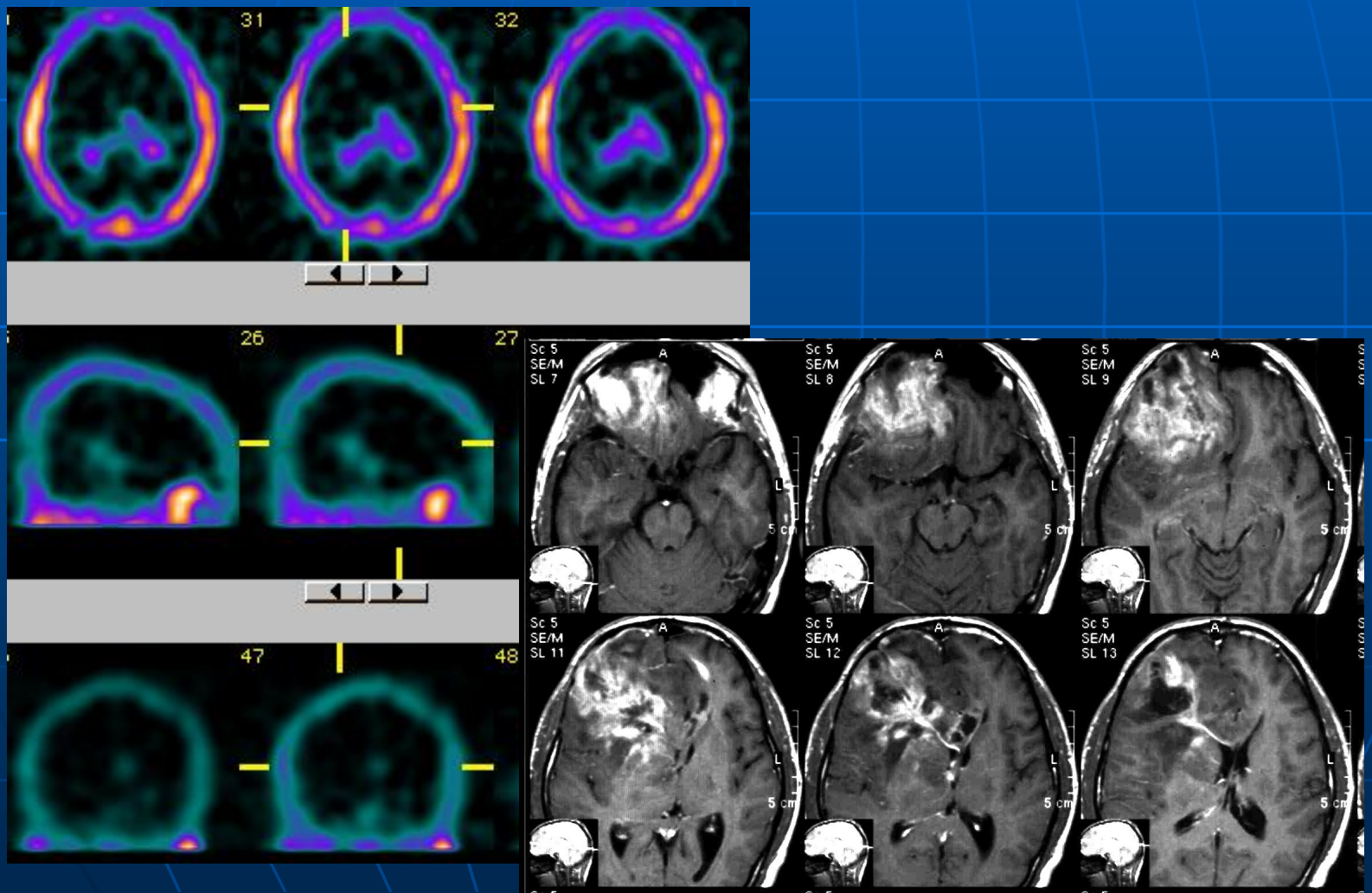

^{99m}Tc MIBI brain SPECT before surgery
Differentiation difficulties

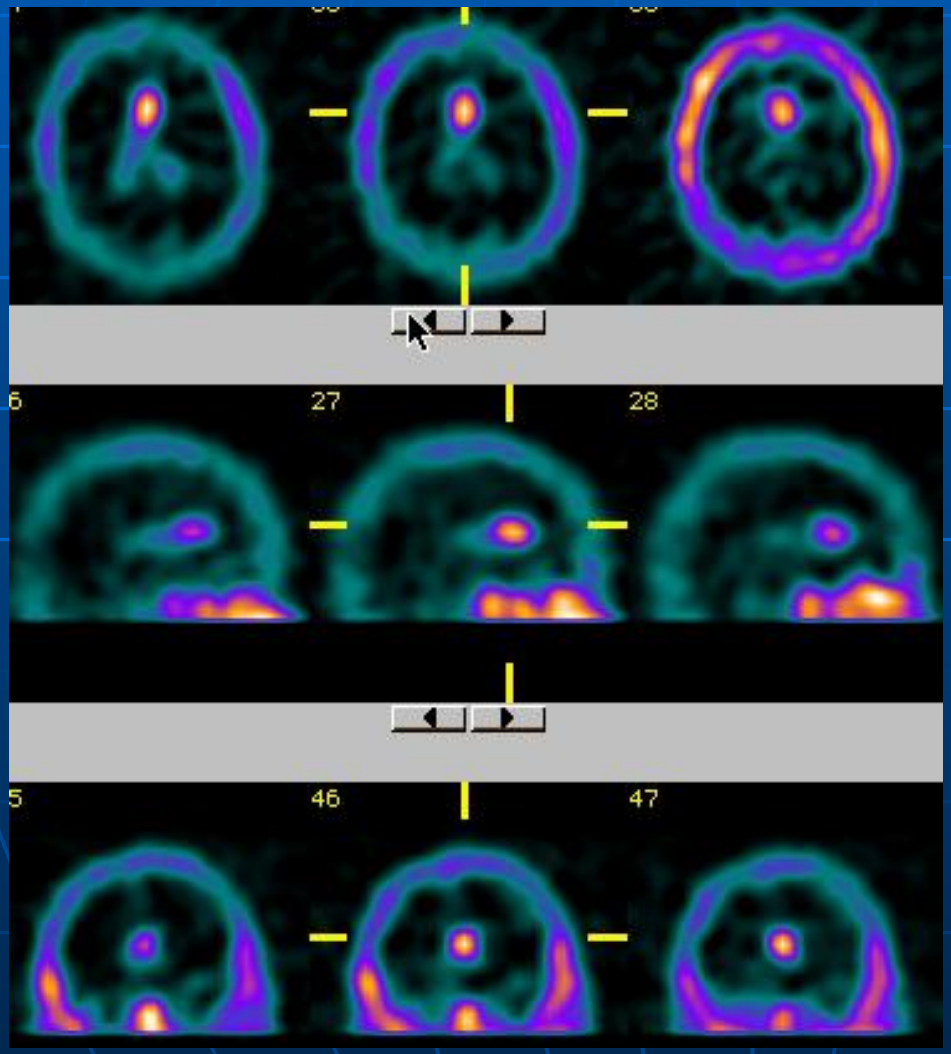

Lymphoma

^{99m}Tc MIBI brain SPECT before surgery Differentiation difficulties

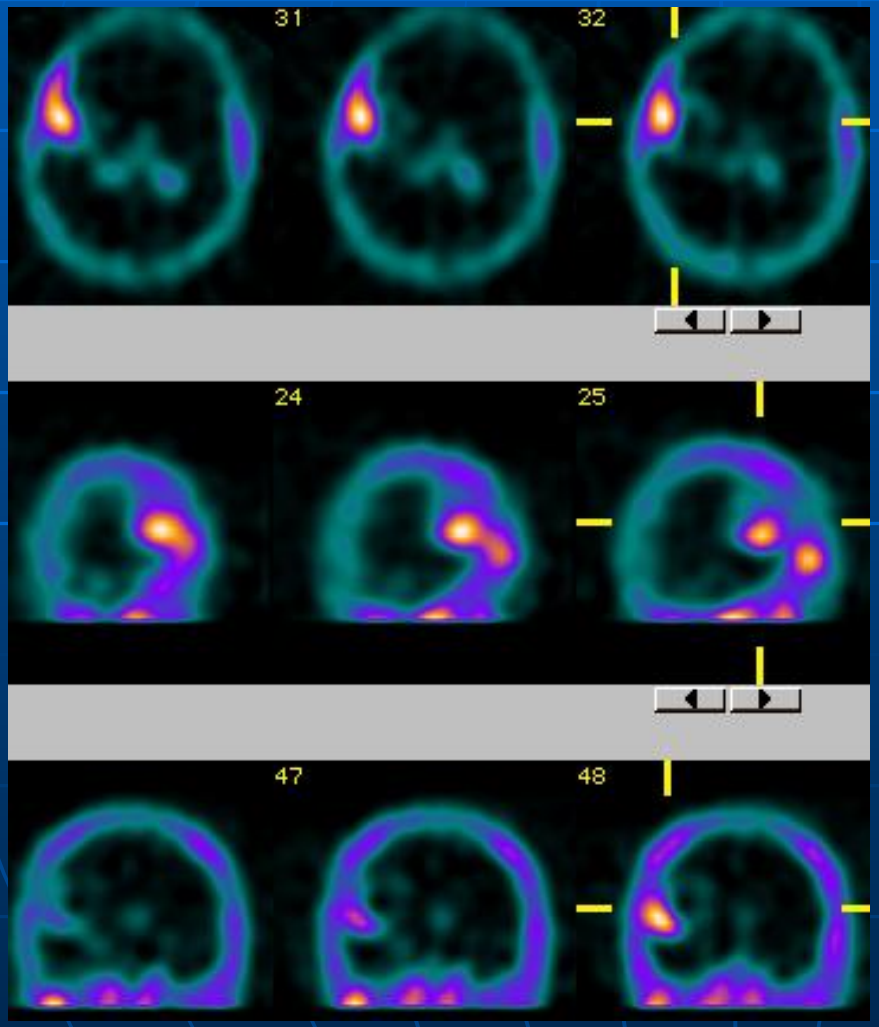

Metastasis

^{99m}Tc MIBI brain SPECT before and after surgery

- Estimation of postoperative results after removal of high grade gliomas
- Prognosis

^{99m}Tc MIBI brain SPECT before and after surgery

1 day before surgery

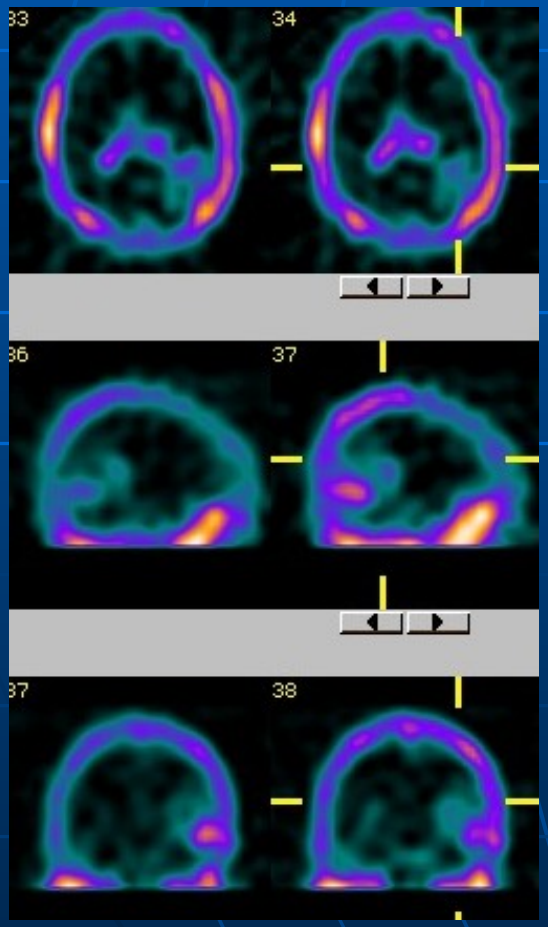

10 days after surgery

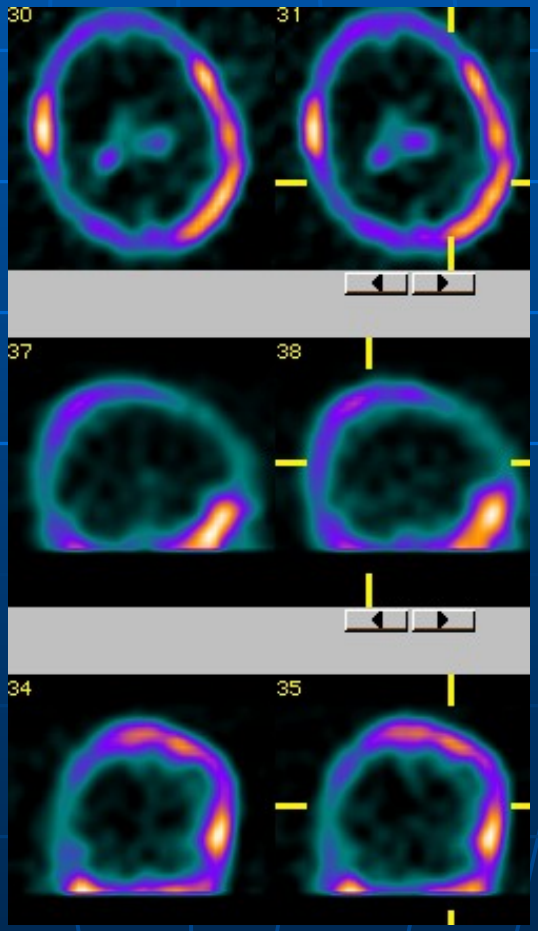

Glioblastoma (IV)

^{99m}Tc MIBI brain SPECT before and after surgery

1 day before surgery 11 days after surgery

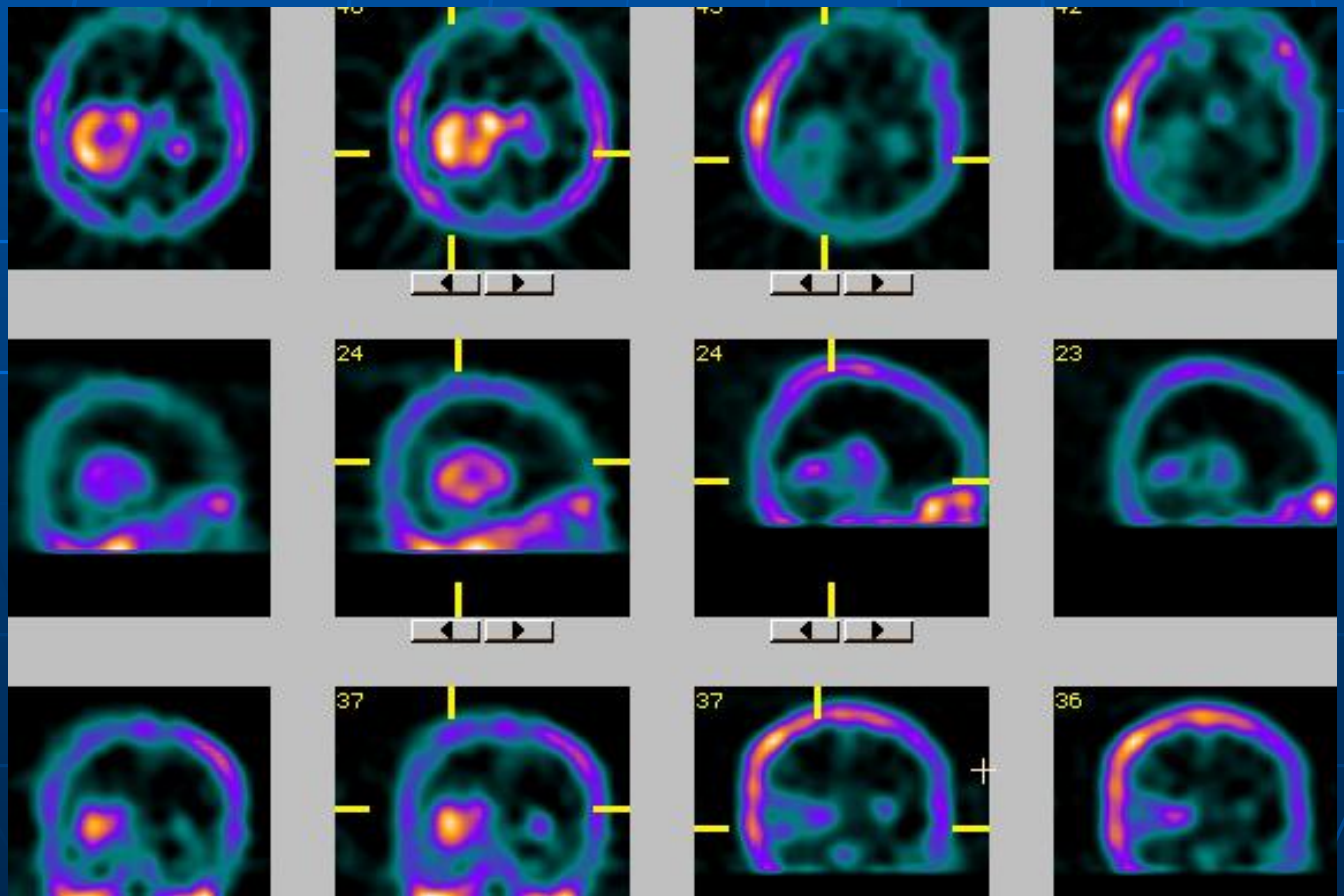

Gliosarcoma (IV)

^{99m}Tc MIBI brain SPECT before and after surgery

3 days before surgery

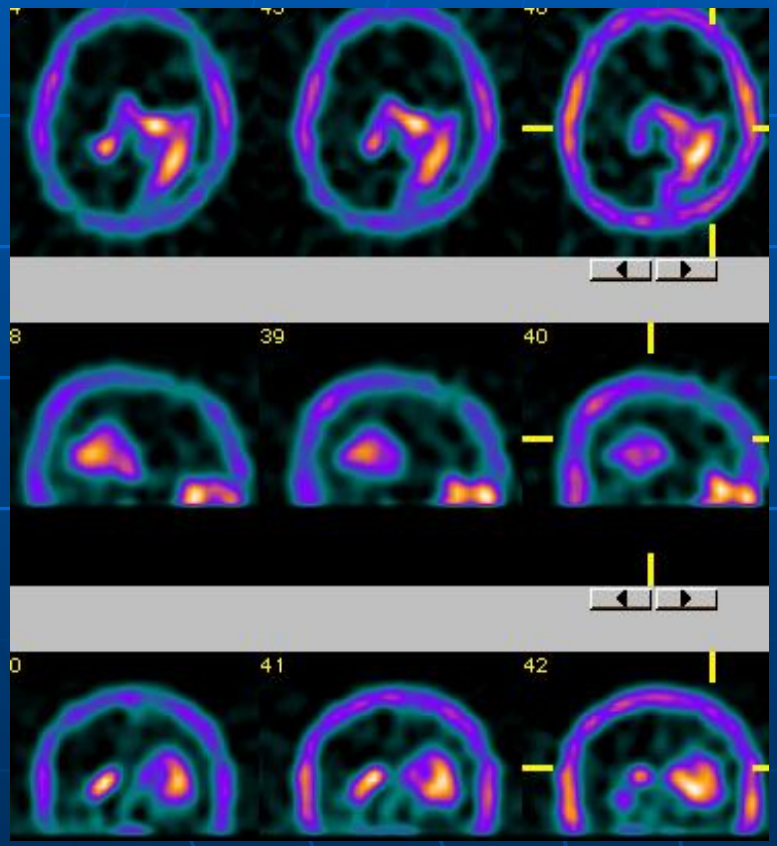

Glioblastoma (IV)

10 days after surgery

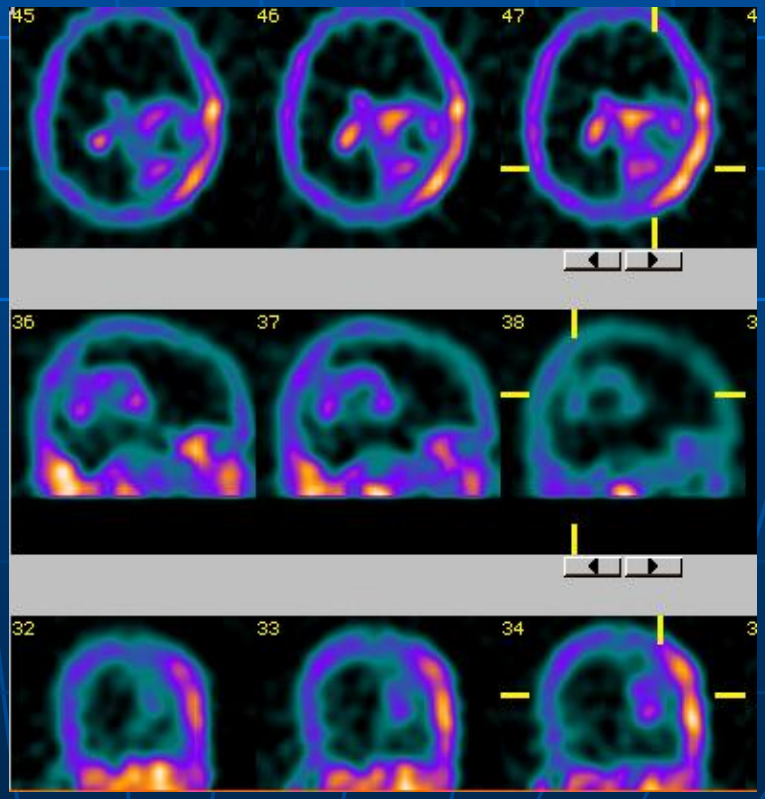

^{99m}Tc MIBI brain SPECT before and after surgery

2 days before surgery

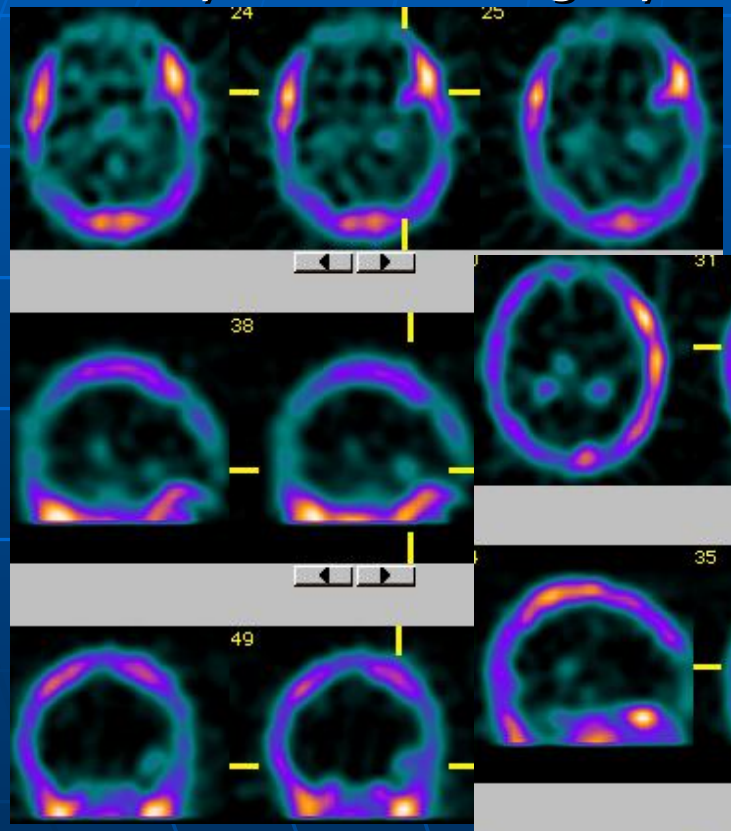

Astrocytoma III

10 days after surgery

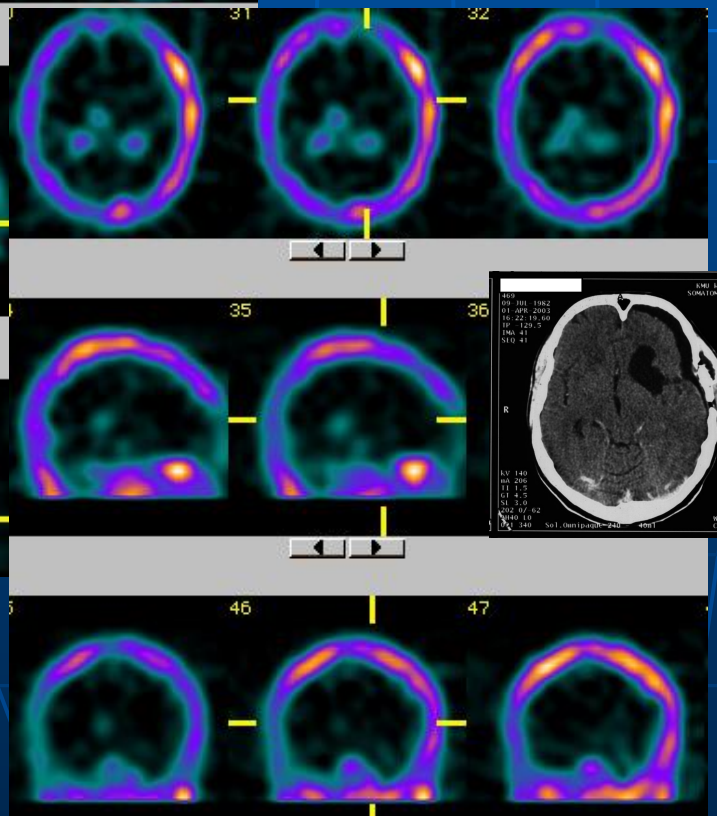

CECT after surgery

^{99m}Tc MIBI brain SPECT before and after surgery

Astrocytoma II

3 days before surgery

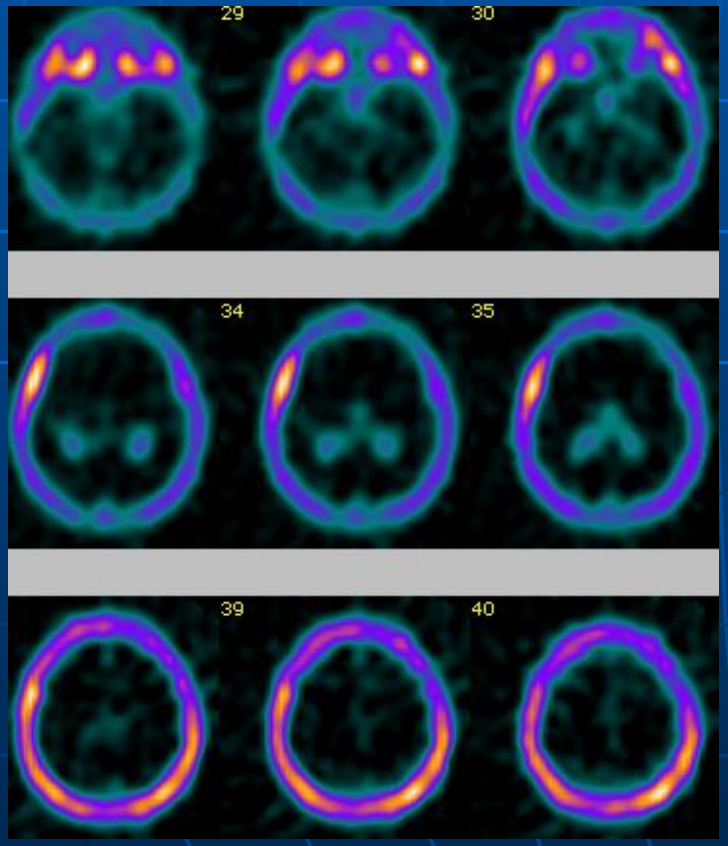

9 days after surgery

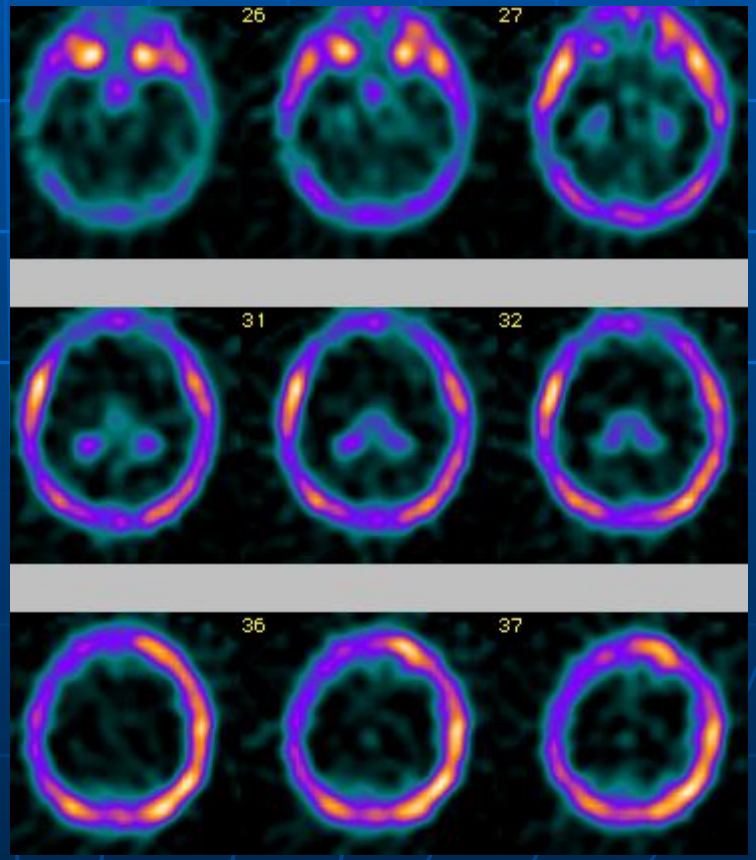

^{99m}Tc MIBI brain SPECT after surgery

Pilocitic astrocytoma?

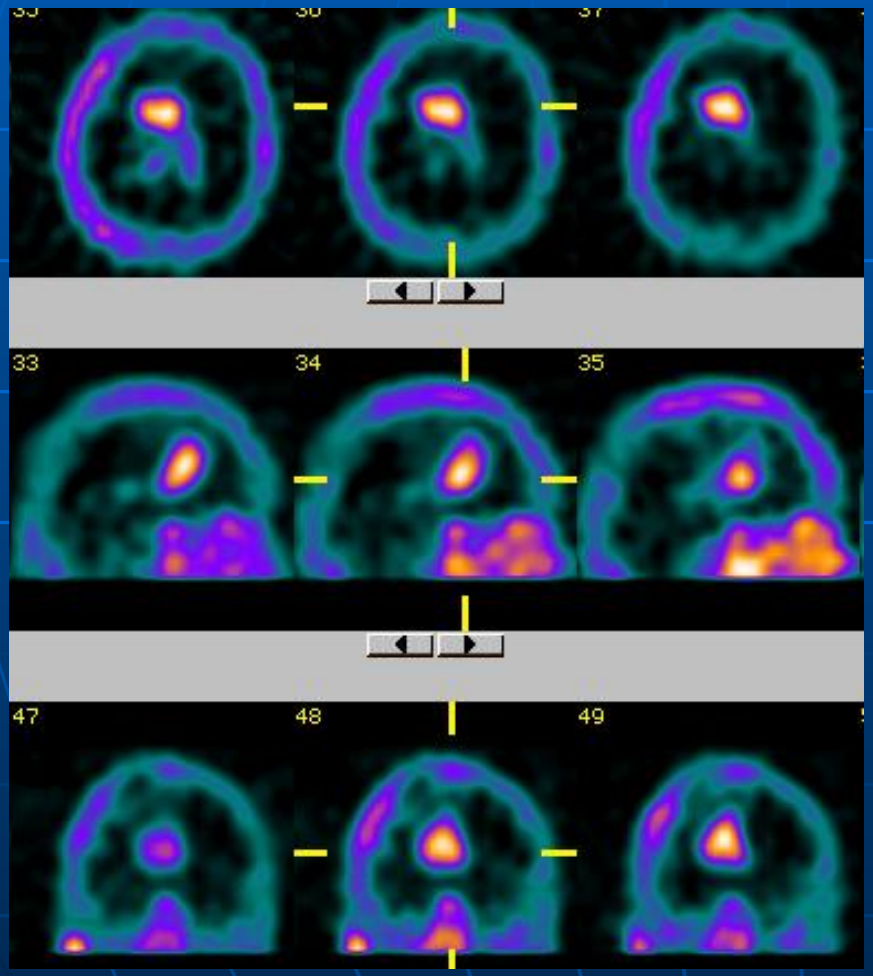

Glioblastoma?

^{99m}Tc MIBI brain SPECT before and (or) after surgery and after radiotherapy

- Evaluation response to therapy
- Differentiation tumor from radiation necrosis

^{99m}Tc MIBI brain SPECT after surgery and after radiotherapy

Glioblastoma (IV)

11 days after surgery

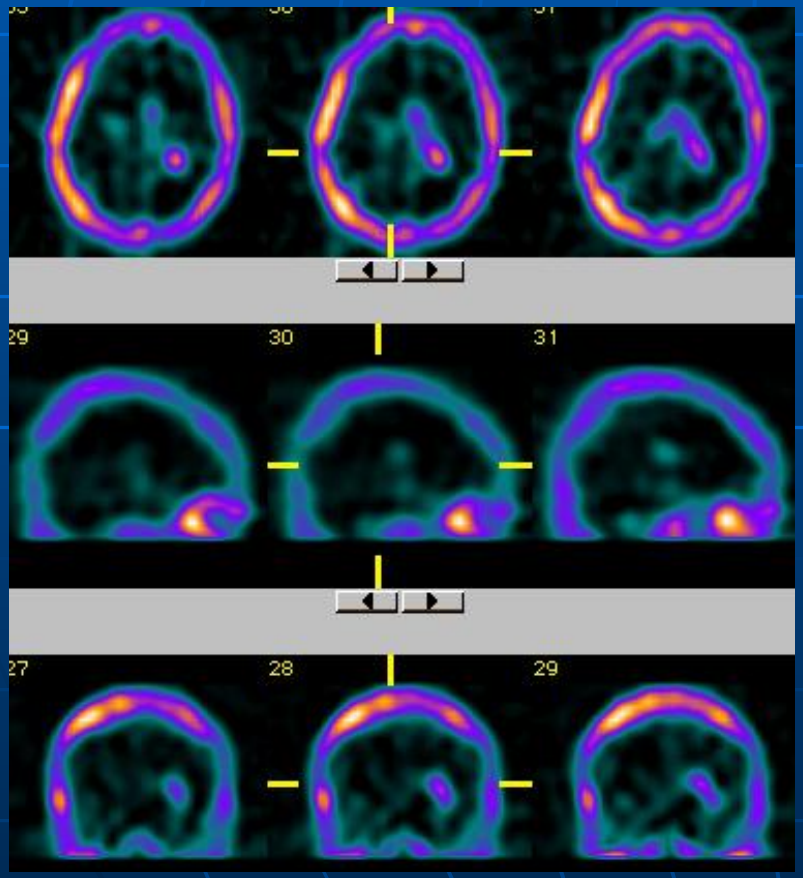

93 days after surgery, after RT

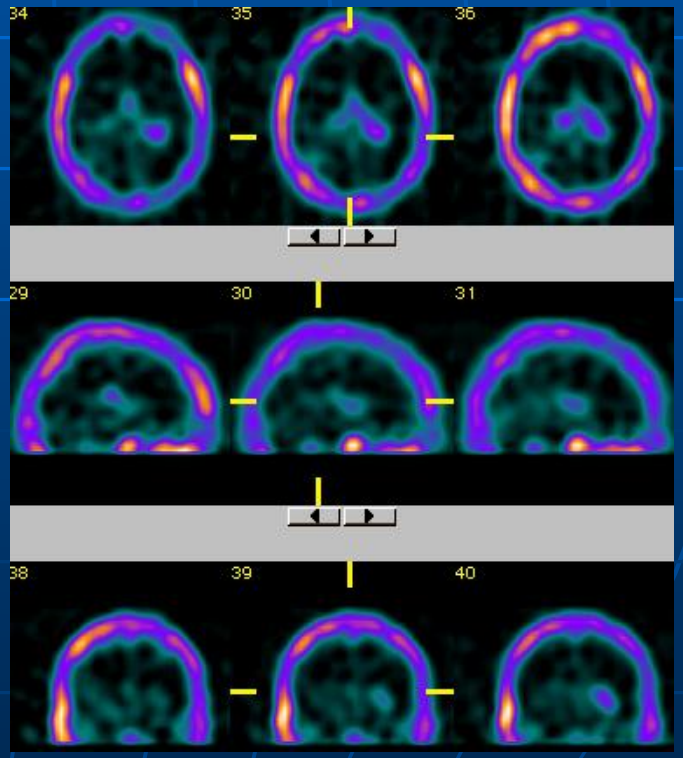

^{99m}Tc MIBI brain SPECT before and (or) after surgery and after radiotherapy

Glioblastoma (IV)

3 days before surgery

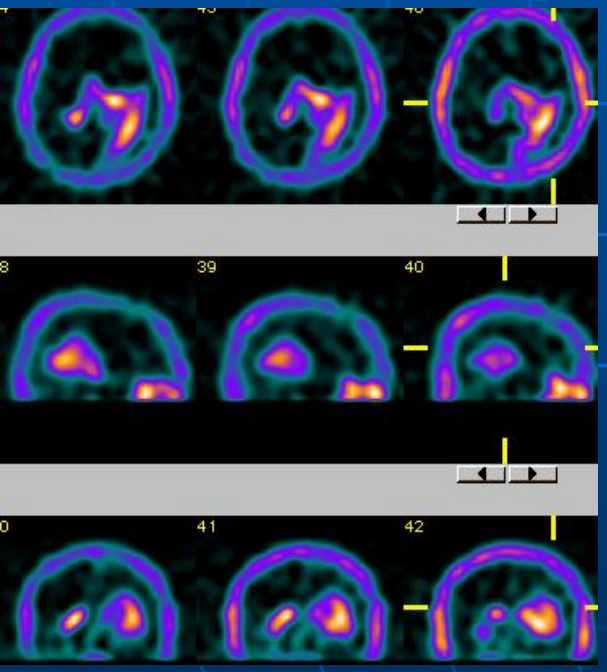

10 days after surgery

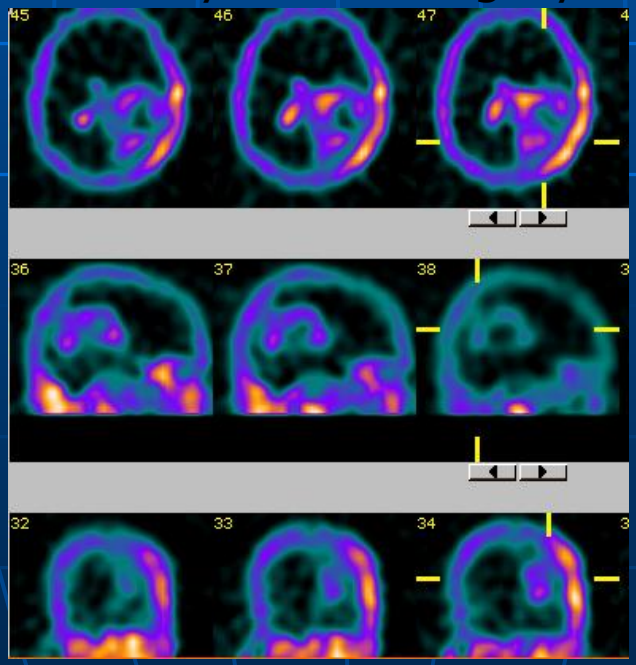

68 days after surgery

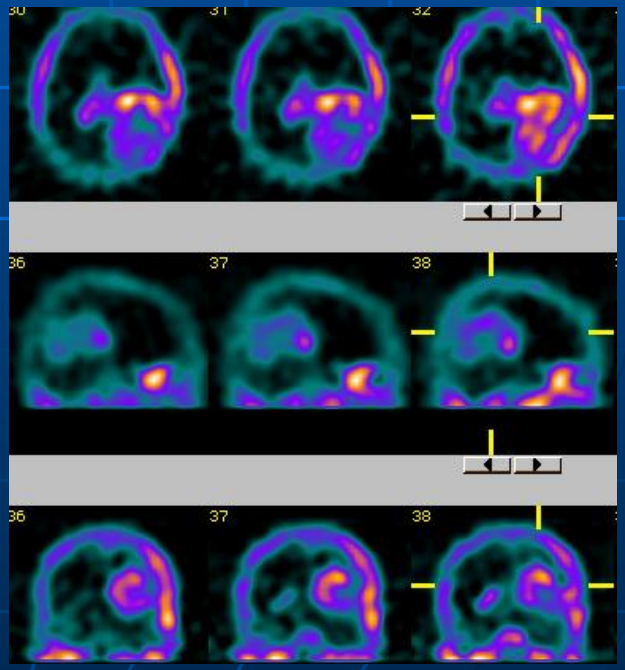

^{99m}Tc MIBI brain SPECT after 3-4 months after treatment, or earlier if there are indications

- Detection of recurrent and persistent high grade glioma
- Detection redifferentiation of glioma

^{99m}Tc MIBI brain SPECT after 3-4 months after treatment, or earlier if there are indications

Glioblastoma (IV)

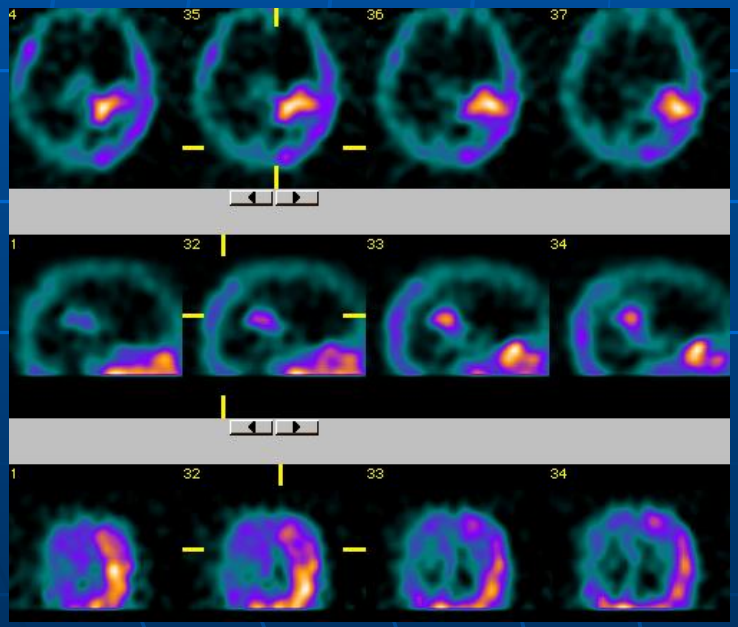

1 month after RT

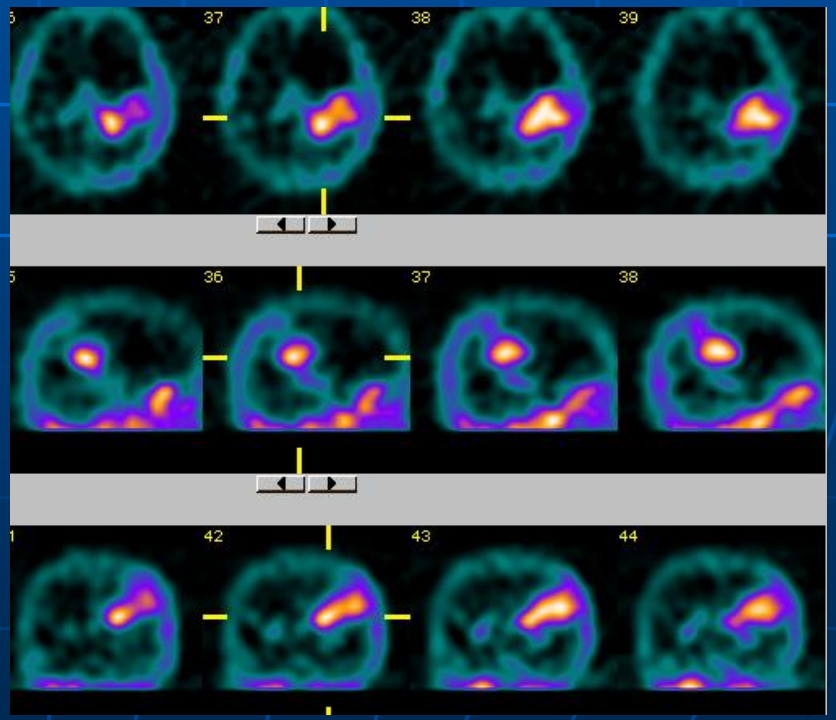

^{99m}Tc MIBI brain SPECT after 3-4 months after treatment, or earlier if there are indications

Glioblastoma (IV)

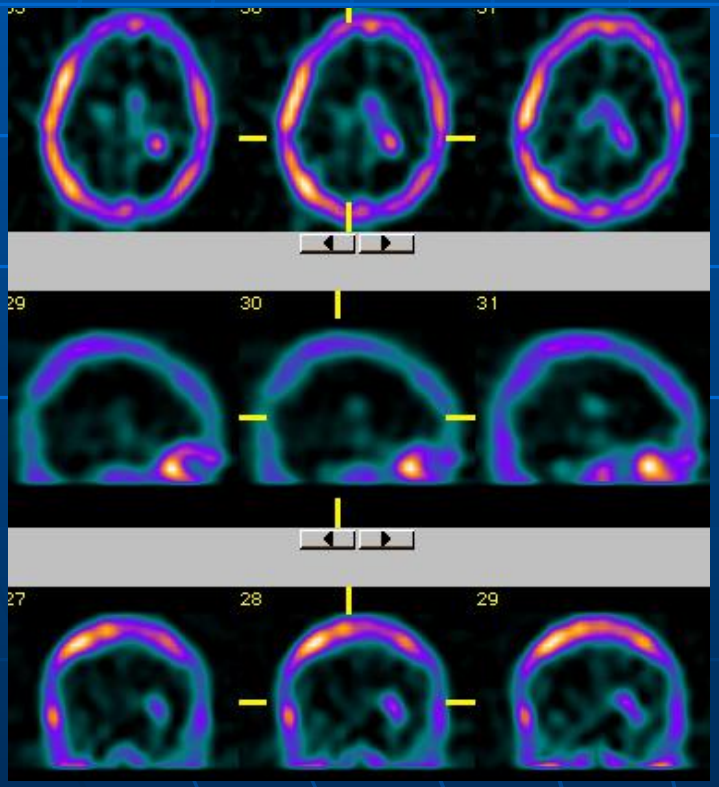

4 month after RT

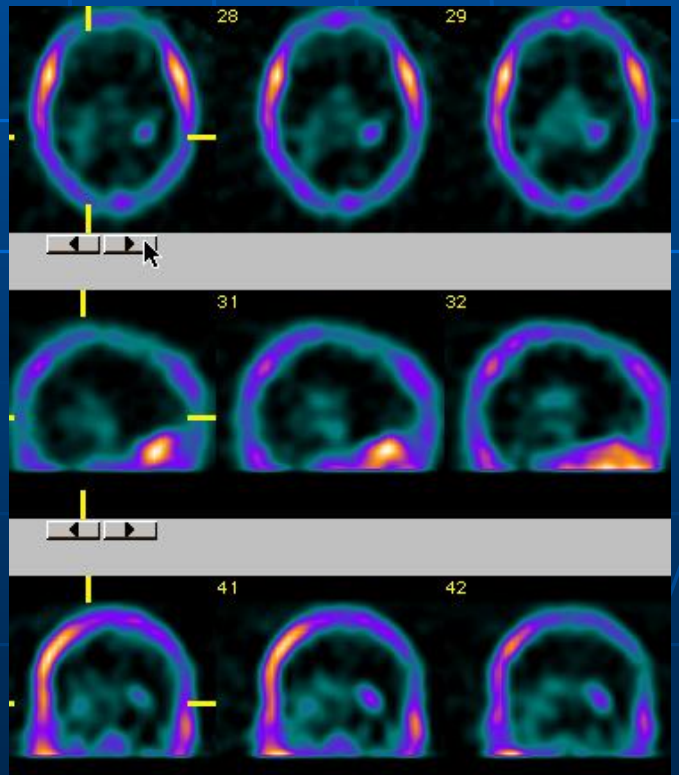

^{99m}Tc MIBI brain SPECT before and after surgery and after radiotheraphy

Glioblastoma (IV)

3 days before surgery

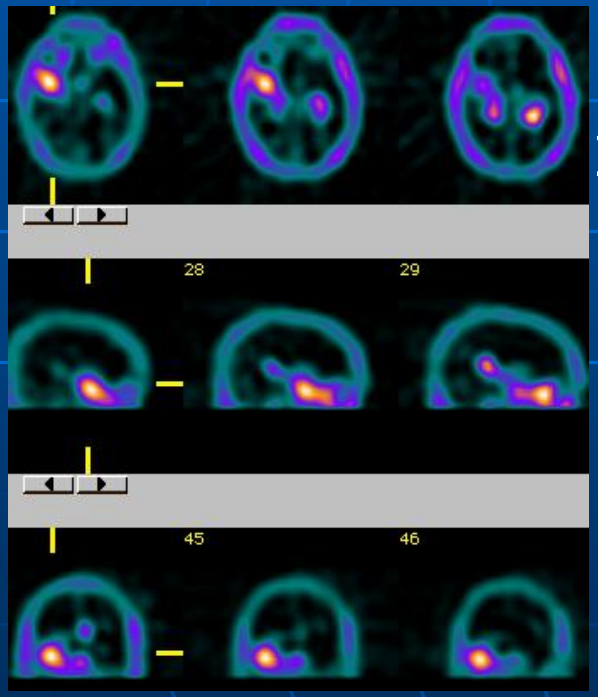

13 days after surgery

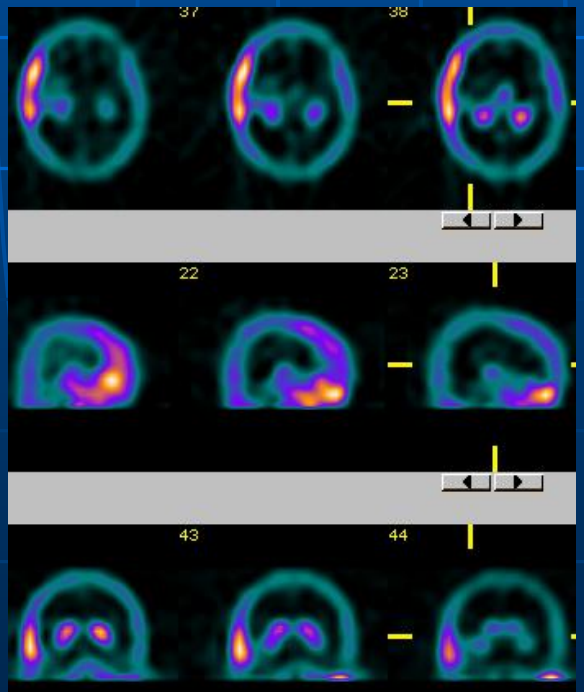

78 days after RT

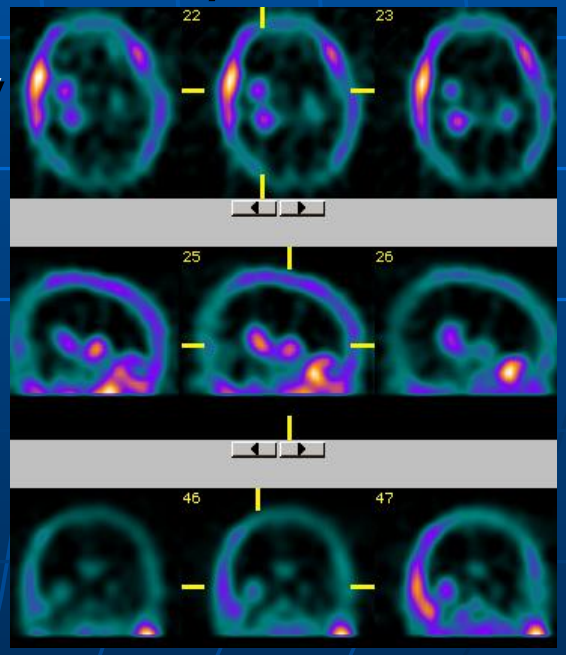

^{99m}Tc MIBI brain SPECT after 3-4 months after treatment, or earlier if there are indications

2,5 month after RT

Glioblastoma (IV)

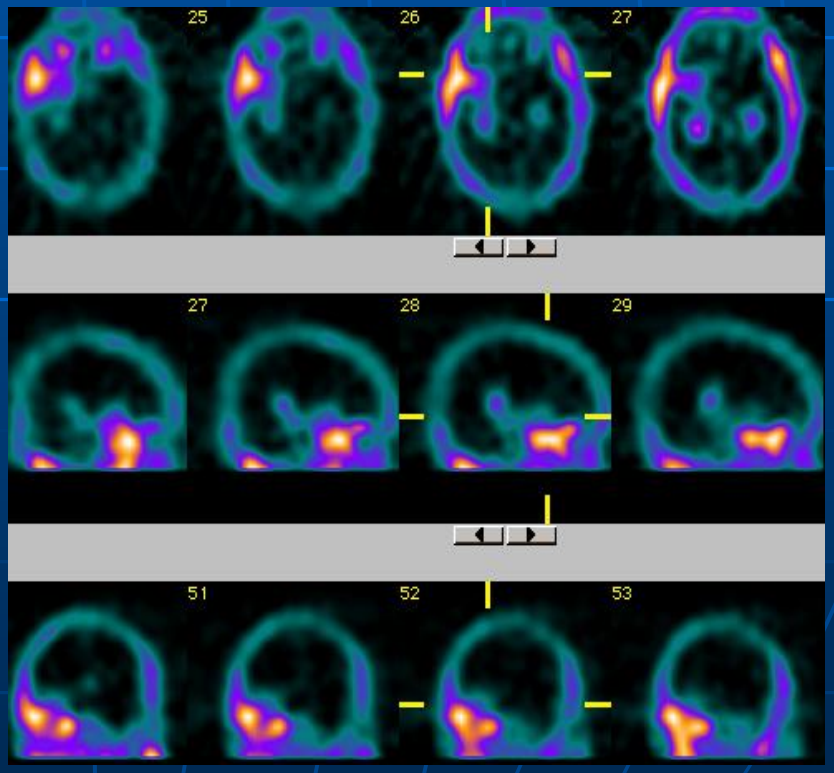

^{99m}Tc MIBI brain SPECT before and after surgery and after radiotherapy

Glioblastoma (IV)

1 day before surgery

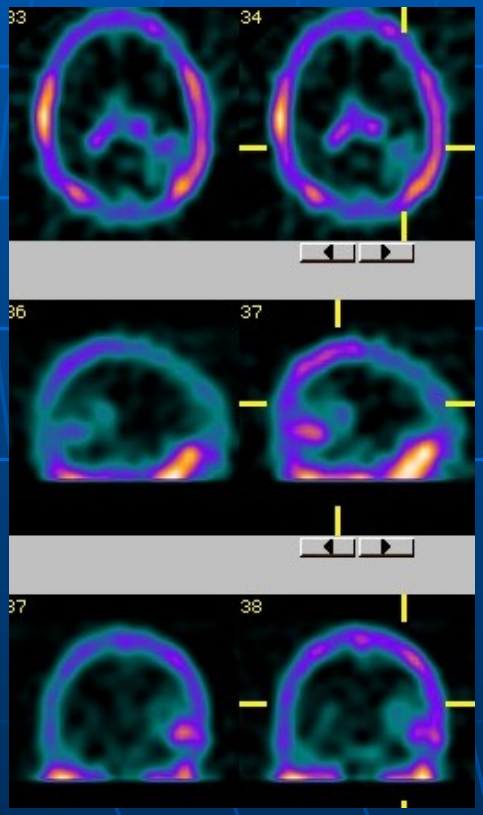

10 days after surgery

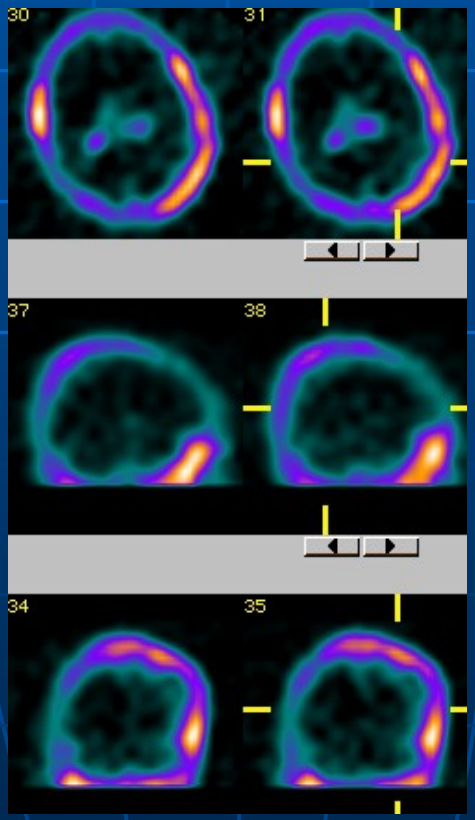

93 days after RT

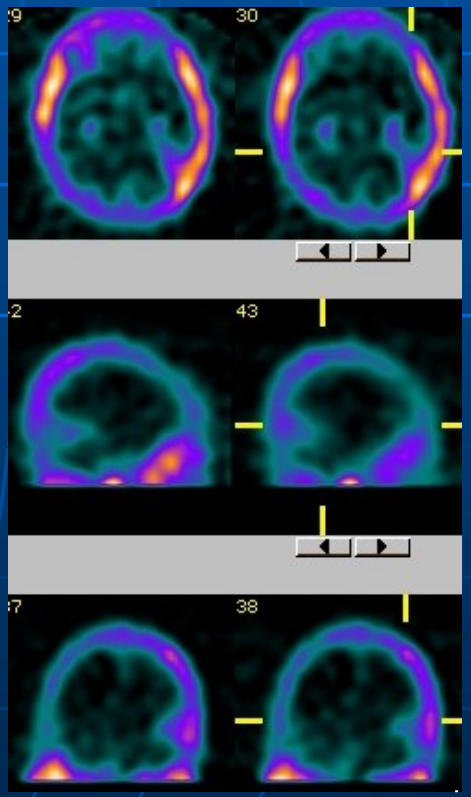

^{99m}Tc MIBI brain SPECT after 3-4 months after treatment, or earlier if necessery

3 month after RT

Glioblastoma (IV)

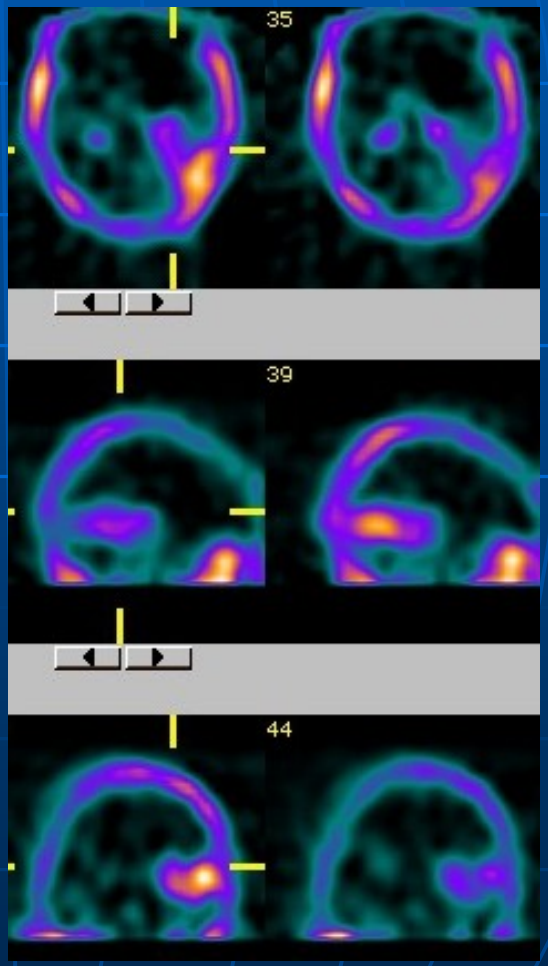

Conclusion

- ^{99m}Tc-MIBI brain SPECT is useful for determination of hystological grade and follow up of gliomas

Ar reikia??????????????

AUTHORS AIM RESULTS

- O' Tuama *et al.* (1993) to investigate MIBI utility in children brain tumors (n= 19) Sensitivity: 67%; specificity: 100%
- Bagni *et al.* (1995) Pre-surgical evaluation in 27 patients Trend between MIBI uptake and gliomas grade of malignancy
- Maffioli *et al.* (1996) MIBI utility in case of post-treatment CT scan not conclusive between recurrence versus scar Sensitivity, specificity and accuracy: 85%. Positive and negative predictive value: 97% and 53%, respectively.
- Naddaf *et al.* (1998) MIBI usefulness to diagnose lymphomas in AIDS patients Sensitivity: 100%; specificity: 69%.
- Soler *at al.* (1998) Retrospective study with MIBI SPECT in 35 patients with clinical deterioration (recurrence vs scar) Specificity and sensitivity: 100 %.
- Nagamachi *et al.* (2001) Relation between MIBI uptake and proliferative activity (antigen MIB-1) Significant correlation between MIBI uptake and MIB-1 index
- Minutoli *et al.* (2003) MIBI in differential diagnosis between neoplastic from non neoplastic intracranial hematoma (n = 29) MIBI sensitivity and specificity: 100%
- Beauchesne *et al.* (2004) To investigate whether the metabolic tumor volume (MTV) calculated by MIBI SPECT after therapy is correlated with patients survival MTV < 32 cm3 : median survival of 358 days. MTV > 32 cm3: median survival of 238 days.